

Content available at: <https://www.ipinnovative.com/open-access-journals>

IP International Journal of Ocular Oncology and Oculoplasty

Journal homepage: <https://ijooo.org/>

Case Report

Dermoid cyst – A rare known caruncular lesion

Sahil Agrawal^{1,2}, Seema Sen^{1,2}, Arnav Panigrahi^{1,2}, Saloni Gupta³, Deepsekhar Das^{1,2,*}

¹Dr. Rajendra Prasad Centre for Ophthalmic Sciences, New Delhi, India

²All India Institute of Medical Sciences, New Delhi, India

³Northern Railway Central Hospital, Connaught Place, New Delhi, India



ARTICLE INFO

Article history:

Received 08-09-2021

Accepted 11-10-2021

Available online 25-10-2021

Keywords:

Carcuncular lesion

Dermoid

Cyst

ABSTRACT

Lesions of the caruncle are rare and diverse in presentation. A 26-year-old female patient presented with swelling 1 X 1 mm in dimension, whitish and avascular in the left caruncular region with no overlying vessels or appendages. She noted a recent increase in size of the mass. There were no evidence of preauricular tags/ sinus/ fistulas/cleft palate/ facial asymmetry/ vertebral or limbal anomalies. Excisional biopsy confirmed the diagnosis of dermoid cyst. Goldenhar-Gorlin syndrome must be kept in mind in the presence of lipodermoids and other ocular or systemic abnormalities. A close correlation between ophthalmologists and pathologists need to be maintained in the evaluation of doubtful lesions.

This is an Open Access (OA) journal, and articles are distributed under the terms of the [Creative Commons Attribution-NonCommercial-ShareAlike 4.0 License](https://creativecommons.org/licenses/by-nc-sa/4.0/), which allows others to remix, tweak, and build upon the work non-commercially, as long as appropriate credit is given and the new creations are licensed under the identical terms.

For reprints contact: reprint@ipinnovative.com

1. Introduction

Dermoid and epidermoids are the most common orbital tumours in children. These lesions come under the category of ocular choristomas, which are congenital lesions presenting as normal tissue in an abnormal site, and can be present in the cornea, limbus, bulbar conjunctiva and other areas of the orbit. They may be associated with Goldenhar-Gorlin syndrome (oculoauriculovertebral dysplasia), characterized by ocular dermoid/lipodermoids, preauricular skin appendages, fistulas, and vertebral anomalies.¹ Herein we report a rare case of caruncular dermoid cyst in a 26-year-old adult female with no other ocular abnormalities.

2. Case Report

A 26-year-old female patient presented with swelling in the left eye for one year, increasing in size for the past five

months. There were no other ocular complaints except for the swelling. There was no history of any systemic illness, nor was there similar family history. On examination, both eyes had visual acuity of 6/6 on Snellen's chart with normal anterior and posterior segment findings, except that there was a mass, 1 X 1 mm in dimension, whitish and avascular in the left caruncular region with no overlying vessels or appendages.(Figure 1 a & b) The surrounding tissues were normal. There were no evidence of preauricular tags/ sinus/ fistulas/cleft palate/ facial asymmetry/ vertebral or limbal anomalies. Computed tomography revealed no post septal extension.

Under peribulbar block, the mass was excised in toto after dissection and releasing its local adhesions, taking care not to excise excess of the caruncle and surrounding plica semilunaris. The incision was closed with an 8-0 vicryl suture. Histopathology of the mass confirmed the diagnosis of dermoid cyst. Follow up at one year was uneventful.

* Corresponding author.

E-mail address: doc.deep.das@gmail.com (D. Das).

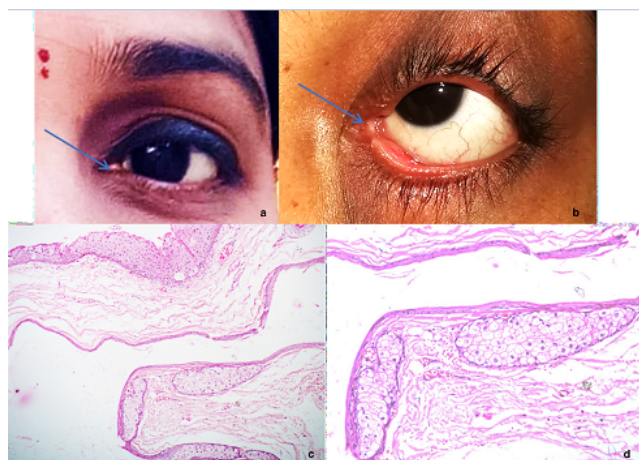


Fig. 1: **a:** External photograph showing whitish avascular dermoid cyst arising from the left caruncle; **b:** Post-operative 1 week follow up; **c:** Histology of the mass with epithelial and connective tissue layers with adipose tissue covered by connective tissue matrix. (H&E x100); **d:** (H&E x200)

3. Discussion

The embryological development of the caruncle is not fully defined. One school of thought is that it develops at the end of the third month of gestation, sequestered from the portion of the lower eyelid by the development of inferior canaliculus. Another postulates that, by epithelial migration of the posterior surface of lower eyelid near the lid margin, caruncle develops as a structure independent of the canaliculus.²

Dermoid cysts are congenital, benign neoplasms of the orbit usually located superotemporally near the frontozygomatic suture, or superonasal, composed of keratinized stratified squamous epithelium and few dermal derivatives like hair follicles and sebaceous glands.³ Dermoid cysts are one of the most common lesions of the orbit in children.^{3–5} Epibulbar dermoid and lipodermoids are choristomas which have epithelium-derived tissues.⁶

Lesions of the caruncle are uncommon. We report this unusual case of dermoid cyst because of its unique nature of being located in the caruncle in a 26-year old adult female.

The compound nature of the caruncle gives rise to a high diversity of neoplasms,⁷ most of which are benign. Acquired lesions of the caruncle are inflammatory conditions, epithelial lesions, cysts, melanocytic tumours, sebaceous tumours, oncocytoma, myeloproliferative disorders, vascular lesions and neural tumours.⁷ The most common lesions are nevus, pigmented caruncle, squamous papilloma, nonspecific chronic inflammation, and granuloma.⁸ In a study conducted in Denmark over 25 years, out of 574 caruncular lesions, about 96% were benign, composed of naevus(43%) and papilloma(23%). Premalignant lesions (1.7%) were mostly primary acquired

melanosis (PAM) with atypia and epithelial dysplasia. Malignant lesions (2.4%) are mostly of basal cell carcinoma (0.7%) and lymphoma (0.7%).⁹ In another study, out of 42 caruncular lesions, 95% are of benign nature.¹⁰

Choristomas may be associated with systemic conditions and other syndromes, such as ring dermoid syndrome, Goldenhar syndrome or mandibulofacial dysostosis of Franceschetti syndrome.¹¹

Goldenhar syndrome is a rare congenital anomaly first described in 1952 by the French ophthalmologist Maurice Goldenhar as a triad of accessory tragus, mandibular hypoplasia and limbal dermoid. Later it was expanded to Goldenhar-Gorlin syndrome due to the additional vertebral anomalies as described by Gorlin. The main ocular features are epibulbar choristoma in the form of limbal dermoid/lipodermoid. Other features include eyelid coloboma, microphthalmia, motility disorders, strabismus, coloboma of iris or choroid, cataracts, anomalies of the lacrimal drainage system, and retinal and optic nerve anomalies have been described.¹²

Lipodermoids rarely need excision. In our case, the lesion was excised in view of cosmesis. Our patient had no other ocular abnormalities nor any anomalies suggestive of Goldenhar-Gorlin syndrome. The patient was reassured of the benign nature of the lesion and was on regular follow-up.

Caruncular lesions are rare and are of diverse variety, which makes clinical diagnosis difficult. According to literature, preoperative diagnosis is correct in about half of the cases, which carries the risk of malignant lesions, though uncommon, being diagnosed as benign ones. Because of its distinct and differing presentations, referral of the excised lesions of the caruncle for the pathological examination becomes a mandatory one.

4. Conflict of Interest

The authors declare that there are no conflicts of interest in this paper.

5. Source of Funding

None.

References

1. Rajabi MT, Ramezani K. Lipodermoid Cyst: A Report of a Rare Caruncular Case. *Middle East Afr J Ophthalmol.* 2015;22(4):528–30.
2. Duke-Elder S, Cook C. Normal and abnormal development: embryology. In: *System of ophthalmology.* vol. 3. Pt. 1. St. Louis: CV Mosby; 1963. p. 234–5.
3. Shields J, Shields C. Orbital Cysts of Childhood- Classification, Clinical Features and Management. *Surv Ophthalmol.* 2004;49(3):281–99. doi:10.1016/j.survophthal.2004.02.001.
4. Cavazza S, Laffi GL, Lodi L, Gasparrini E, Tassinari G. Orbital Dermoid Cyst of Childhood: Clinical Pathological Findings, Classification and Management. *Int Ophthalmol.* 2011;31(2):93–7. doi:10.1007/s10792-011-9419-y.

5. Maurya RP, Patne S, Singh VP, Singh MK, Ritika, Dwivedi M, et al. Presentation pattern and management outcome of ocular and periocular dermoid cyst. *Int J Ocul Oncol Oculoplast*. 2016;2(2):95–105.
6. M B. Lipodermoid: A case report. *Clin Eye Vis Care*. 1995;7(2):79–82.
7. Luthra CL, Doxanas MT, Green WR. Lesions of the caruncle: a clinicohistopathologic study. *Surv Ophthalmol*. 1978;23(3):183–95. doi:10.1016/0039-6257(78)90155-8.
8. Sankar PS, Rajeswari S, Kavitha K. Caruncular dermoid: A report of a rare case. *TNOA J Ophthalmic Sci Res*. 2018;56(4):263–5.
9. Østergaard J, Prause JU, Heegaard S. Caruncular lesions in Denmark 1978-2002: a histopathological study with correlation to clinical referral diagnosis. *Acta Ophthalmol Scand*. 2006;84(1):130–6.
10. Levy J, Ilsar M, Deckel Y. Lesions of the caruncle: a description of 42 cases and a review of the literature. *Eye*. 2009;23:1004–18.
11. Pirouzian A. Management of pediatric corneal limbal dermoids. *Clin Ophthalmol*. 2013;7:607–14. doi:10.2147/OPHTH.S38663.
12. Verma R, Singh NP. Varied ocular manifestations of Goldenhar syndrome. *Med J DY Patil Vidyapeeth*. 2020;13(2):166–8.

Author biography

Sahil Agrawal, Senior Research Assistant

Seema Sen, Professor

Arnav Panigrahi, Junior Resident

Saloni Gupta, Consultant

Deepsekhar Das, Senior Resident

Cite this article: Agrawal S, Sen S, Panigrahi A, Gupta S, Das D. Dermoid cyst – A rare known caruncular lesion. *IP Int J Ocul Oncol Oculoplasty* 2021;7(3):303-305.