

Content available at: <https://www.ipinnovative.com/open-access-journals>

IP International Journal of Ocular Oncology and Oculoplasty

Journal homepage: <https://ijooo.org/>

Original Research Article

A study of ocular morbidity related to trauma and role of B-Scan in its diagnosis and management

Yusuf Rizvi¹, Aniket Rai², Saloni Gupta², Sahil Agrawal^{3,4,*}¹Rohilkhand Medical College and Hospital, Bareilly, Uttar Pradesh, India²Northern Railway Central Hospital, Connaught Place, New Delhi, India³All India Institute of Medical Sciences, New Delhi, India⁴Dr. R.P. Centre for Ophthalmic Sciences, New Delhi, India

ARTICLE INFO

Article history:

Received 08-08-2021

Accepted 09-09-2021

Available online 25-10-2021

Keywords:

Ocular trauma

Bscan

Traumatic cataract

Posterior vitreous detachment

Retinal detachment

ABSTRACT

Purpose: Ocular trauma is an important cause of visual impairment worldwide. The reported annual incidence of severe ocular trauma is 9.75 per 1,000 adults. Ultrasonography (B scan) has emerged as a useful technique in ocular injury scenario. We aimed to evaluate role of B Scan ultrasonography in management of ocular injuries.

Materials and Methods: All patients with ocular trauma attending the emergency department were enrolled for the study. Relevant history and demographic data was noted on the study proforma. Detailed ocular examination was done employing slit lamp biomicroscopy for anterior segment and direct and indirect ophthalmoscopy for posterior segment evaluation. All patients were necessarily subjected to B scan ultrasonography (USG) for additional clinical information.

Results: A total of 50 cases were enrolled. The mean age of affection was 28 years. The most common mode of injury was agriculture related. The most common anterior segment finding was traumatic cataract as seen in 22(44%) cases while on USG posterior vitreous detachments seen in 36% cases, followed by retinal detachment in 24% cases and vitreous haemorrhage in 22% cases. Choroidal detachment was accurately localized in 2% cases.

Conclusion: The study emphasizes the need for B-scan as a valuable tool in the diagnosis of posterior segment pathologies particularly when the media has become opaque as it can visualize and localize the position of the lesions which would not be possible by any other means.

This is an Open Access (OA) journal, and articles are distributed under the terms of the [Creative Commons Attribution-NonCommercial-ShareAlike 4.0 License](https://creativecommons.org/licenses/by-nc-sa/4.0/), which allows others to remix, tweak, and build upon the work non-commercially, as long as appropriate credit is given and the new creations are licensed under the identical terms.

For reprints contact: reprint@ipinnovative.com

1. Introduction

Ocular trauma is an important cause of visual impairment worldwide. It is estimated that over 2.4 million people suffer from ocular trauma annually over the world and 40,000 become visually handicapped permanently.¹ In the Indian context, ocular injuries constitute 1.5% of total blindness.² The prevalence is higher in rural areas (4.5%) than in urban areas (3.97%), as reported by the Ocular Trauma Society of

India.³ It is a common and significant public health problem in developing countries. However, most of the clinico-epidemiological studies on ocular trauma has been carried out in developed countries which cannot be applied in our country.

The present study is designed to evaluate the quantum of visual morbidity assigned due to ocular injuries and the role of B-scan ultrasonography in its management. Our study explores the significance of B-scan ultrasonography in detecting injury mediated ocular pathology and facilitating management. It also measures the incidence of ocular

* Corresponding author.

E-mail address: agrawalsahi103.acad@gmail.com (S. Agrawal).

morbidity attributed to injuries at a tertiary care hospital and compares the different modes of injuries accounting for ocular morbidity.

2. Materials and Methods

This is a prospective observational study including patients of ocular trauma attending the casualty department and Ophthalmology OPD of a tertiary eye care hospital. This work was carried out according to the guidelines of the institutional review board, and ethical clearance was taken. Written informed consent with full disclosure was obtained from the patients before participation in the study. Exclusion criteria included - apprehensive patients not giving consent for B-scan USG, seriously ill polytrauma patients restricting usage or feasibility of B-scan, patients with thermal and chemical injuries.

Relevant history and socio-demographic data (age, gender, residence (rural/ urban), occupation), the place where the trauma occurred, its aetiology, type of object that caused trauma, mode of injury, affected eye and ocular structures were noted.

All patients underwent a comprehensive ocular examination including visual acuity (using Snellen chart), torchlight examination, IOP at presentation, slit-lamp biomicroscopy for anterior segment, and direct and indirect ophthalmoscopy for posterior segment evaluation. Patients were broadly classified into open and closed globe injuries as per the latest Birmingham eye trauma classification. All patients were subjected to B-scan Ultrasonography for additional clinical information. Open globe injuries were subjected to B-scan only after primary suturing.

All the information was collected in a predesigned and pretested pro forma. The collected data were entered and analyzed using SPSS (version 20.0 Chicago, USA: SPSS Inc). Categorical and numerical variables were analyzed as frequency and percentage. Chi-square test of significance was applied, and $P < 0.05$ was taken as statistically significant.

3. Results

A total of 50 patients were studied. They were aged between 10-80 years. The most vulnerable age group was 21-30 years (28%), followed by 10-20 years (26%) and 31-40 years (22%). (Figure 1) Among them, 78% were male while 22% were females. The right eye (RE) was involved in 52% of patients, left eye (LE) in 46% while in 2% both eyes were involved. Maximum number of patients belonged to rural background (%) followed by semi-urban (%) and urban (%) background.

Closed globe injury was present in 41 (82%) patients. Out of these 30 (12.3%) presented with a contusion, 8 (3.28%) with superficial foreign body (FB) while 3 (1.23%) had a lamellar laceration. Open globe injury was commoner

in children and was present in 9 (18%) of patients. Among them 5 (55.56%) had penetration, 3 (33.33%) had intraocular FB and 1 (11.11%) patient had perforated globe.

The most common cause for ocular trauma was workplace-related injuries and was mainly agricultural (30%). It was followed by assault (26%), sports and domestic injuries (24%) cases and industrial workplace attributed (16%). Road traffic accident (RTA) was present in 4% of cases. (Figure 2) Wooden stick was the most common object causing trauma in 20% of patients. Ball related injury was seen in 16% of cases followed by fist (14%), stone (12%) and iron rod (12%). Injury due to fall, firecracker and cricket bat was 4% each.

The majority (90%) of the patients presented with severe visual loss, 6% had mild and 4% had a moderate visual loss. None of the patients had normal visual acuity. Visual acuity was graded as per the criteria described by the International Council of Ophthalmology meet Sydney 2002 as normal visual acuity 6/6, mild visual loss 6/9 to 6/18, moderate visual loss 6/24 to 6/60, severe visual loss <6/60. (Figure 3)

3.1. Anterior segment findings (Figure 4a)

In most cases, the trauma had affected all ocular structures, from anterior to posterior segment. The most common anterior segment finding was traumatic cataract as seen in 44% of cases. It was followed by traumatic mydriasis-24%, traumatic iritis-22%, iridodonesis-18%, hyphema and subconjunctival haemorrhage-16 % each and lens subluxation-14% cases.

3.2. Posterior segment findings (Figure 4b)

The most common posterior segment findings detected clinically were vitreous degeneration- 8% and vitreous haemorrhage- 6%cases. Commotio retinae were seen in 4% of cases, retinal detachment was seen in 2 cases only (4%), dislocation of the lens in vitreous in 2% cases. No choroidal detachment and posterior vitreous detachment were seen clinically.

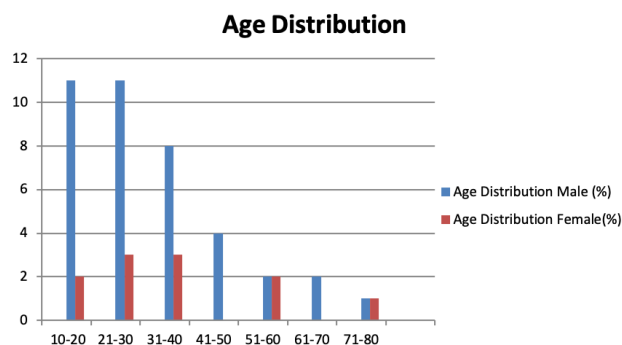


Fig. 1: Trauma related age distribution chart

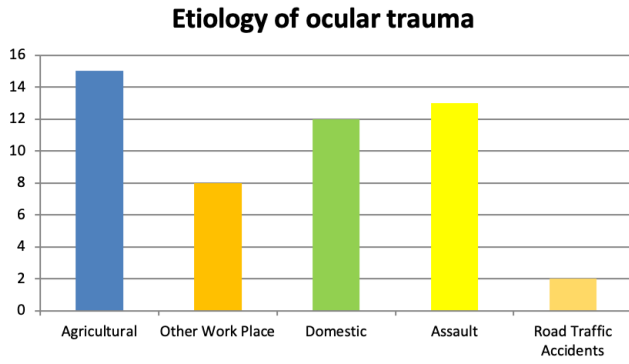


Fig. 2: Chart depicting etiology of trauma

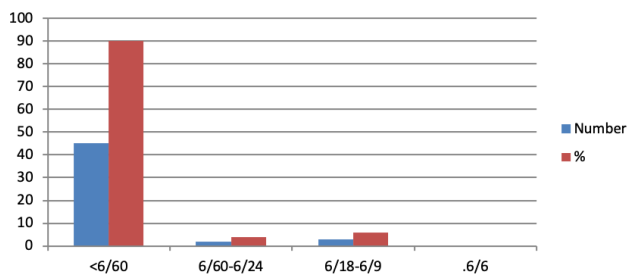


Fig. 3: Visual acuity at presentation

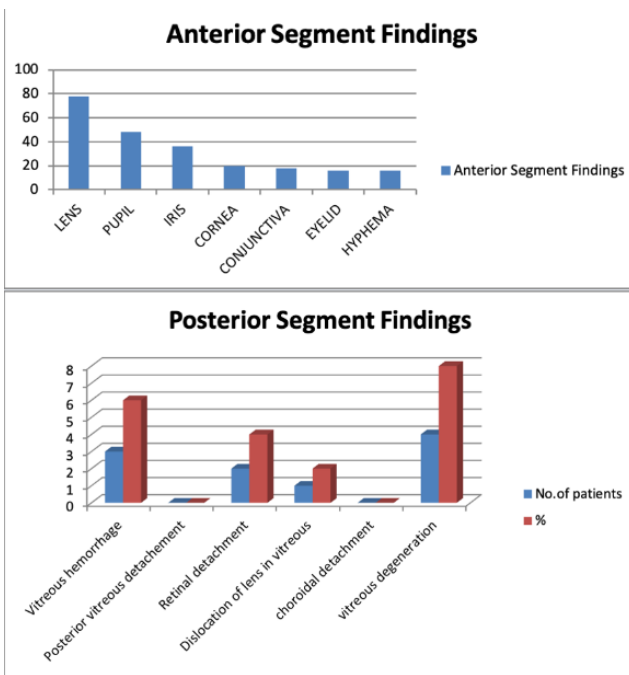


Fig. 4: Chart depicting clinically detected anterior and posterior segment findings

Table 1: Comparative statistical evaluation employing chi-square test

Findings	Vitreous hemorrhage	Posterior vitreous detachment	Retinal detachment	Choroidal detachment	Subluxation of lens	Dislocation of lens	Commotio Retinae	Vitreous Debris
No. of patients on B-scan Findings	11	18	12	1	3	2	0	4
No. of patients on Clinical Findings	3	0	2	0	0	1	2	4
B scan %	22	36	24	2	6	4	0	4
Clinical Finding%	6	0	4	0	0	2	4	4
P-value	0.0117*	0.00*	0.001*	0.312	0.074	0.551	0.148	1

*statistical significance (p<0.005)

3.3. B-scan USG findings

The most common findings on USG were posterior vitreous detachments seen in 36% cases, followed by retinal detachment - 24% cases and vitreous haemorrhage - 22% cases. The choroidal detachment was accurately localized in 2% of cases.(Table 1)

4. Discussion

Of all the reported modes of injuries, blunt trauma is the commonest (62.4%). The frequent causes include road traffic accidents, physical assaults, sports injuries, agricultural injuries and other occupational injuries; particularly hammering nail injuries.¹ Unfortunately, a vast number of these injuries result in a permanent impairment of vision of the young population that results in an irrevocably altered lifestyle and a perpetual psychological scar.

The commonest age group affected in our study was between 20-30years (28%) followed by 10-20 years (26%). The mean age of affection was 28 years. This is similar to previous studies where out of 6704 participants interviewed, 163 episodes of ocular trauma were reported by 158 participants (prevalence = 2.4%, confidence interval = 2.0 to 2.7) with a mean age at trauma of 24.2 years.⁴

Most studies have indicated ocular trauma incidence skewed towards the male population. Out of 402 patients, 293 (72.9%) were male and 109 (27.1%) were female. Overall male-to-female sex ratio was 2.7:1.⁵ Our study also revealed a significantly high risk of ocular trauma amongst the male population (78%) (male: female ratio being 3.7:1). However, this risk becomes equivalent with advancing age. An equal number of male and female cases are recorded in the sixth and eighth decade of life. Our study has noted 52% involvement of the right eye, 46% of the left eye and 4% of bilateral involvement.

A myriad of predisposing factors leads to eventual ocular trauma. Jain et al have documented RTA related injuries as a cause for ocular trauma in 27.73% of cases followed by 22% agricultural injuries, 19.11% industrial injuries and nearly 14% as injuries associated with domestic violence and sports-related factors.⁶⁻¹⁰ On a contrasting note, our study highlights RTA in only 4% of cases as the cause for ocular trauma, as against agricultural injuries (30%), assault (26%), sports and domestic-related (24%) and industrial work place attributed (16%). This highlights the disparity in etiological factors for ocular trauma depending on the region, occupation, cultural practices and level of urbanization. A study in a tertiary centre in Northern India had daily labourers as the most commonly affected individuals in trauma (64 cases = 32%), followed by housewives (37 cases = 18.5%) then by farmers (17.5%) and students accounting for 35 cases (17.5%) each.¹¹

In our study, the most common etiological agent that traumatized the eyes were a wooden stick that accounted

for nearly 20% of the patients. Such wooden stick injuries were encountered at workplaces, in agricultural fields and instances of domestic violence. Children were particularly susceptible to such mode of injuries due to ignorance and lack of safety precautions while at play. In a comprehensive analysis of agents of trauma amongst 83 patients, Sana Nadeem et al have conferred injuries caused by wooden sticks and stone as the most frequent etiological agents for ocular trauma.¹²

Our study highlights blunt trauma with closed globe injuries as the most frequently encountered ocular trauma accounting for 82% of the cases. Closed globe injuries accounted for more than 60.5% of the cases in the study. Also, in a study from Korea by Oum et al., the prevalence of closed globe injury was six times higher than open globe injury.¹³ In the study by Rajendra P Maurya et al, blunt injuries predominated (56%) and only 17% of injuries were caused by sharp objects.⁵ Such statistics have been substantiated by almost all the studies across the globe.^{12,14}

The structural damage caused to the eye has a multitude of presentations; some that are relatively innocuous while others blinding in nature. The structural and functional visual loss as recorded by our study has been attributed to multiple traumatic patterns ranging from a conjunctival tear/haemorrhage to sclera-corneal perforations, traumatic uveitis, hyphema, lens rupture/dislocation, angle recession, secondary glaucoma, vitreous hemorrhage.

Patients may range from a small foreign body on the cornea to a ruptured globe, from a patient presenting with 6/6 vision to a patient with no perception of light. In our study, best-corrected visual acuity (BCVA) was poorer than 6/60 in 45 of the 50 evaluated cases. This is in agreement with a plethora of similar studies that quote figures of severe presenting visual handicap ranging from 56.5%-70%. A study by Rao et al reported visual acuity at presentation between 6/36 and 6/60 in 45.18% and below 6/60 in 21.48% eyes suffering from ocular trauma with associated head injuries.¹⁵⁻¹⁸ The marginal shift in ocular morbidity in this study was perhaps due to different selection criteria of including only head injury patients with associated ocular trauma. The high presenting visual handicap of below 6/60 in our study could probably be explained due to late presentations, selective referrals due to the tertiary nature of the hospital and a high level of ignorance with poor literacy levels, rampant in this region. Visual acuity of 6/9 or better in 44.11% cases was reported by Bharat Jain et al, 6/18 or better in 40% and 67% by Titiyal et al and Abha et al respectively.^{19,20} Since our study was cross-sectional, observational, non-interventional in nature, the prospective aspect of final visual status as attained by these patients could not be ascertained. Nevertheless, it gave useful inputs into the demographic pattern, societal and occupational approach and diagnostic criteria to be followed in cases involving ocular trauma in this region.

A review of the ocular structures involved due to trauma in our study, reveals involvement of lens in nearly 70% of cases, pupillary involvement in 48%, iris in 36%, cornea in 20%, conjunctiva 18% and eyelid and anterior chamber affected in 16% each. The most common anterior segment finding was traumatic cataract as seen in 22 (44%) cases followed by traumatic mydriasis and traumatic iritis seen in 24% and 22% cases respectively. Maurya RP et al reported hyphema (31.70%), traumatic cataract (21.95%), iridodialysis (19.51%)²¹ as commonest anterior segment complications. A case study by Sindhura et al also showed traumatic cataract to be the most common anterior segment finding, accounting for 34.90% followed by corneal oedema/opacity (23.86%) which is consistent with our findings.^{22,23} However, a study by Alem et al showed, among all (773) cases studied corneal tear was the most frequently observed finding (39.33%, number (n) = 304), followed by lens damage (24.45%, n = 189).²⁴ Also study by Das et al at a tertiary centre in Andaman islands, corneal epithelial defects were mostly encountered lesion (32.9%), followed by corneal perforation (11.4%) and lid laceration (7.1%). Traumatic anterior dislocation of the lens was found in 2.9% of cases, whereas traumatic cataract was found in 5.7% of cases.²⁵ Injuries restricted to the anterior segment by and large had a uniform diagnosis made by both clinical evaluation and B-scan sonography as also seen in our study.

However, our study has highlighted the lacunae of disparity in posterior segment findings by statistically comparing diagnostic outcomes through clinical and ultrasonographic evaluations.

Posterior segment associations were revealed in all cases of open globe and 35% cases of closed globe injuries. The visual acuity at the time of presentation was poor in a majority (90%) of cases at the time of presentation. All cases with open globe injuries and 18% with closed globe had a vision below <3/60. While analyzing the posterior segment, the most frequent clinical finding was vitreous haemorrhage (22%) and retinal detachment (4%). The clinical diagnosis as made on slit-lamp biomicroscopy, changed B-scan evaluation in a high percentage of cases. Using B-scan ultrasonography nearly 36% of ocular trauma cases were found with posterior vitreous detachment (PVD), 24% with retinal detachment, 22% with vitreous haemorrhage and 2% with choroidal detachment. Interestingly 3 cases (6%) of lens subluxation and 2 cases (4%) of lens dislocation that was inadvertently missed on routine clinical assessment, were also picked up on B-scan. The Chi-square test analyses, comparing the clinical and ultrasonographic data, noted statistically significant ($p < 0.05\%$) differences for the clinical condition of vitreous hemorrhage ($p = 0.0117$), posterior vitreous detachment ($p = 0.001$) and retinal detachment ($p = 0.001$). Differences in diagnosis were also noted for subluxation of the lens, dislocation of

lens and commotio retinae but they were not statistically significant. This underscores the relevance of B-scan evaluation in both open and closed globe injuries, especially when suspecting vitreous haemorrhage, posterior vitreous haemorrhage and retino-choroidal detachment. Intraocular foreign body detection finds a special need for B-scan evaluation due to the limitation of MRI in metallic intraocular foreign bodies.

Thus, our study concluded that there is a mandatory requirement of B-scan ultrasonography in all ocular trauma cases, particularly those with a suspicion of lenticular or posterior segment anomaly in the event of obscured posterior segment. More than two decades have passed since the early reports on the clinical use of ultrasound in the diagnosis of ocular and orbital pathologies appeared in the literature. However, there is hardly any report available from India projecting its diagnostic potential.

5. Conflict of Interest

The authors declare that there are no conflicts of interest in this paper.

6. Source of Funding

None.

References

1. Kharki BD. Ocular Morbidity due to Trauma. *PMJN*. 2008;8(1):1–12.
2. Dattatray HR, Kuli JJ, Gogoi RN. Dr. Rajendra N. Gogoi A Clinical Study to Evaluate Ocular Manifestations of Trauma. *Int J Sci Res (IJSR)*. 2016;5(4):2326–8.
3. Chugh JP, Susheel, Verma M. Role of ultrasonography in ocular trauma. *Head Neck Neuroradiol*. 2001;11(2):75–9.
4. Vats S, Murthy GV, Chandra M, Gupta SK, Vashist P, Gogoi M, et al. Epidemiological study of ocular trauma in an urban slum population in Delhi, India. *Indian J Ophthalmol*. 2008;56(4):313–6.
5. Maurya RP, Srivastav T, Singh VP, Mishra CP, Al-Mujaini A. The epidemiology of ocular trauma in Northern India: A teaching hospital study. *Oman J Ophthalmol*. 2019;12(2):78–83. doi:10.4103/ojo.OJO_149_2018.
6. Jain BK, Devi ER. A clinical study of ocular trauma. *J Evid Based Med Healthc*. 2015;2(61):9055–9.
7. Sobaci G, Akin T, Erdem U. Ocular Trauma Score in Deadly Weapon-related Open-globe Injuries. *Am J Ophthalmol*;141(4):760–1.
8. Govind ST, Pandey S, Sharma V. An unusual presentation of neglected naso-orbital foreign body. *J Evol Med Dent Sci*. 2013;2(21):3717–9.
9. Singh D, Sharma YR, Azad R. Profile of Ocular Trauma at Tertiary Eye Centre. *JK Sci: J Med Educ Res*. 2005;7(1):14–9.
10. Sinha S. Pattern of trauma to Anterior Segment of Eyes in a Tertiary Eye Care Centre of Jharkhand. *Journal of the Indian Medical Association*. 2008;106(5):289–90.
11. Syal E, Dhawan M, Singh SP. To study the epidemiological and clinical profile of ocular trauma at a tertiary health-care facility. *Delta J Ophthalmol*. 2018;19:259–67.
12. Sana MN, Ayub H, Fawad H. Visual Outcome of Ocular Trauma. *Pak J Ophthalmol*. 2013;29(1):34–9.
13. Oum BS, Lee JS, Han YS. Clinical features of ocular trauma in emergency department. *Korean J Ophthalmol*. 2004;18(1):70–8. doi:10.3341/kjo.2004.18.1.70.
14. Chhawania P, Shikha. Study of B-Scan in Ocular Trauma. *Sch J App Med Sci*. 2016;4(6):2137–5.

15. Prasada IR, Sundar PS, Vaidehi P. Clinical Study of Ocular Morbidity in Head Injury Patients At Tertiary Care Unit, Andhra Pradesh. *IOSR J Dent Med Sci (IOSRJDMS)*. 2016;15(11):21–6.
16. 1983.
17. Kulkarni1 SAR, Aggarwal1 RP, Kulkarni2 MR, Deshpande PBWD, Labhsetwar AS. *Ocular manifestations of head injury Eye (Lond)*. 2005;19(12):1257–63.
18. Stavern GPV, Biousse V, Lynn MJ, Simon DJ, Newman NJ. Neuro-Ophthalmic manifestations of head trauma. *J Neuro-Ophthalmol*. 2001;21(2):112–117.
19. Govind CTS, Prakash S, Gupta V, Joshi. Pattern of Ocular Trauma in Tertiary Care Hospital of Kumaon Region. *J Indian Acad Forensic Med*. 2013;35(2):971–973.
20. Gahlot A, Magdum R, Singh M, Kumari P. A Study of Ocular Trauma Profile and Its Visual Outcome in Road Traffic Accidents. *Natl J Med Res*. 2015;5(3):211–5.
21. Maurya RP, Singh VP, Yadav I, Singh MK, Mishra CP, Sen PR, et al. Profile of pediatric ocular trauma at tertiary eye care center in northern India. *Indian J Clin Exp Ophthalmol*. 2015;1(2):76–83.
22. Sindhura G, Krishna N. Study of B Scan Ultrasonography in Blunt Ocular Trauma in Correlation with Clinical Findings. *Int J Sci Res (IJSR)*. 2018;7(5):178–81.
23. Sitholea HL, Makgamathob MN. The use of ultrasonography in a patient with blunt eye trauma. *S Afr Optom*. 2013;72(2):94–6.
24. Alem KD, Arega DD, Weldegiorgis ST, Agaje BG, Tigneh EG. Profile of ocular trauma in patients presenting to the department of ophthalmology at Hawassa University: Retrospective study. *PLoS One*. 2019;14(3):e0213893. doi:10.1371/journal.pone.0213893.
25. Das S, Rana M. Patterns of Ocular Trauma Presenting to the Tertiary Eye Care Centre in the Islands of Andaman and Nicobar. *DJO*. 2020;30:20–6.

Author biography

Yusuf Rizvi, Professor

Aniket Rai, Senior Resident

Saloni Gupta, Consultant

Sahil Agrawal, Senior Research Officer

Cite this article: Rizvi Y, Rai A, Gupta S, Agrawal S. A study of ocular morbidity related to trauma and role of B-Scan in its diagnosis and management. *IP Int J Ocul Oncol Oculoplasty* 2021;7(3):257-262.