



## Review Article

## Management of impacted corneal foreign bodies: A review

Sahil Agrawal<sup>1</sup>, Sandton J S Raj<sup>1</sup>, Sujeeth Modaboyina<sup>1</sup>, Rahul Bafna<sup>1</sup>, Saloni Gupta<sup>2</sup>, Deepsekhar Das<sup>1,\*</sup><sup>1</sup>Dr. Rajendra Prasad Centre for Ophthalmic Sciences, All India Institute of Medical, New Delhi, India<sup>2</sup>Northern Railway Central Hospital, New Delhi, India

## ARTICLE INFO

## Article history:

Received 10-05-2021

Accepted 25-05-2021

Available online 24-07-2021

## Keywords:

Foreign bodies

cornea

surgical techniques

ocular trauma

corneal foreign body

## ABSTRACT

Corneal foreign bodies are commonly seen in an ophthalmology emergency. The most common cause of this condition is a workplace-related injury. In these situations, the management differs from patient to patient and depends on a wide range of variables. In this article, we aim to review the literature on corneal foreign bodies in the past 50 years and classify them based on their level of impaction and elaborately discuss all the management options described for each.

© This is an open access article distributed under the terms of the Creative Commons Attribution License (<https://creativecommons.org/licenses/by/4.0/>) which permits unrestricted use, distribution, and reproduction in any medium, provided the original author and source are credited.

## 1. Introduction

Corneal foreign bodies are common ocular emergencies reported in the ophthalmology emergency. Most of these are workplace-related injuries occurring as sequelae of welding, hammering or farming. Some studies show that occupation related injuries contribute 20.1 % of all ocular trauma cases in India.<sup>1</sup> The incidence is common among young males engaging in high-risk sports activities or workplaces without a proper protective eye-gear.<sup>2</sup> A nine-month study in a tertiary care centre at the Indian state of Haryana further substantiated that a majority of injuries occur in younger males, with 66 % belonging to the age group of 14-29 years. 47 % of the injured cases were from the metal industry, and 27 % were from construction sites. The most common activity leading to a corneal foreign body was metal grinding.<sup>3</sup>

## 1.1. Physiological and anatomical protection from foreign bodies

A multitude of factors protects the eyeball. The lids and lashes prevent dust, sweat and small particles from entering the eye. The lacrimal gland serves the function of keeping the ocular surface moist and also washes out foreign bodies. Tears also contain lysozyme, which carries out antimicrobial activity. The conjunctiva protects the sclera, and the orbital bony rim protects the eye from mechanical trauma and foreign bodies. (Figure 1)

## 1.2. Corneal foreign bodies and their implications

## 1.2.1. Corneal physiology and sequence of events following trauma

The cornea is a transparent avascular structure that is of utmost importance in vision and maintaining the integrity of the globe. The epithelium of the cornea is composed of superficial cells, wing cells and basal cells. The basement membrane of the epithelium has regenerating potential, and thus injuries that pertain to the epithelium heal by

\* Corresponding author.

E-mail address: [doc.deep.das@gmail.com](mailto:doc.deep.das@gmail.com) (D. Das).

themselves when managed immediately. An injury to the Bowman's membrane, which is an acellular layer, leads to scar formation as the layer does not have the ability to regenerate. Stroma contributes to 90% thickness of the entire cornea and is primarily composed of regularly arranged collagen fibres. Stromal injuries lead to scarring, and if the scarring is in the visual axis, the patient might require surgical interventions in the future to optimise vision. Descemet's membrane is a tough layer that acts as a shield, and any damage to the same can result in prolapse of iris tissue, and further, the anterior chamber contents can get exposed. The endothelial pump is of utmost importance in maintaining the hydration of corneal stroma. Any damage to the endothelium leads to permanent loss of the cell and compensatory polymegathism and pleomorphism together with stromal oedema. Hence we should not blindly manipulate any stromal foreign body since it can lead to more damage and corneal decompensation.

### 1.2.2. Factors determining the level of foreign body impaction

Various factors are responsible for the level of foreign body impaction in the cornea:

1. The velocity with which the foreign body is travelling. High-velocity injuries lead to deeper penetration and may even enter the anterior chamber, causing damage to the iris and lens and may even reach the posterior retina.
2. The angle of impact
3. The shape of the foreign body. Foreign bodies with a sharper edge are likely to get impacted deep, whereas foreign bodies will be exactly the opposite.
4. Nature of the foreign body: Rigid foreign bodies will travel deeper than softer malleable ones.

However, the nature of damage and level at which the foreign body gets halted depends on the combined effect of all the previously mentioned factors along with certain factors related to the patient's cornea: corneal rigidity and thickness.

### 1.3. Sequence of events following a foreign body impaction

A sudden release of tears after a foreign body impaction causes a brief period of blindness associated with blepharospasm. Also, rubbing of eyes causes the foreign bodies to penetrate deeper layers which, on the other hand, would have been washed away.<sup>4</sup> Once a foreign body is entrapped between the layers of the cornea, it triggers an inflammatory cascade and activation of white blood cells. These lead to congestion, corneal and lid oedema, chemosis, anterior chamber reaction. These are more prominent and early with organic foreign bodies like leaves, cow dung etc.,

due to infective foci. (Figure 2) A delay in intervention can result in necrosis of the tissue and lead to deleterious complications like endophthalmitis. Once an epithelial wound is formed, healing of the same is achieved by cell migration and proliferation. Small lesions that occupy less than 60 per cent of the total surface area heal rapidly within four days compared to defects occupying larger areas.<sup>5</sup> Inert materials like glass, plastic etc., usually don't give rise to inflammatory reactions; finally, they get integrated into the cornea. Some surgeons prefer to leave them in situ unless there is profound irritation. But due to fibroblastic activation, the scar formed in the central cornea can be visually and cosmetically disabling for the patient. Rust which is left behind after removing ferrous foreign bodies, can lead to necrosis of the stroma.<sup>6</sup> On the other hand, in the case of organic materials, there is a proliferation of giant cells and the formation of granulomas. The foreign body in such cases may act as a nidus for infective keratitis and may even flare up into endophthalmitis or panophthalmitis.<sup>4</sup>

### 1.4. Types of corneal foreign bodies

The common ocular foreign bodies include metal pieces, rust particles, glass pieces and organic matter. However, there are reports of unusual foreign bodies like one's own hair, caterpillar hair getting impacted.<sup>7</sup>

Ocular foreign bodies can be classified based on the nature of foreign body into Organic and Inorganic type. Depending on the location of corneal foreign bodies, they can be divided into Superficial, Stromal or Deep.

Foreign bodies that are confined to the cornea's epithelium can be considered superficial foreign bodies (Figure 3a,b), and those embedded in the corneal stroma (Figure 4a) and below are considered deep (Figure 5a). Superficial ones are easily identified on slit-lamp and can be removed in the same sitting. In the case of deep foreign bodies, anterior segment optical coherence tomography before the procedure will benefit the surgeon in assessing the depth of penetration and planning the procedure accordingly. Jinagal et al. have reported a case of a plastic piece that was embedded in the superficial stroma. AS-OCT was used to assess the depth of impaction prior to removal with forceps. AS-OCT is particularly helpful in the case of pediatric age groups who are not able to provide a proper history.<sup>8</sup> Caterpillar hair can give rise to ophthalmia nodosa, a type of severe nodular granulomatous iridocyclitis.<sup>4</sup>

### 1.5. Signs and Symptoms

The common symptoms are foreign body sensation, watering, redness, photophobia, blurred vision. Toddlers and children who are not able to communicate verbally or give a proper history might also be uncooperative for examination. They may show irritability and pain on closing

the eyelid.<sup>9</sup> Often, they can be asymptomatic also. The removal of a corneal foreign body is always carried out in an emergency setting.<sup>10</sup> The type and circumstances of injury can give a clue regarding the possibility of globe penetration also.

### 1.6. Investigations

Even though we can remove superficial corneal foreign bodies under an operating microscope or slit lamp, plain radiography of orbit, CT scan and occasionally MRI is indicated in cases of severe ocular injuries like blast injuries and perforating injuries. MRI is contraindicated in cases of suspected metal foreign bodies.<sup>11</sup> A retained extraocular or intraocular foreign body can lead to ocular and adnexal inflammation and infection, hence the need for urgent removal. Inorganic foreign bodies are well tolerated; on the contrary vegetative foreign bodies act as a nidus for infection.<sup>12</sup> Although, there are studies that show prolonged retained corneal foreign body without appreciable reaction.<sup>13</sup>

After taking a detailed history of the mode of injury, visual acuity, pupillary reflexes, intraocular pressure, extraocular movements should be noted. Slit-lamp evaluation and fundus examination should be carried out to locate the site of impaction.<sup>14</sup> Double eversion of the eyelid should be carried out, and fornices should be examined under diffuse illumination. Objects like glass pieces and plastic bits are difficult to focus on due to their transparent nature. Hence, various techniques of illumination can be employed to identify the object. Making a slit section of the cornea is useful in assessing the depth of penetration of a foreign body, especially if the site of impaction is in the stroma. If the depth of entry could not be assessed under a slit lamp, it is always advised to remove the foreign body under an operating microscope to prevent inadvertent injury to surrounding tissue. Blind manipulation can also lead to the displacement of the foreign body into the anterior chamber.

Fluorescent staining is advocated to look for corneal abrasion and to check for Seidel's positive. On staining the traumatic area, washing out of the dye indicates aqueous leakage from the AC and should be repaired as early as possible. The anterior chamber should be assessed for hyphema, angle, cells or flare.<sup>10</sup> Even though ocular pressure should be monitored, tonometry should be avoided in suspected penetrating injuries in patients with corneal defects and corneal infections.<sup>15</sup> Foreign bodies that enter the eye can cause damage to the iris, lens, and can even reach the posterior segment in high-velocity injuries.

Since most of the injuries occur accidentally at the workplace, metallic foreign bodies are the most commonly encountered ones in the ER.<sup>16</sup> The first step in emergency management is copious saline irrigation which can wash out any loose rust particles or dust lodged in the fornices

and cul de sac.<sup>17</sup> There are many techniques described for the removal of ferruginous foreign bodies. To alleviate the pain, one drop of local anaesthetic can be instilled in the eye. Loose particles present superficially can be removed using a cotton tip applicator moistened with a local anaesthetic agent. The tip can be gently rolled over the foreign body, which aids in its removal by lifting it off from the corneal surface.<sup>18</sup> Another method of removing superficial corneal foreign body, especially rust ring, is by gently scraping the cornea and lifting the foreign body with the bevelled edge of a 25G needle attached to a tuberculin syringe.<sup>18</sup> (Figure 3c) Metallic foreign bodies can give rise to the formation of rust rings if left beyond 12 hrs.<sup>19</sup> Various studies have shown that if removal is delayed, in case of any material, especially deeply seated; it can later lead to scarring, which alters the quality of vision and increases the risk of infections.<sup>16</sup> Debriding more than what is required can cause damage to Bowman's layer and deeper, which can result in irreversible scarring.<sup>20</sup> Once the foreign body is removed, repeat saline irrigation and fluorescein test can be repeated to check corneal abrasions. Smaller corneal abrasions heal by themselves. Large abrasions caused by organic matter have higher chances of infection, and they should be followed up after 24hrs. The abrasions are treated with lubricant and antibiotic eye drops.<sup>21</sup> Studies have shown that using an electric drill in removing the retained rust ring is superior to a manual drill in achieving a better outcome and less patient discomfort.<sup>6</sup> (Figure 3d)

Organic foreign bodies can include insect parts, wooden chips, bamboo splinters, husk, caterpillar hair etc. which, if not removed urgently, can lead to reactive inflammation. They can also act as a nidus for infection.<sup>22</sup> In 1950 a case was reported in which a patient had a retained grain particle embedded in the cornea for nearly 15 years. Although the patient was asymptomatic, corneal perforation with iris tissue incarceration was found upon removal of the foreign body.<sup>23</sup>

In cases such as a deeply embedded foreign body, where surgical removal is imminent, fine-tipped forceps can be used to gently remove the object along its tract of entry. (Figure 5b) The procedure can be done under topical anaesthesia or under sedation in the case of pediatric patients. After removal, Seidel's test can be done if we suspect aqueous leakage. Sometimes, the foreign body can partially enter the anterior chamber, which needs very cautious surgical management. Yang has reported a case of a complicated deep foreign body that has entered the anterior chamber partially. A 6mm suture needle was passed beneath the foreign body so that the anterior opening of the wounds was everted. (Figure 5c) This facilitated easy removal of the foreign body without any complications. (Figure 5d) The use of a suture needle facilitated better light reflection, maintenance of the anterior chamber, easy removal of the foreign body, and better globe fixation. Also, it was less

expensive and also helped in less endothelial cell loss because of less manoeuvring of the anterior chamber.<sup>24</sup>

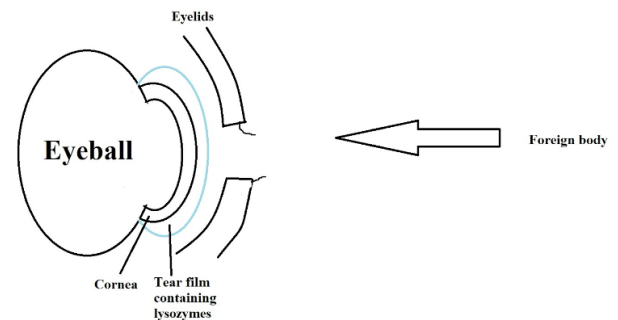
In their study on deep corneal foreign body removal, Duan and Yan have used a needle hook as the surgical aid. They used a 40G needle to make a needle hook. Their study also advocates surgeons debride any necrotic corneal tissue, cut open the tunnel lodged with the foreign body with a keratome and scrape off the dead tissue so that further complications can be prevented. Once the inflamed stroma is denuded, the tunnel should be closed with intermittent sutures to prevent the incidence of infection. (Figure 5e) The foreign body can also be sent for culture and sensitivity.<sup>25</sup> Accidental injury with a pencil can lead to the deposition of graphite particles in the cornea. Philip et al. have documented graphite particles in the anterior stroma of a child three years after the injury. Since there was no deficit in vision and no evidence of inflammation, the child was kept under observation.<sup>26</sup>

Polystyrene fragments have also been found in the mid stroma, presenting with glare complaints and a remarkably good visual acuity. The plastic piece containing polystyrene was embedded in the stroma for five years without causing vision loss. Since there was a foreseen possibility of lens damage while removing the foreign body and entering the anterior chamber, the surgeon preferred corneal transplantation.<sup>27</sup> Although intracorneal cilia has shown to produce no reaction, a decrease in the endothelial cell count has been reported. The loss might be due to the mechanical effect or biochemical reaction caused by the cilia.<sup>28</sup> Authors have also described caterpillar hair in the corneal stroma, which even penetrated the anterior chamber. (Figure 5a) Since it is organic, associated inflammatory reactions and vitreous exudates were present but with unaffected visual acuity. AS-OCT was used to confirm the location of the hair, and the condition was managed by topical and oral steroids, cycloplegics and antibiotics. Later the patient was kept on low dose steroid after tapering the dose, although the final outcome after withdrawing steroids was not mentioned.<sup>29</sup> The penetration of hair may be aided by its shape and structure, ocular movements and vascular pulsations. The granulomatous reaction which follows depends on the number of hair which has entered the eye.<sup>30</sup> Intracorneal hair and cilia have been reported by other authors also. Using a Jeweler's forceps, microblade and 30gauge needle, hair trapped in the anterior stroma was successfully removed.<sup>31</sup> Some surgeons prefer to leave the intrastromal hair in situ if the vision is unaffected and no active inflammation.<sup>32</sup> Ocular trauma can also cause entrapment of cilia in the cornea and conjunctiva. In case of multiple lashes, the central ones can be removed through the epithelium while those on the limbus via a conjunctival peritomy.<sup>33</sup>

In case of foreign bodies like sugar cane or bamboo splinters, which are embedded in the anterior corneal

stroma, blunt-tipped surgical forceps can be used to gently pinch and pull the splinter in the direction of the tunnel created.

Although corneal foreign bodies constitute the majority of cases being reported in the eye casualty, most of them do not hamper vision. Organic foreign bodies should be removed in the same sitting itself to prevent the incidence of infection. Suppose the pupillary area of the cornea is affected and the object is deeply buried in the stroma; in that case, it can affect the quality of vision due to stromal scarring and astigmatism.<sup>25</sup> Once a foreign body is removed, treatment mainly consists of topical lubricants and antibiotics. In the case of larger corneal defects caused by the injury, eye ointments are preferred to eye drops since the former provides prolonged contact time and reduces friction caused by the lids.<sup>20</sup> Topical anaesthetic agents should not be prescribed since it delays wound healing. Steroids are contraindicated in case of organic foreign bodies as they can flare up an occult fungal infection.<sup>34</sup> Also, occupational health education is of utmost importance to prevent workplace hazards. Proper use of protective goggles and face shields, regular eye examinations, and timely intervention in case of an accident help maintain a good quality of vision and prevent further complications.



**Fig. 1:** Illustration of the normal protective barriers of the eye.

### 1.7. Role of suturing and tissue adhesive glue

A foreign body may leave a tissue defect depending on its size and velocity, which it hits the cornea. The primary aim is to maintain a clear cornea, remove the foreign material, and a fully formed anterior chamber.

How to proceed further with a corneal wound depends on the tissue loss and the depth of injury. In the case of self-sealed wounds, conservative management with prophylactic antibiotics and steroids is required if the size is less than 2mm. Applying a bandage contact lens will provide further wound stability. (Figure 4d) In case of large self-sealed wounds, the management options include suturing and tissue adhesive glue. Suturing is preferred in kids and patients who might unintentionally

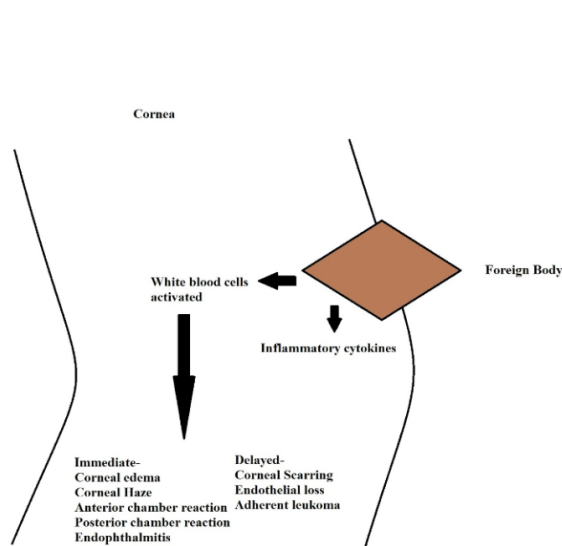
**Table 1:** Literature on removal of corneal foreign bodies according to different layers

Author/Year	Pt age/Sex	Location of Foreign body type	Technique used	Outcome
<b>Epithelial foreign bodies</b>				
Brown N et al. 1975	121 patients. Age and sex not mentioned	Corneal rust ring +/- ferrous foreign body	Foreign body removed with the help of 40mm x 0.8 mm needle. Patients divided into two groups for removal of rust ring by manual drill and electric drill and compare the results between them	Electric drill was found to cause less pain, more precise removal . It was quicker and safer than manual methods. Pain relief was also more rapid in the electric drill group.
Sigurdson H et al. 1987	59 Male patients and 1 female	Corneal rust ring	Patients divided into two groups of 30 each. And compared the efficacy of rust ring removal using hypodermic needle vs electric drill	Patients who underwent electric drill removal had better epithelial healing. It is also a faster method.
<b>Superficial stromal or anterior foreign bodies</b>				
Guerin et al. 2008	27year/F	Hair fragment which migrated from limbus to paracentral area	Removed under topical anesthesia	Good outcome without any scarring
Jinagal et al. 2018	5 year/M	Plastic paper sheet in the superficial stroma	Removed with forceps, unhealthy epithelium scraped off and bandage contact lens applied	Post-operative AS-OCT showed corneal thinning and scarring
Philip et al. 2012	12 year/F	Graphite particles in anterior stroma	No intervention done as eye was quiet	Patient was kept on follow-up
Doulas et al. 2003	31year/M	Mid stromal polystyrene fragment	Patient underwent corneal transplantation	Intraoperatively uneventful. Post op status of the patient and other details not mentioned
Soon K Alexander et al. 2019	30year/F	Human hair in anterior stroma	Hair removed with the help of Jeweler's forceps, microblade and 30gauge needle	Complete resolution of anterior segments reaction with 20/20 vision
<b>Deep stromal foreign bodies without involving the Descemet's membrane</b>				
Duan et al. 2013	7 males and 5 females aged 5 to 56 years (total of 12 patients)	4/12 were wooden foreign bodies 3/12 were bamboo 5/12 were thorns	Suture needle technique assisted with keratome to cut open the tunnel	Favourable outcome
<b>Full Thickness impacted foreign bodies</b>				
Yang et al. 2000	8eyes/patients were studied. Age and sex were not mentioned	4/8 were glass piece 3/8 were thorn 1/8 was stone fragment All eight foreign bodies penetrated the cornea and distal end was projecting into the anterior chamber	Suture needle technique(6mm needle, 10-0 Ethicon, United Kingdom) to evert the wound edges	Favourable outcome with less endothelial cell loss
Olorenshaw et al. 1991	31year/M	Cilia adhered to corneal scar with tip projecting into angle of anterior chamber	Topical decongestants given for ocular irritation	Patient presented with low specular count mostly due to mechanical or biochemical effects of the eyelash. No follow up specular count mentioned.
Singh R et al, 2017	12year/M	Caterpillar hair on the superficial and deep corneal stroma . Few hair ends were projecting into the anterior chamber with associated vitreous cells	Topical treatment with prednisolone, homatropine and moxifloxacin. Oral steroids also added	Number of hair reduced. Patient was kept on steroids since posterior segment lesions increased. Two months later, the hair reduced, but the patient kept on tapering steroids since inflammation was present.
Shankar V et al. 2015	32year/M	Multiple hair fragments in epithelium, superficial stroma. One deep stromal hair, with its lateral tip in the anterior chamber. Stromal scar seen at the level of Descemet's membrane	No attempt to remove hair as eye was quiet and vision was 20/20	Specular revealed low specular count.

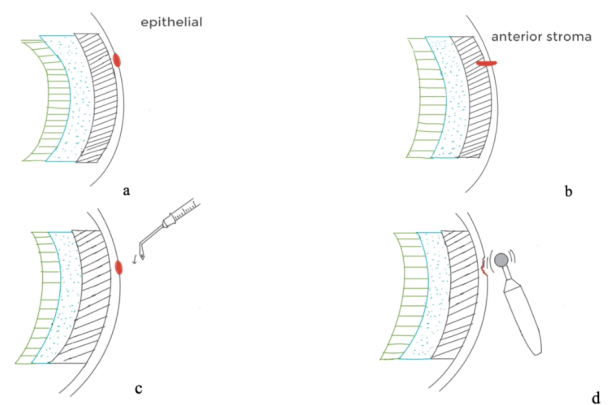
**Table 2:** Table showing the preferred method of foreign body removal based on previous studies

Layer of cornea and type of foreign body	Method of removal	Advantage
Superficial epithelial foreign body eg:ferrous foreign body/ rust ring	A hypodermic needle can be used to lift off the ferrous particle . Followed by electric drill removal of the retained rust ring	<ul style="list-style-type: none"> <li>• Hypodermic needle cause less trauma</li> <li>• Electric drill is quick, safer and causes less patient discomfort. Also promotes better wound healing</li> </ul>
Anterior stromal foreign body	Removal with the help of a forceps can be achieved in case of a foreign body occupying the anterior 1/3 of stroma if the proximal end is superficial to the epithelium. Else the epithelium can be gently debrided with a microblade and the foreign body removed by gently pulling with the forceps Preoperative ASOCT can be done i n case of any doubt regarding the depth of penetration	<ul style="list-style-type: none"> <li>• Can be done under a slit lamp or operating microscope</li> <li>• Easy availability of instruments and less traumatic</li> </ul>
Mid stromal foreign bodies	Preoperative ASOCT will give a better assessment regarding the depth of impaction. After scraping off the superficial stroma, the tunnel can be cut open with a keratome under an operating microscope and the material can be removed with a suture needle All the necrotic tissue should be debrided and a bandage contact lens can be applied if necessary	<ul style="list-style-type: none"> <li>• ASOCT is advantageous especially in case of transparent foreign bodies like glass/ plastic</li> <li>• Removing the necrotic stroma reduces the chance of further tissue damage and infection .</li> </ul>
Full thickness injuries with distal end of foreign body in the anterior chamber	A forceps can be used to hold the edges of entry wound Passing a 6mmsuture needle through the tract will help in everting the edges and the foreign body can then be removed with a jewelers forceps or intravitreal forceps After removal , the wound can be suture with 10-0 monofilament nylon sutures	<ul style="list-style-type: none"> <li>• Less manoeuvring of anterior chamber</li> <li>• Better preservation of endothelial cell count</li> </ul>

NB: All the procedures should be followed by prescription of antibiotic drops, lubricants and cycloplegics if necessary. Organic foreign bodies should be given a broad spectrum antifungal coverage until culture reports are available. Antibiotics can be modified accordingly based on the organism isolated



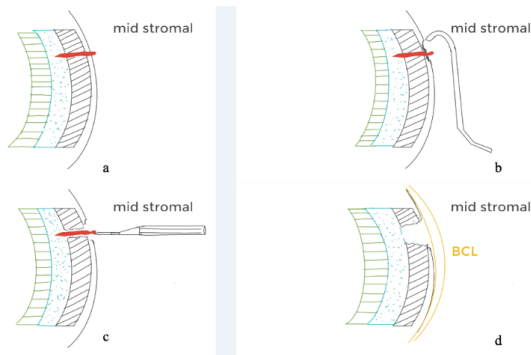
**Fig. 2:** Cascade of events following foreign body impaction.



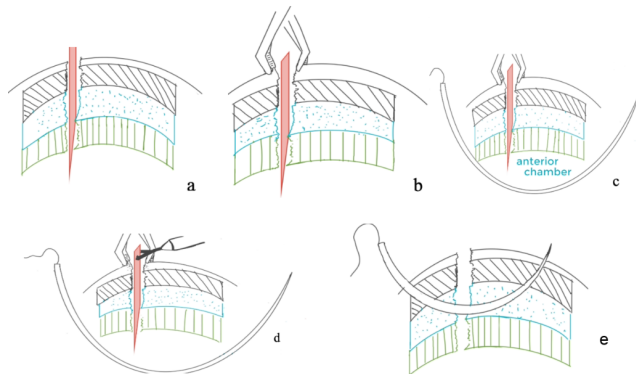
**Fig. 3:** Sketch diagram showing removal of superficial foreign body in case of epithelial(a), or that involving anterior stroma(b) with the help of a 26G bend needle(c) and an electric drill to remove the remaining rust ring.

rub the eyes postoperatively.<sup>35</sup> Although suturing can cause astigmatism in the future, the final decision depends on





**Fig. 4:** Sketch diagram showing removal of deep foreign body embedded in midstroma(a). Using a iris hooks(b), the dead tissue around the entry wound is scrapped off and then the foreign body is removed using a 26G needle(d). Small defects (<3mm) can be covered with a bandage contact lens to re-epithelise and heal.



**Fig. 5:** Sketch diagram showing deeply embedded foreign body with penetration into the anterior chamber(a). Using a limbs/ tissue holding forceps the foreign body is secured(b) and a 6mm suture needle is passed beneath the foreign body so that the anterior opening of the wounds was everted(c). Now using an end grasping forceps (Jeweler's forceps) the foreign body is gently pulled out, while the tissue holding forceps holds both the ends of the wound(d). The full thickness wound is now sutured using 10 monofilament suture.

the wound integrity and a maintained anterior chamber. Partial-thickness lacerations tend to heal themselves without intervention.<sup>36</sup> But if there is an associated flap, care should be taken to reposition it in place with partial-thickness sutures. For this, 10-0 nylon or 11-0 nylon sutures can be used. A flap that is not displaced can be managed by placing a bandage contact lens. A full-thickness corneal wound invariably requires suturing, and care should be taken to bury all the suture knots at the end of surgery. The depth of the suture should be 90 per cent of the total thickness.<sup>36</sup> In case of bevelled edges, centration of the suture with respect to the posterior aspect of the wound will give better apposition of edges. If there is a loss of corneal tissue, the management depends upon the size of the defect. A

small defect can be repaired by suturing with a foreseen complication like astigmatism, and a defect exceeding 5mm in diameter should be repaired by a patch graft. Tissue adhesive glues can manage defects of size up to 3mm. Fibrin glue provides better wound healing, but the plug formation takes a longer time than cyanoacrylate glue. In contrast, cyanoacrylate glue starts to polymerise immediately on exposure to air. Care should be taken to properly dry the cornea before applying cyanoacrylate glue. Glue is applied to the defect after all the necrotic tissues are removed and after confirming that there is no iris / foreign body at the wound site.<sup>37</sup> Minimal tissue handling and avoiding suture bites in the visual axis are other measures to achieve better postoperative outcomes.<sup>35</sup>

As small epithelial defects heal with adequate conservative management, the chances of fungal invasion into the stroma is infrequent in an immunocompetent individual. Topical fluoroquinolone, which has a broad spectrum of action against various microbes, will be adequate for proper coverage. Whereas in the case of larger wounds created by organic matter associated with tissue necrosis, a broad-spectrum antifungal like Natamycin 5 % can be added after sending the sample for fungal culture and sensitivity modifying the medication based on culture report.

## 2. Conclusion

Corneal foreign bodies constitute the majority of eye casualties. A proper preoperative history, examination and investigations will help in deciding the management. Superficial epithelial foreign bodies can be removed with the help of a hypodermic needle. Stromal foreign bodies are better managed after getting AS-OCT done since it helps in assessing the depth and also helps in identifying transparent materials. If a tunnel is present in the stroma, it should be opened, and necrotic tissue should be debrided. Less handling of the anterior chamber helps in preserving the endothelial cell count. A suture needle can be of use in such cases as mentioned in Table: A properly formed anterior chamber should be confirmed after every surgical procedure. Patients should be prescribed topical medications and steroids in case of active inflammation. A strict follow-up and adherence to the post-operative medications from the patient's side is required. As prevention is always better, counselling regarding the use of protective eyewear/shields in workplaces, abstinence from dangerous sports activities and health education at various levels can decrease the incidence of such accidents.

## 3. Authors Contribution

Sahil Agrawal MD and Saloni Gupta MS, Both the authors have equal contribution for authorship.

#### 4. Acknowledgement

None.

#### 5. Source of Funding

None.

#### 6. Conflicts of Interest

All contributing authors declare no conflict of interest.

#### References

- Qayum S, Anjum R, Garg P. Epidemiological pattern of ocular trauma in a tertiary hospital of Northern India. *Int J Med Clin Res*. 2016;7:420–2.
- Ahmed F, House RJ, Feldman BH. Corneal Abrasions and Corneal Foreign Bodies. *Primary Care*. 2015;42(3):363–75. doi:10.1016/j.pop.2015.05.004.
- Agrawal C, Girgis S, Sethi A, Sethi V, Konale M, Lokwani P, et al. Etiological causes and epidemiological characteristics of patients with occupational corneal foreign bodies: A prospective study in a hospital-based setting in India. *Indian J Ophthalmol*. 2020;68(1):54–7. doi:10.4103/ijo.ijo\_623\_19.
- Pandey AN. Ocular Foreign Bodies: A Review. *J Clin Exp Ophthalmol*. 2017;8(2):2–5. doi:10.4172/2155-9570.1000645.
- Dua HS, Forrester JV. The Corneoscleral Limbus in Human Corneal Epithelial Wound Healing. *Am J Ophthalmol*. 1990;110(6):646–56. doi:10.1016/s0002-9394(14)77062-x.
- Brown N, Clemett R, Grey R. Corneal rust removal by electric drill. Clinical trial by comparison with manual removal. *Br J Ophthalmol*. 1975;59(10):586–9. doi:10.1136/bjo.59.10.586.
- Guerin E, Alexander P, Lanyon P, Robinson K, Foss A. A reminder that temporal arteritis is not necessarily giant cell arteritis. *Eye*. 2009;23(7):1608–9. doi:10.1038/eye.2008.294.
- Jinagal J, Gupta G, Maurya DC, Ram J. Transparent Corneal Foreign Body - A Diagnostic Challenge in Children. *Delhi J Ophthalmol*. 2018;doi:10.7869/djo.397.
- Upshaw JE, Brenkert TE, Losek JD. Ocular Foreign Bodies in Children. *Pediatr Emerg Care*. 2008;24(6):409–14. doi:10.1097/pec.0b013e318177a806.
- Babineau MR, Sanchez LD. Ophthalmologic Procedures in the Emergency Department. *Emerg Med Clin North Am*. 2008;26(1):17–34. doi:10.1016/j.emc.2007.11.003.
- Rothman M. Orbital trauma. Seminars in Ultrasound. *CT MRI*. 1997;18(6):437–47.
- Parrish CM, Chandler JW. Corneal trauma: corneal foreign bodies. In: Kaufman H, Barron B, McDonald M, editors. *The Cornea*. vol. 1988. New York, NY: Churchill Livingstone; p. 621–2.
- Covert DJ, Henry CR, Sheth BP. Well-Tolerated Intracorneal Wood Foreign Body of 40-Year Duration. *Cornea*. 2009;28(5):597–8. doi:10.1097/ico.0b013e3181901e1f.
- Kercheval DB, Terry JE. Essentials of slit lamp biomicroscopy. *J Am Optom Assoc*. 1997;48(11):1383–9.
- Dennis WR, Dennis AM. Eye emergencies. In: Stone C, Humphries E, editors. *Current emergency diagnosis and treatment*. 5th Edn. Lange Medical Books/ McGraw-Hill; 2004.
- Ozkurt ZG, Yuksel H, Saka G, Guclu H, Evsen S, Balsak S. Metallic corneal foreign bodies: an occupational health hazard. *Arq Bras Oftalmol*. 2014;77(2):81–3. doi:10.5935/0004-2749.20140020.
- Jayamanne DGR, Bell RWD. Non-penetrating corneal foreign body injuries: Factors affecting delay in rehabilitation of patients. *J Accid Emerg Med*. 1994;11(3):195–7.
- Wilson SA, Last A. Management of corneal abrasions. *Am Fam Physician*. 2004;70:123–8.
- Casser L, Fingeret M, Woodcome H. Atlas of primary eyecare procedures. New York: Appleton Lange; 1990.
- Knoop KJ, Dennis WR, Hedges JR. Ophthalmologic procedures. In: Roberts M, Hedges JR, editors. *Clinical procedures in emergency medicine*. 4th Edn.; 2003.
- Schwartz GR. Ocular foreign body removal. In: *Principles & practice of emergency medicine*. 4th edn. Lippincott Williams & Wilkins; 1999.
- Zauberman H, Neumann E. Superficial Corneal Foreign Bodies of Organic Origin\*. *Am J Ophthalmol*. 1965;60(3):467–9. doi:10.1016/0002-9394(65)90713-0.
- Sedan J, Sedan-Bauby S. Contribution à la neuroclinique du glaucome. *Ophthalmologica*. 1949;118(4-5):534–47.
- Yang X. Removal of corneal foreign bodies that project into the anterior chamber: use of a suture needle. *Am J Ophthalmol*. 2000;129(6):801–2.
- Duan H, Yan S. Clinical efficacy of surgical removal of deep corneal plant foreign bodies. *Eye Sci*. 2013;28(1):30–3.
- Philip SS, John D, John SS. Asymptomatic Intracorneal Graphite Deposits following Graphite Pencil Injury. *Case Reports in Ophthalmological Medicine*. 2012;p. 1–2.
- Doulas K, Apostolakis K, Feretis D. A long-standing, deep, intracorneal foreign body. *Acta Ophthalmologica Scand*. 2003;81(1):81–2. doi:10.1034/j.1600-0420.2003.00028\_4.x.
- Olorenshaw GM, Brooks AM, Grant G, Gillies WE. Tolerance of the eye for implanted cilia. *Br J Ophthalmol*. 1991;75(10):622–3. doi:10.1136/bjo.75.10.622.
- Singh R, Tripathy K, Chawla R. Caterpillar hair in the eye. *BMJ Case Rep*. 2017;doi:10.1136/bcr-2017-219392.
- Watson PG, Sevel D. Ophthalmia nodosa. *Br J Ophthalmol*. 1966;50(4):209–17. doi:10.1136/bjo.50.4.209.
- Soon AK, Mather R. Chronic, Stromal Foreign Body of Presumed Human Origin, following Corneal Abrasion. *Case Rep Ophthalmol Med*. 2019;doi:10.1155/2019/9607282.
- Shanker V, Nigam V, Mathur U. Retained intracorneal human hair fragment: An unusual case of occupational trauma. *Oman J Ophthalmol*. 2015;8(1):67. doi:10.4103/0974-620x.149876.
- Casswell EJ, Anikina EV, Mearza AA. Traumatic insertion of eyelashes into corneal stroma. *Contact Lens and Anterior Eye*. 2014;37(5):388–9. doi:10.1016/j.clae.2014.04.006.
- Newell SW. Management of corneal foreign bodies. *Am Fam Physician*. 1985;31(2):149–56.
- Biju J, Chitra R. Open Globe Injuries-Primary Repair of Corneoscleral Injuries- Major Review. *Kerala J Ophthalmol*. 2010;XXII(3):225–34.
- Rathi A. Ocular surface injuries & management. *Community Eye Health*. 2017;30(99):11–4.
- & Mohan S, Aggarwal, & Anand, Mohan S, Aggarwal A, Panda A, et al. Repair of Corneoscleral Perforations. *DOS Times*. 2008;14(2):21–26.

#### Author biography

**Sahil Agrawal**, Senior Resident

**Sandton J S Raj**, Junior Resident

**Sujeeth Modaboyina**, Senior Resident

**Rahul Bafna**, Senior Resident

**Saloni Gupta**, Consultant

**Deepsekhar Das**, Senior Resident

**Cite this article:** Agrawal S, Raj SJS, Modaboyina S, Bafna R, Gupta S, Das D. Management of impacted corneal foreign bodies: A review. *IP Int J Ocul Oncol Oculoplasty* 2021;7(2):131-138.