

Content available at: <https://www.ipinnovative.com/open-access-journals>

Indian Journal of Clinical Anatomy and Physiology

Journal homepage: <https://www.ijcap.org/>

Original Research Article

Study of contributing arteries to superficial palmar arch formation

Bangale Sridevi P^{1,*}

¹Dept. of Anatomy, MIMSR Medical College, Latur, Maharashtra, India



ARTICLE INFO

Article history:

Received 11-08-2021

Accepted 24-09-2021

Available online 07-12-2021

Keywords:

Ulnar artery

Radial artery

Median artery

Superficial palmar arch

ABSTRACT

The superficial palmar arch (SPA) is formed predominantly by the ulnar artery with a contribution from the superficial palmar branch of the radial artery.

Aim: To study contributing arteries in superficial palmar arch formation and variations in its formation.

Material and Methods: Study comprised of 30 upper limbs from 15 cadavers. Palmar arches in them were dissected following classical incisions and dissection procedures of Cunninghams' manual.

Results: SPA was formed by superficial branch of ulnar artery only in 13.33% specimens, by superficial branch of both ulnar and radial artery in 70% specimens, by superficial branch of ulnar and persistent median artery in 13.33% specimens and was formed by superficial branches of ulnar and radial arteries with persistent median artery in 3.33% specimens. SPA was complete in 80% and was incomplete in 20% specimens.

Conclusion: The arch formation is highly variable. Knowledge of contribution to the SPA will be helpful to the reconstructive hand surgical procedures such as arterial repairs, vascular graft applications and re-implantations.

This is an Open Access (OA) journal, and articles are distributed under the terms of the [Creative Commons Attribution-NonCommercial-ShareAlike 4.0 License](https://creativecommons.org/licenses/by-nc-sa/4.0/), which allows others to remix, tweak, and build upon the work non-commercially, as long as appropriate credit is given and the new creations are licensed under the identical terms.

For reprints contact: reprint@ipinnovative.com

1. Introduction

Superficial palmar arch (SPA) is formed by direct continuation of ulnar artery beyond flexor retinaculum. It is often not a complete arch. If it is complete it becomes continuous with superficial palmar branch of radial artery.¹ About a third of the superficial palmar arches are formed by the ulnar artery alone; a further third are completed by the superficial palmar branch of the radial artery; and a third by the arteria radialis indicis, a branch of either arteria princeps pollicis or the median artery.² So there are different views on contributing arteries and completeness of arch formation in different books. So aim of this study is to note usually contributing arteries and variations related to superficial palmar arch (SPA) formation. Objectives of this study are 1) study of contributing arteries to superficial palmar arch

formation. 2) to note superficial palmar arch is complete / incomplete. 3) to note any variation present / absent.

2. Materials and Methods

Study was done on 15 formalin (10%) embalmed adult cadavers, 11 males & 4 females (30 sides). Decomposed, amputated, injured and specimens from children were excluded from study. Vertical incision was taken on Palm and skin reflected laterally. Palmar aponeurosis was identified with palmaris longus (PL) tendon. PL tendon was cut and aponeurosis reflected distally. Median and ulnar nerve & their branches in relation to arteries forming superficial palmar arch & flexor retinaculum were dissected meticulously till digital branches.

* Corresponding author.

E-mail address: drsridevibangale@gmail.com (B. Sridevi P).

3. Results

SPA was formed by superficial branch of ulnar artery only in 4 cases out of 30 (13.33%) (Figure 1). SPA was formed by superficial branch of both ulnar and radial artery in 21 cases out of 30 (70%) (Figures 2 and 3). SPA was formed by superficial branch of ulnar and persistent median artery in 4 cases out of 30 (13.33%) (Figure 4). And in single case SPA was formed by superficial branches of ulnar and radial arteries with persistent median artery (3.33%) (Figure 5).

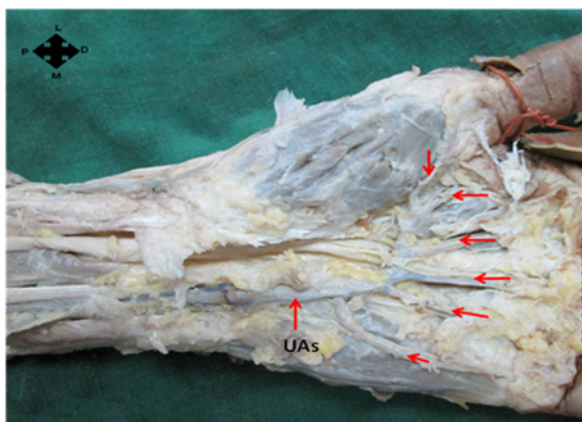


Fig. 1: Illustration showing incomplete superficial palmar arch formed by superficial branch of ulnar artery (UAs) only, supplying 5 fingers

With respect to complete and incomplete arch formation of superficial palmar arch, it was observed that in 24 cases out of 30, SPA was complete (80%) (Figures 2 and 4) and in 6 cases out of 30, arch was incomplete (20%) (Figures 1, 3 and 5).

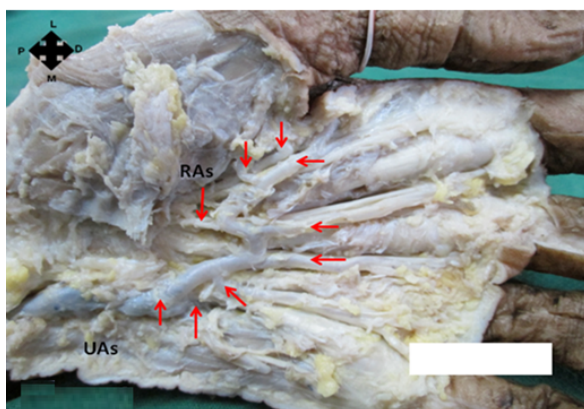


Fig. 2: Illustration showing complete superficial palmar arch formed by superficial branch of ulnar artery (UAs) and superficial branch of radial artery (RAs) supplying 5 fingers

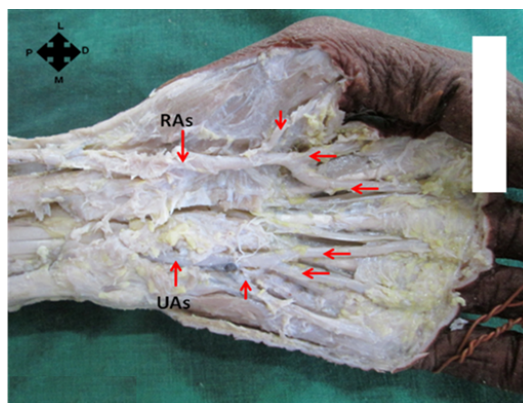


Fig. 3: Illustration showing incomplete superficial palmar arch formed by superficial branch of ulnar artery (UAs) and superficial branch of radial artery (RAs) supplying 5 fingers

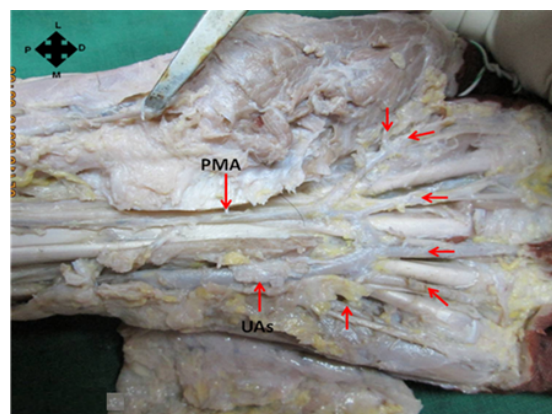


Fig. 4: Illustration showing complete superficial palmar arch formed by superficial branch of ulnar artery (UAs) and persistent median artery (PMA) supplying medial $4\frac{1}{2}$ fingers

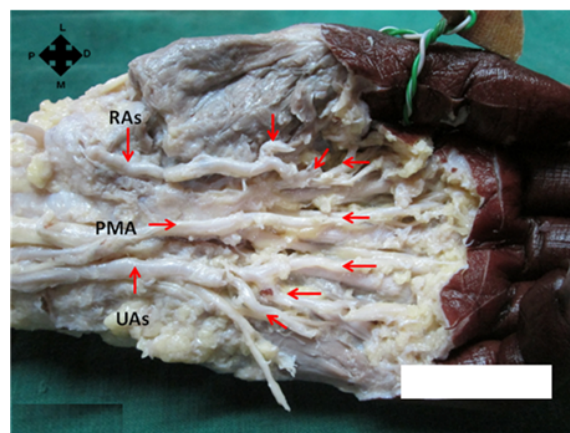


Fig. 5: Illustration showing incomplete superficial palmar arch formed by superficial branch of ulnar artery (UAs), persistent median artery (PMA) and superficial branch of radial artery (RAs) supplying 5 fingers

Table 1: Comparison of findings of present study with previous studies in view of arteries contributing in formation of superficial palmar arch

Contributing arteries	Ulnar artery only	Ulnar and radial arteries	Ulnar and median arteries	Ulnar, median and radial arteries
Anitha et al ³	–	–	6%	Absent
Coleman and Anson ⁴	37%	68%	3.8%	1.2%
Ikeda et al ⁵	–	–	0.9%	Absent
Adachi ⁶	–	–	9%	–
Jaschtschinski S. N ⁷	38%	–	–	–
MAJ Mozersky DJ et al ⁸	88%	–	–	–
Earley ⁹	20%	–	–	–
Gellman H et al ¹⁰	31.1%	–	–	–
Suman U et al ¹¹	50%	–	–	–
Present study	13.33%	70%	13.33%	3.33%

Table 2: Comparison of present study findings with previous studies in view of complete or incomplete formation of superficial palmar arch

SPA Authors	Complete	Incomplete
Moore KL ; clinically oriented anatomy ¹²	34.5%	65.5%
Coleman et al ⁴	78.5%	21.5%
Ikeda et al ⁵	96.4%	3.6%
Gellman et al ¹⁰	84.4%	15.6%
Al Turk & Metcalf ¹³	84.4%	15.6%
Anitha et al ³	75%	25%
Present study	80%	20%

4. Discussion

Present study was compared with previous studies in view of arteries contributing in formation of SPA as shown in Table 1. Results of present study are comparable with studies of Coleman and Anson⁴ and Earley.⁹

In view of complete / incomplete SPA, present study is compared with previous studies as demonstrated in table no. 2. Results of present study are equivalent to that of Coleman et al,⁴ Gellman et al,¹⁰ Al Turk and Metcalf,¹³ Anitha et al³ studies.

5. Conclusion

The findings suggest that majority of hands showed complete arch which indicates that collateral circulation is present in majority of cases.

While harvesting radial artery for use as arterial bypass conduits or while harvesting the free radial forearm flap, the need to look specifically for variation in collateral circulation, like presence of incomplete arch is a must. Knowledge of usual contributing arteries and its anatomical variations is important for hand surgeries, such as arterial repairs, vascular grafts.

6. Source of Funding

None.

7. Conflict of Interest

The authors declare no conflict of interest.

References

1. McMinn RMH. Wrist and hand. In: Last's anatomy regional and applied. New York: Churchill Livingstone; 1995. p. 110.
2. Williams PL, Bannister LG, Berry MM. Gray's Anatomy. 38th ed. New York: Churchill Livingstone; 2000. p. 1544.
3. Anitha T, Kalbande S, Dombé D. Variations in the formation of superficial palmar arch and its clinical significance in hand surgeries. *Int J Biol Med Res.* 2011;2(2):543–6.
4. Coleman SS, Anson BJ. Arterial patterns in the hand based upon a study of 650 specimens. *Surg Gynecol Obstet.* 1961;113:409–24.
5. Ikeda A, Ugawa A, Kazihara Y, Hamada N. Arterial patterns in the hand based on a three-dimensional analysis of 220 cadaver hands. *J Hand Surg Am.* 1988;13:501–9.
6. Adachi B. Das arterien-system der Japaner, Kenkyusha. *Koyoto.* 1928;1:368–89.
7. Jaschtschinski SN. Morphologie und topographie des arcus volaris sublimis und profundus. *Anat Hefte.* 1897;7:163–88.
8. Mozersky DJ, Buckley CJ, Hagoood CO, Capps W, Dannemiller FJ. Ultrasonic evaluation of the palmar circulation. A useful adjunct to radial artery cannulation. *Am J Surg.* 1973;126(6):810–2. doi:10.1016/s0002-9610(73)80077-7.
9. Earley MJ. The arterial supply of the thumb, first web and index finger and its surgical application. *J Hand Surg.* 1986;11B(2):163–74.
10. Gellman H, Botte MJ, Shankwiler J, Gelberman RH. Arterial patterns of the deep and superficial palmar arches. *Clin Orthop Relat Res.* 2001;383:41–6.
11. Suman U, Jayanthi K. A study of complete superficial palmar arches formed entirely by ulnar artery. *J Anat Soc India.* 2011;60(2):199–201.
12. Moore KL, Dalley AF. Clinically Oriented Anatomy. 10th ed. Philadelphia: Lippincott: Williams and Wilkins; 1999. p. 751.

13. Al-Turk M, Metcalf WK. A study of the superficial palmar arteries using the Doppler Ultrasonic Flowmeter. *J Anat.* 1984;138:27–32.

Cite this article: Sridevi P B. Study of contributing arteries to superficial palmar arch formation. *Indian J Clin Anat Physiol* 2021;8(4):280-283.

Author biography

Bangale Sridevi P, Assistant Professor