

Content available at: <https://www.ipinnovative.com/open-access-journals>

Indian Journal of Clinical Anatomy and Physiology

Journal homepage: <https://www.ijcap.org/>

## Original Research Article

## A cadaveric study of relationship of external carotid artery with reference to adjacent anatomical landmarks

Anjalee G Ovhal<sup>1,\*</sup>, K Ravikumar<sup>1</sup>, Sachin Badge<sup>2</sup><sup>1</sup>Dept. of Anatomy, Late Baliram Kashyap Memorial Government Medical College, Jagdalpur, Chandigarh, India<sup>2</sup>Dept. of Pathology, Late Baliram Kashyap Memorial Government Medical College, Jagdalpur, Chhattisgarh, India

## ARTICLE INFO

## Article history:

Received 14-11-2021

Accepted 25-11-2021

Available online 07-12-2021

## Keywords:

Anatomical landmarks

Angle of the mandible

Cadavers

Carotid tubercle

External carotid artery

## ABSTRACT

**Background:** Evaluation of carotid bifurcation level and relationship of External Carotid Artery (ECA) with reference to adjacent anatomical landmarks is important in planning various surgical and radiological procedures related to the carotid arteries.

**Aims and Objectives:** The aim was to study the relationship of External Carotid Artery with reference to Adjacent Anatomical landmarks in cadavers.

**Materials and Methods:** 60 cadavers - 52 male and 8 female embalmed with 10% formalin were dissected over the period of two years for this study.

**Results:** The distance between the origin and the termination of ECA was found to be in the range of 25–70 mm on the right side and in the range of 25–68 mm on the left side. The distance between the origin of ECA and the carotid tubercle was found to be in the range of 23–50 mm on the right side and in the range of 22–48 mm on the left side. The distance between the origin of ECA and the angle of the mandible was found to be in the range of 18–30 mm on the right side and in the range of 20–32 mm on the left side.

**Conclusions:** The anatomical knowledge of relationship of External Carotid Artery with reference to adjacent anatomical landmarks is helpful for vascular surgeons to plan surgeries and prevent complications during various diagnostic and therapeutic procedures.

This is an Open Access (OA) journal, and articles are distributed under the terms of the [Creative Commons Attribution-NonCommercial-ShareAlike 4.0 License](https://creativecommons.org/licenses/by-nc-sa/4.0/), which allows others to remix, tweak, and build upon the work non-commercially, as long as appropriate credit is given and the new creations are licensed under the identical terms.

For reprints contact: [reprint@ipinnovative.com](mailto:reprint@ipinnovative.com)

## 1. Introduction

Evaluation of carotid bifurcation level with reference to other adjacent anatomical landmarks is important in planning various surgical, radiological procedures related to the carotid arteries. Hence a cadaveric study of External Carotid Artery was conducted over the period of two years.

The aim was to study the relationship of External Carotid Artery with reference to Adjacent Anatomical landmarks in cadavers.

60 cadavers - 52 male and 8 female embalmed with 10% formalin were dissected over the period of two years for this study.

\* Corresponding author.

E-mail address: [anjalee.ovhal@gmail.com](mailto:anjalee.ovhal@gmail.com) (A. G. Ovhal).

ECA was found to arise at the level of upper border of lamina of thyroid cartilage in 24 (40%) cases each on the right and left sides and the distance between the origin of ECA (bifurcation of CCA) and the upper border of lamina of thyroid cartilage ranged from -20 to +13 mm on the right side and -30 to +15 mm on the left side. The distance between the origin and the termination of ECA was found to be in the range of 25–70 mm on the right side and in the range of 25–68 mm on the left side. The distance between the origin of ECA and the carotid tubercle was found to be in the range of 23–50 mm on the right side and in the range of 22–48 mm on the left side. The distance between the origin of ECA and the angle of the mandible was found to be in the range of 18–30 mm on the right side and in the range

of 20 – 32 mm on the left side. The mean internal diameter of ECA at its origin was 9.7 mm on the right side and 10.8 mm on the left side. The mean internal diameter of ECA at its termination was 3.9 mm on the right side and 3.8 mm on the left side.

## 2. Aims and Objectives

The aim was to study the relationship of External Carotid Artery with reference to Adjacent Anatomical landmarks in cadavers.

The objectives were:

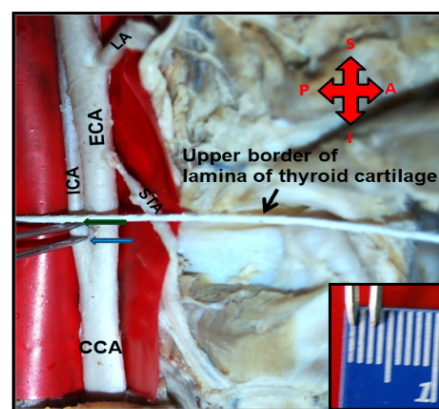
1. To measure the distance between the site of origin of ECA [bifurcation of Common Carotid Artery (CCA)] and upper border of lamina of thyroid cartilage.
2. To measure the distance between origin of ECA and the carotid tubercle/anterior tubercle of transverse process of 6<sup>th</sup> cervical vertebra (Chassaignac's tubercle).
3. To measure the distance between origin of ECA and the angle of the mandible.
4. To determine the site of origin of ECA with reference to cervical vertebrae.
5. To measure the internal diameter of ECA at its origin.
6. To measure the internal diameter of ECA at its termination.

## 3. Materials and Methods

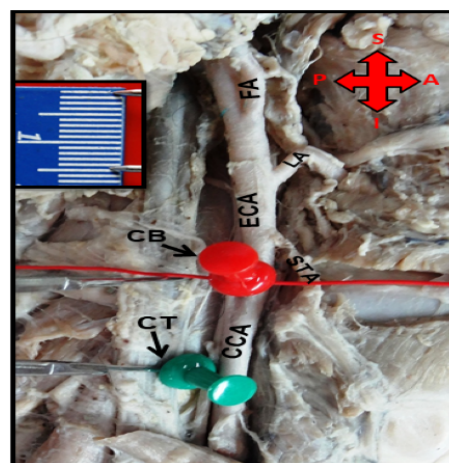
After dissecting the External Carotid Artery from origin to termination, its branches were cleared and exposed properly. Then the distance between the site of origin of ECA (bifurcation of CCA) and upper border of lamina of thyroid cartilage was measured with the help of a thread, a divider and a scale as illustrated in the Figure 1. The carotid tubercle/anterior tubercle of transverse process of 6<sup>th</sup> cervical vertebra (Chassaignac's tubercle) which is felt prominently was palpated. A pin was fixed on it to mark its location and then distance between origin of ECA and the carotid tubercle was measured with the help of thread and scale as illustrated in the Figure 2. The distance between origin of ECA and the angle of the mandible was measured as illustrated in the Figure 3. The cervical vertebrae were exposed as illustrated in the Figure 4 and the site of origin of ECA with reference to cervical vertebrae was determined.

Then the external carotid artery was cut transversely at its origin and at its termination to measure the internal diameter of ECA at its origin and termination. The internal diameters were measured in two axes with the help of a divider and a scale as illustrated in the Figures 5 and 6. The average internal diameter was calculated and noted down.

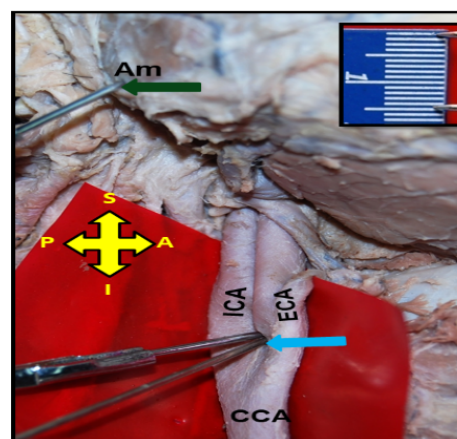
The data were statistically analysed for the purpose of comparison and correlation by calculating the Mean, Standard deviation and Range.



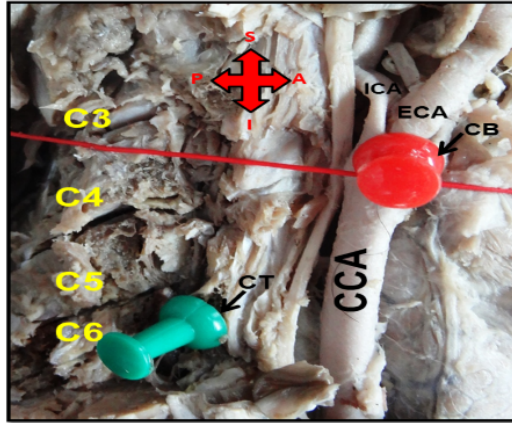
**Fig. 1:** Illustration showing measurement of the distance between the site of origin of right ECA (blue arrow) and the upper border of lamina of thyroid cartilage (green arrow)




**Fig. 2:** Illustration showing measurement of the distance between the site of origin of right ECA (red pin) and the carotid tubercle (green pin) [CB - bifurcation of CCA / origin of ECA, CT - carotid tubercle / Chassaignac's tubercle]




**Fig. 3:** Illustration showing measurement of the distance between the site of origin of right ECA (blue arrow) and the angle of the mandible (green arrow) [Am- angle of mandible]



**Fig. 4:** Illustration showing determination of the site of origin of right ECA with reference to cervical vertebrae [CB(red pin) - bifurcation of CCA / origin of ECA; CT (green pin) - carotid tubercle / Chassaignac’s tubercle; C1, C2, C3, C4 – cervical vertebrae]



**Fig. 5:** Illustration showing measurement of the internal diameter of ECA at its origin A: Transverse axis (red arrow) B: Antero-posterior axis (black arrow)



**Fig. 6:** Illustration showing measurement of the internal diameter of ECA at its termination A: Transverse axis (red arrow) B: Antero-posterior axis (black arrow)

**4. Results and Discussion**

**4.1. Origin of ECA with reference to upper border of lamina of thyroid cartilage**

Ribeiro, R. A et al. found that the distance of the CCA bifurcation from the superior border of the thyroid cartilage to be varying from -0.8 (below the level) to + 1.9 cm (above the level), with an average of  $0.9 \pm 0.1$  cm on the right side, with no differences between sides.<sup>1</sup>

Sanjeev I K, Anita H, Ashwini M et al. in their study found that the level of origin of the external carotid artery was at the superior border of the thyroid cartilage in 56.76% of the cases and it was found at a higher level (10-25mm above the superior border of the thyroid cartilage) in 16.22% of the cases. In 27.02% of the cases, the origin of the external carotid artery was found at a lower level (10-22 mm below the superior border of the thyroid cartilage). Developmentally, these variations result from the persistence of the channels that normally disappear or from the disappearance of the normally persisting vessels.<sup>2</sup>

In the present study, ECA was found to be arising at the level of upper border of lamina of thyroid cartilage in 24 cases (on both right and left sides) and the distance between the origin of ECA (bifurcation of CCA) and the upper border of lamina of thyroid cartilage ranged between -20 (below the level) to + 13 mm (above the level) on right side and - 30 to + 15 mm on the left side.

**Table 1:**

Studies	Distance between the origin of ECA (bifurcation of CCA) and upper border of lamina of thyroid cartilage (mm)
Ribeiro et al (2006)	- 8 to +19
Sanjeev et al (2010)	-10 to +25
Present study	-20 to +13 (Right) -30 to +15 (Left)

**4.2. Origin of ECA with reference to the carotid tubercle**

In the present study, the distance between the origin of ECA and the carotid tubercle (Chassaignac’s tubercle) was found to be in the range of 23-50 mm on the right side and 22-48 mm on the left side.

**Table 2:**

Studies	Distance between origin ECA and angle of mandible (mm)
Ribeiro et al (2006)	5-44
Present study	18-30 (Right) 20-32 (Left)



**Table 3:**

Vertebral level	D. Anangwe (2008)		Ribeiro et al (2006)		Present study	
	Right (%)	Left (%)	Right (%)	Left (%)	Right (%)	Left (%)
C2	12.5	12.5	60	78	-	-
C3	38.8	38.8	40	20	21.67	26.67
C3- C4	22.5	22.5	-	-	31.67	31.67
C4	7.5	7.5	-	-	33.33	36.67
C4-C5	-	-	-	-	3.33	0
C5	2.5	2.5	-	-	10	5
C6-C7	3.75	3.75	-	-	-	-

**Table 4:**

Studies	Internal diameter of ECA at origin (mm)	
	Right	Left
Ribeiro et al (2006)	7.3±0.2	7.1±0.2
Present study	9.7±2.1	10.8±14.5

**Table 5:**

Studies	Distance between origin of ECA and its termination (mm)
Sanjeev et al (2010)	60
Present study	25 – 70 (Right) 25 – 68 (Left)

#### 4.3. Origin of ECA with reference to the angle of the mandible

Ribeiro, R. A et al found that the distance of the CCA bifurcation from the angle of mandible was in the range of 0.5 - 4.4 cm below the angle, with an average of  $1.7 \pm 0.2$  cm.<sup>1</sup>

In the present study, the distance between the origin of ECA and the angle of the mandible was in the range of 18-30 mm on the right side and 20-32 mm on the left side.

#### 4.4. Origin of ECA with reference to cervical vertebrae

D. Anangwe, H. Saidi, and K.O. Awori studied the level of bifurcation of the common carotid artery by dissecting 80 carotid arteries of 40 cadavers. They found higher level of bifurcation in 63.8% cases. The most common levels of bifurcation were at the level of C3 vertebral body (38.8%). They said that high common carotid bifurcation is at a higher risk of impingement by intra-articular screws during procedures on cervical vertebrae. The most common low bifurcation was at C4 vertebral level in 7.5% cases. Also in 22.5% cases, the level of bifurcation was at the C3-4 intervertebral disc level and in 25% cases, terminations were higher than C3/C3-4 level. They also recorded that the external carotid artery was antero-lateral to the internal carotid artery in 30% of the cases. Further they concluded that caution must be taken by clinicians during surgical procedures in the neck because of variability in normal anatomy of ECA.<sup>3</sup>

Ribeiro, R. A et al. found that on the right side, 40% of the CCA bifurcation was at the 3<sup>rd</sup> cervical vertebral level

while in 60% cases it was at 2<sup>nd</sup> cervical vertebral level. On the left side, CCA bifurcation was at the 4<sup>th</sup> cervical vertebral level only in one case, 20% cases, bifurcation was at C3 level and in 78% cases it was at C2 level. They found the difference between origin and bifurcation levels in the same side.<sup>1</sup>

In the present study, origin of ECA at the level of C4 vertebra was found in 20 cases on the right side and 22 cases on the left side.

#### 4.5. Internal diameter of ECA at its origin

Ribeiro, R. A et al. found that the diameter of ECA on the right side was  $0.73 \pm 0.02$  and on the left side it was  $0.71 \pm 0.02$ .<sup>1</sup>

In the present study, it was found that the range of internal diameter of ECA at its origin was 4.9–15 mm on the right side and 4.5–13 mm on the left side.

#### 4.6. Internal diameter of ECA at its termination

In this study, the internal diameter of ECA was measured at its termination and it was found to be in the range of 1.9–7 mm on the right side and 1.7–7.5 mm on the left side. The mean diameter was 3.9 mm on the right side and 3.8 mm on the left side.

#### 4.7. Termination of ECA

According to Sanjeev et al., the level of termination of ECA was found to be at the neck of the mandible in 67.57% of the cases and below the level of neck of the mandible in 32.43% of the cases. The average distance of the termination of the

external carotid artery from the origin was 60 mm.<sup>2</sup>

In the present study, the distance between the origin of ECA and its termination was found to be in the range of 25–70 mm on the right side and 25–68 mm on the left side.

It was found that the distance between the origin of ECA and its termination was in the range of 25–70 mm on the right side and 25–68 mm on the left side.

However in one case on the left side, the ECA was terminating by trifurcating into maxillary artery, posterior auricular artery and transverse facial artery. In this case, the superficial temporal artery was arising from ECA proximal to the point of termination and it was found that the distance between the site of origin of ECA and the site of origin of STA was 45 mm.

## 5. Conclusion

The anatomical knowledge of relationship of External Carotid Artery with reference to adjacent anatomical landmarks is helpful for vascular surgeons to plan surgeries and prevent complications during various diagnostic and therapeutic procedures.

## 6. Source of Funding

None.

## 7. Conflicts of Interest

The authors declare no conflicts of interest.


## 8. Acknowledgement

I would like to express my special thanks of gratitude to Dr. Lakshmi Rajgopal, Ex Additional Professor, Seth G.S. Medical College, Parel, Mumbai for her valuable guidance and support.

## References

1. Ribeiro RA, Ribeiro JAS, Filho OAR, Caetano GA. Common Carotid Artery Bifurcation Levels Related to Clinical Relevant Anatomical Landmarks. *Int J Morphol*. 2006;24(3):413–6.
2. Sanjeev IK, Ashwini AH, Mahesh M, Rairam U, G. Branching Pattern Of External Carotid Artery In Human Cadavers. *Journal of Clinical and Diagnostic Research*. 2010;4:3128–3133.
3. Anangwe D, Saidi H, Ogeng'oj, Awori KO. Anatomical Variations of the Carotid Arteries in Adult Kenyans. *East African Medical Journal*. 2008;85(5):244–247.

## Author biography

**Anjalee G Ovhal**, Associate Professor  <https://orcid.org/0000-0002-9953-4760>

**K Ravikumar**, Assistant Professor

**Sachin Badge**, Associate Professor

**Cite this article:** Ovhal AG, Ravikumar K, Badge S. A cadaveric study of relationship of external carotid artery with reference to adjacent anatomical landmarks. *Indian J Clin Anat Physiol* 2021;8(4):255-259.