



Original Research Article

Comparative study of efficacy of platelet rich plasma injection versus corticosteroid injection in conservative management of periarthritis shoulder

Surai Soren¹, Ashok Kumar Nayak¹, Rabindra Nayak¹, Sambit Kumar Panda^{2,*}, Sabyasachi Swain¹

¹Dept. of Orthopaedics Surgery, M.K.C.G Medical College, Berhampur, Odisha, India

²Dept. of Orthopaedics, BB Medical College, Bolangir, Odisha, India



ARTICLE INFO

Article history:

Received 03-12-2020

Accepted 02-01-2021

Available online 25-08-2021

Keywords:

Platelet Rich Plasma Injection

Corticosteroid Injection

Efficacy

Periarthritis Shoulder

ABSTRACT

Materials and Methods: Analysis of eighty patients with periarthritis shoulder was done. Patients were thoroughly evaluated and were divided into two groups in a randomized trial. Forty patients were in group-A who received 3doses of injection of PRP (4ml) 2 weeks apart within a duration of 6weeks. Equal number of patients were in group-B. They received 2ml of Injection corticosteroid 2weeks apart within a duration of 6 weeks. All participants were advised to perform a home-based hot fomentation and 15min exercise therapy. One participant from group A and 2 from group B were lost to follow up. There were 35 male and 42 female who completed the study. Analysis of 77 subjects who completed the study was done. Participant were evaluated for range of motion of shoulder as main outcome measure. Visual Analogue Scale (VAS) and (Quick DASH) was used to measure pain and functions of the shoulder. The evaluation of Participants was done at 0,3,6 and 12 weeks. ANOVA test and Chi-square test, was repeatedly used to measure the differences.

Results: Participants who were given PRP injections showed significant improvements in active and passive range of shoulder motion as measured by VAS and Quick DASH over corticosteroid injection. This was also reflected statistically. No major adverse reactions were observed during 12 weeks of intervention.

Conclusion: In our study, the injection of PRP showed marked improvement in the range of motion of shoulder over corticosteroid injection but it needs other study to be treatment of choice. It emerged as an option for treatment in diabetes patient and condition where steroid is contraindicated.

This is an Open Access (OA) journal, and articles are distributed under the terms of the [Creative Commons Attribution-NonCommercial-ShareAlike 4.0 License](https://creativecommons.org/licenses/by-nc-sa/4.0/), which allows others to remix, tweak, and build upon the work non-commercially, as long as appropriate credit is given and the new creations are licensed under the identical terms.

For reprints contact: reprint@ipinnovative.com

1. Introduction

Periarthritis (PA) shoulder is characterised by pain, stiffness of shoulder joint.¹⁻³ It limits the movement of shoulder joint. Periarthritis shoulder affects around 2-5% of general population. It goes up to about 20% with diabetes mellitus. As our country is a diabetic capital of the world the incidence may be much higher.^{4,5} There are various methods of treatment for periarthritis like intra-articular injection of hyaluronic acid and

corticosteroid, physiotherapy which includes mobilization exercise, ultrasonic therapy, manipulation under general anaesthesia, arthroscopic release of fibrous tissue.⁶⁻⁸ The ultrasonic therapy produces in consistent results.^{9,10} Thus none of the treatment provide complete relief from periarthritis.^{11,12} The search for a better treatment is continuing. In that respect PRP is a promising treatment.^{1,4} PRP is extracted from patients own blood. It contains higher concentration of platelets above the baseline.^{13,14} Along with higher platelet concentration it has higher growth factors and anti-inflammatory agents which promotes to reduce healing time and inflammation. Thus, the time for

* Corresponding author.

E-mail address: drsambitpanda@gmail.com (S. K. Panda).

recovery from peri-arthritis is reduced. With this background we tried to examine the efficacy of PRP injection with corticosteroid injection in peri-arthritis.⁶

2. Materials and Methods

Randomised comparative study was conducted at MKCGMCH Berhampur in an OPD set up from January 2019 to December 2019. The study was approved by the institutional Ethical Committee. The present study excluded patients with local abscesses, diabetes mellitus, malignancy, pregnancy, and blood disorders (coagulopathy and thrombocytopenia); patients on NSAIDs or systemic steroids within one week before injection; those who received previous local injection of steroid within past 3 weeks or previous injection of PRP within past 6 months; and patients with painful active, cervical spine conditions. All patients were subjected to history taking, demographic data recording and clinical examination which includes general examination and local examination of shoulder joint.

All patients underwent blood examination which includes complete blood count, fasting blood sugar, erythrocyte sedimentation rate, serum uric acid, rheumatoid factor, C-reactive protein, hepatitis A, B and C virus antibody, tridot test and also radiological examination such as plain radiography shoulder joint, where two projections were formed: antero-posterior view with the patient standing, the arm in the hanging position first with maximal external and then with maximal internal rotation of the shoulder.

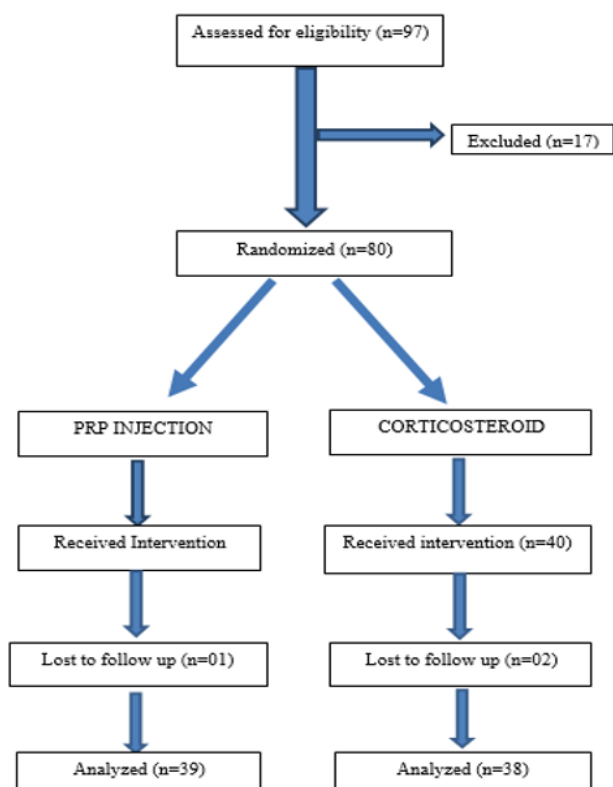
2.1. Inclusion criteria

1. Age over 25 years
2. Shoulder pain for at more than one month with loss of active shoulder movements (flexion, abduction and external rotation).^{15,16}
3. Antero-posterior radiographs of the shoulder joint in neutral rotation should be normal.
4. Willingness to be part of the study and refuse other modality of treatment.

2.2. Exclusion criteria

1. Unwillingness to participate in the study
2. Intrinsic shoulder joint pathology
3. Any history of shoulder trauma/surgery
4. Presence of complex regional pain syndrome
5. History of intra-articular injection in the involved shoulder joint in last six months
6. Patients with haematological disorders
7. Patients with chronic diseases and pregnancy or breastfeeding.

Eighty participants fulfilled the inclusion/exclusion criteria. They were divided into two groups A and B equally. This was done in a randomized manner. The participants were provided with all the information regarding the study. They were apprised with withdrawal rights. After thorough counselling, informed consent was taken. Group A participants received 3 doses of intra-articular injection (4ml of PRP). Group B participants received 2ml of methyl prednisolone acetate by posterior approach. The sulcus between the head of the humerus and acromion was identified. The needle was inserted 2-3cm inferior and medial to the postero-lateral corner of the acromion and directed anteriorly towards the coracoid process.^{17,18} Throughout the whole procedure aseptic measures and precautions were taken. After the injection patient were observed for any adverse reactions. Then they are sent to home. They were instructed to limit shoulder movement for 48 hours and to use cold compression and paracetamol in case of unbearable pain. After a week exercise was started. PRP was prepared by taking 10ml of venous blood from every patient. Blood was collected in a sterile tube. The sterility of the tubes was verified by culture in the department of microbiology. The sterile tubes were filled with sodium citrate to prevent coagulation. The sterile tube with citrated blood was centrifuged at 3500 rpm for 10 minutes to separate the blood component. Then 4ml of PRP was taken out. All the participants of group A and B were taught shoulder exercise which included active range of shoulder movement like abduction, flexion, external rotation and internal rotation. Pendulum exercise was also taught. All the participants were instructed to perform the exercise twice daily at home. They were advised to perform the exercises in gentle manner. Ointment or pain-relieving oil can be used by the participants in case of increased pain. After baseline evaluation and intervention all the participants were assessed at 3, 6 and 12 weeks. The assessment was done by physiatrist. Physiatrist was unaware of the intervention received by participants. The participant had been instructed not to reveal about the treatment. Improvement in active and passive range of motion of shoulder was assessed by goniometer. The data generated were expressed as standard deviation and mean. The change in the mean values of continuous variables with time was compared by using ANOVA test. One-way ANOVA test was applied to compare mean values between groups for each domain of continuous variable.¹⁹ To determine difference between the groups post-hoc tests (Bonferroni correction) was used. Result of p value > 0.05 was considered to be significant.



3. Observation & Results

A total of 97 subjects with complaints of shoulder pain associated with restriction of motion were assessed for eligibility. A total of 80 subjects were found eligible and randomised to two groups of 40 each. 3 participants (1 in Group A; 2 in Group B) were lost to follow up. Analysis of 77 subjects (35 males; 42 females) who completed the study was done.

Data of age, sex, involvement of dominant or non-dominant side and other clinical features of each group are given in [Table 1 (a), (b), (c) and (d)]. The data given is a Baseline feature. Mean of age, sex distribution, duration of symptom, range of motion of shoulder, involvement of shoulder was almost the same in both the group. 1 participant in PRP group reported pain and pricking sensation which was relieved by ice compression. No major side effects were observed during period of study.

Age group involved in both the group was between 29-75yrs. No significant difference was observed in age group. Similarly, the sex distribution was almost the same in both the groups. There was predominance of dominant side as compared to non-dominant side in both the group. Duration of symptoms was almost the same in both the group. At follow up, after the initial intervention there was improvement in active range of shoulder movement. Abduction, flexion, internal rotation, external rotation in both the group. At 12 week of assessment PRP treatment

showed marked improvement in mean active range of shoulder movement abduction, flexion, external rotation and internal rotation over steroid injection. There was improvement with steroid injection at 12 weeks in mean active range shoulder movement but the improvement was far more less than PRP treatment [Table 3]. Analysis of passive range of shoulder motion showed improvements similar to active motion, with significant improvement seen at 12 weeks [Table 4].

Active range of motion in shoulder in degrees [mean] in baseline, 3 week, 6 weeks, 12 weeks in Table 3.

{Statistical test: Anova with bonferroni correction between groups and repeat anova within group}.

Passive range of motion of shoulder in degree in baseline, 3 week, 6 weeks, 12 weeks in Table 4.

[Statistical test: Anova with bonferroni correction between groups and repeat anova with in group]

At 6weeks, more significant improvement was seen only in PRP as shown by Post-hoc test with Bonferroni correction.

4. Discussion

Age of participants was in range of 29-75yrs with mean of 53.5 ± 12.5 years. This is in line with the data reported in literature.¹² Female are more affected than male in periarthritis. And our study is similar to the other studies.²⁰ In this study the dominant side was affected more than non-dominant side contrary to the other studies,¹² Which shows non-dominant side to be involved more. Treatment with PRP resulted in better VAS score for pain and quick DASH score for function after 6weeks. Treatment with PRP resulted in marked improvement in pain, active and passive range of motion of shoulder after 12 weeks. This was also reflected statistically. Treatment with steroid injection also showed improvement in pain and functional movement of shoulder but it was not up to the level of PRP. The improvement was in line with that of other previous studies.^{11,14,19} Systematic review of steroid use in PA by Griesser MJ et al. showed significant but transient improvement in abduction and forward elevation and significant short as well as long term diminution of pain measured by VAS and Shoulder Pain and Disability Index (SPADI).⁶ In our study it was found that PRP was better than steroid. There is increasing evidence to support the use of PRP in PA.

Advantage- Randomization of the participant to eliminate the selection bias was done in our study. Assessment by a blinded investigator to minimize the bias was incorporated in the study. Use of goniometer to measure the range of motion of shoulder.⁵ Simple method of preparation of PRP.

Drawbacks- Duration of the study was only 1 year and the intervention was only for 12 weeks. Since the duration of periarthritis shoulder is between 1-2 years. There is the need for a longer study beyond 12weeks and similar trend

Table 1: (a)

	PRP mean (SD) (N=39)	Corticosteroid mean (SD) (N=38)
Sex, no. (%)		
Male	22 (56.4)	18(47.4)
Female	17 (43.6)	20 (52.6)
(b)		
	PRP mean (SD) (N=39)	Corticosteroid mean (SD) (N=38)
Age (years)		
Mean	52.5(12.8)	54(12.2)
Range	(29-75)	(30-72)
(c)		
Side involved, N(%)	PRP (39)	Corticosteroid (38)
Dominant	22(56.4)	20(52.6)
Non-dominant	17(43.5)	18(47.3)
(d)		
	PRP (N=39)	Corticosteroid (N=38)
Duration of symptoms, in months		
Mean	4.4	5.1

Table 2: Patient demographic and baseline features

Range of motion (in shoulder)		PRP (N=39)		Corticosteroid (N=38)	
		Mean	Standard Deviation	Mean	Standard Deviation
Abduction	Active	105.8397	10.37876	97.0592	11.37512
	Passive	115.2051	9.78635	106.8158	10.49673
Flexion	Active	107.0385	15.18163	93.6974	14.78028
	Passive	115.2244	12.14439	103.5526	13.58148
External rotation	Active	53.4615	8.54488	40.7566	7.14651
	Passive	61.2564	8.41785	49.6250	7.06456
Internal rotation	Active	43.5192	5.69579	34.7171	4.42283
	Passive	49.8269	5.56426	43.1908	4.29937

Statistical test: [-chi-square test for sex & involved side was done. ANOVA with bonferroni test for duration of symptom and range of motion of shoulder-]

Table 3:

		PRP mean (SD) (N=39)	Corticosteroid mean (SD) (N=38)	P- value
Abduction	Baseline	82(8.3)	80.5(11.2)	0.11
	3 weeks	96.1(9.8)	90.4(11.4)	0.48
	6 weeks	112.5(12.6)	102.1(12.0)	0.12
	12 weeks	132.6(12.6)	115.0(11.7)	0.023
Flexion	Baseline	84.6(13.4)	76.9(16.5)	0.18
	3 weeks	98.9(14.8)	87.3(14.9)	0.07
	6 weeks	114.4(16.6)	99.2(14.6)	0.24
	12 weeks	132(14.0)	115(11.7)	0.023
External rotation	Baseline	32.4(6.1)	27.5(5.8)	0.039
	3 weeks	45.3(7.8)	35.0(6.6)	0.005
	6 weeks	59.6(9.1)	45.4(8.6)	0.036
	12 weeks	76.7(13.4)	55.5(9.0)	0.036
Internal rotation	Baseline	25.6(3.7)	21.6(3.2)	0.041
	3 weeks	37.2(5.4)	29.0(3.8)	0.0
	6 weeks	49.3(6.8)	38.8(5.1)	0.002
	12 weeks	60.6(6.5)	49.0(6.3)	0.001

Table 4:

		PRP mean (SD) (N=39)	Corticosteroid mean(SD) (N=38)	P-value
Abduction	Baseline	88.6(8.1)	86.7(10.8)	0.25
	3 weeks	105.0(9.5)	99.7(11.5)	0.38
	6 weeks	148.9(16.0)	113.8(10.6)	0.021
	12 weeks	153.0(12.0)	126.8(10.1)	0.003
Flexion	Baseline	90.5(11.2)	83.5(14.6)	0.04
	3 weeks	106.7(12.0)	96.6(14.5)	0.14
	6 weeks	123.5(14.1)	110.8(13.8)	0.094
External rotation	12 weeks	140.5(13.9)	123.3(12.3)	0.045
	Baseline	38.0(6.2)	33.3(5.9)	0.16
	3 weeks	52.5(6.7)	44.0(7.3)	0.018
Internal rotation	6 weeks	66.8(7.6)	55.0(8.3)	0.004
	12 weeks	85.3(11.0)	65.5(7.9)	0.001
	Baseline	30.4(6.0)	27.4(3.2)	0.008
Internal rotation	3 weeks	43.1(5.9)	37.0(4.0)	0.08
	6 weeks	57.2(6.2)	49.0(5.7)	0.003
	12 weeks	69.2(7.2)	59.4(5.7)	0.008

has been reported in literature.¹²

5. Conclusion

In our study, the injection of PRP showed marked improvement in the range of motion of shoulder over corticosteroid injection but it needs other study to be treatment of choice. It emerged as an option for treatment in diabetes patient and condition where steroid is contraindicated.

6. Conflict of Interest

The authors declare that there are no conflicts of interest in this paper.

7. Source of Funding

None.

References

- Hsu WK, Mishra A, Rodeo SR, Fu F, Terry MA, Randelli P, et al. Platelet-rich plasma in orthopaedic applications: evidence-based recommendations for treatment. *J Am Acad Orthop Surg.* 2013;21(12):739–48.
- Hand GCR, Athanasou NA, Matthews T, Carr AJ. The pathology of frozen shoulder. *J Bone Joint Surg Br.* 2007;89(7):928–32.
- Zuckerman JD, Rokito A. Frozen shoulder: a consensus definition. *J Shoulder Elbow Surg.* 2011;20(2):322–25.
- Harmon KG, Rao AL. The use of platelet-rich plasma in the nonsurgical management of sports injuries: hype or hope? *Haematology Am Soc Haematol Educ Program.* 2013;2013:620–6. doi:10.1182/asheducation-2013.1.620.
- Pal B, Anderson J, Dick WC, Griffiths ID. Limitation of joint mobility and shoulder capsulitis in insulin- and non-insulin-dependent diabetes mellitus. *Br J Rheumatol.* 1986;25(2):147–51.
- Griesser MJ, Harris JD, Campbell JE, Jones GL. Adhesive capsulitis of the shoulder: a systematic review of the effectiveness of intra-articular corticosteroid injections. *J Bone Joint Surg Am.* 2011;93(18):1727–33.
- Jacobs LG, Smith MG, Khan SA, Smith K, Joshi M. Manipulation or intra-articular steroids in the management of adhesive capsulitis of the shoulder? A prospective randomized trial. *J Shoulder Elbow Surg.* 2009;18(3):348–53.
- Carette S, Moffet H, Tardif J, Bessette L, Morin F, Frémont P, et al. Intraarticular corticosteroids, supervised physiotherapy, or a combination of the two in the treatment of adhesive capsulitis of the shoulder: a placebo-controlled trial. *Arthritis Rheum.* 2003;48(3):829–38.
- Chauhan S, Kothari SY, Laisram N. Comparison of ultrasonic therapy, sodium hyaluronate injection and steroid injection in the treatment of periarthritis shoulder. *IJPMR.* 2012;23(3):105–10.
- Dogru H, Basaran S, Sarpel T. Effectiveness of therapeutic ultrasound in adhesive capsulitis. *Joint Bone Spine.* 2008;75(4):445–50.
- Lloyd-Roberts GC, French PR. Periarthritis of the shoulder: a study of the disease and its treatment. *Br Med J.* 1959;1(5137):1569–71.
- Neviaser AS, Neviaser RJ. Adhesive capsulitis of the shoulder. *J Am Acad Orthop Surg.* 2011;19(9):536–42.
- Blanchard V, Barr S, Cerisola FL. The effectiveness of corticosteroid injections compared with physiotherapeutic interventions for adhesive capsulitis: a systematic review. *Physiotherapy.* 2010;96(2):95–107.
- Eppley BL, Woodell JE, Higgins J. Platelet quantification and growth factor analysis from platelet-rich plasma: implications for wound healing. *Plast Reconstr Surg.* 2004;114(6):1502–8.
- Mcfarland EG. Examination of the shoulder: the complete guide. New York: Thieme; 2006.
- Schellinghout JM, Verhagen AP, Thomas S, Koes BW. Lack of uniformity in diagnostic labeling of shoulder pain: time for a different approach. *Man Ther.* 2008;13(6):478–83.
- Rizk TE, Pinals RS, Talaiver AS. Corticosteroid injections in adhesive capsulitis: investigation of their value and site. *Arch Phys Med Rehabil.* 1991;72(1):20–2.
- Page MJ, Green S, Kramer S, Johnston RV, McBain B, Buchbinder R, et al. Electrotherapy modalities for adhesive capsulitis (frozen shoulder) Cochrane. *Database Syst Rev.* 2014;(10):11324.
- Kennedy CA, Beaton DE, Smith P, Eerd DV, Tang K, Inrig T, et al. Measurement properties of the QuickDASH (disabilities of the arm, shoulder and hand) outcome measure and cross-cultural adaptations of the QuickDASH: a systematic review. *Qual Life Res.* 2013;22(9):2509–47.
- Dias R, Cutts S, Massoud S. Frozen shoulder. *BMJ.* 2005;331(7530):1453–6.

Author biography

Surai Soren, Assistant Professor

Ashok Kumar Nayak, Associate Professor

Rabindra Nayak, Assistant Professor

Sambit Kumar Panda, Associate Professor

Sabyasachi Swain, Senior Resident

Cite this article: Soren S, Nayak AK, Nayak R, Panda SK, Swain S. Comparative study of efficacy of platelet rich plasma injection versus corticosteroid injection in conservative management of periarthritis shoulder. *Panacea J Med Sci* 2021;11(2):274-279.