



Original Research Article

Evaluation of results of fracture head and neck of radius managed by various methods

Surai Soren¹, Ashok Kumar Nayak¹, Rabindra Kumar Nayak¹, Sambit Kumar Panda^{2,*}, Pravash Ranjan Parida³

¹Dept. of Orthopaedics, MKCG Medical College, Berhampur, Odisha, India

²Dept. of Orthopaedics, BB Medical College, Bolangir, Odisha, India

³Dept. of Orthopaedics, SCB Medical College, Cuttack, Odisha, India



ARTICLE INFO

Article history:

Received 03-12-2020

Accepted 11-12-2020

Available online 25-08-2021

Keywords:

Radial Head Arthroplasty

Herbert's screw

Radial head excision

ABSTRACT

Background: Radial head fractures are the most frequent fracture type reported around the elbow. Fractures have been documented to occur in isolation or with other associated osseous and soft tissue injuries. However, despite intensive research into these injuries, controversies still exist regarding the role of further imaging modalities, the use of non-operative management, as well as the indication and technique for operative intervention.

Aims and Objective: To analyse the clinical and functional outcome of patients with head and neck fracture of radius managed by conservative method, open reduction and internal fixation, radial head prosthesis and radial head excision.

Materials and Methods: This study "evaluation of results of fracture head and neck of radius managed by various methods" was carried out in M.K.C.G Medical College, Berhampur from September 2017 to October 2019. Eighty patients of radial head and neck fractures were treated and hereby included in our study. We collected records of the patients by asking the patients history and examining the patients. Essential investigations of all the patients were done. The primary outcome measures were the surgeon reported Mayo Elbow Score (MES) and the patient reported Short Musculoskeletal Function Assessment (SMFA).

Conclusion: Current evidence supports open reduction and internal fixation of simple Mason type II fractures. For Mason type III fractures, controversy still exists regarding the optimal treatment. Studies currently show good to excellent results with radial head replacement in the majority of patients with Mason type III fractures with three or more fracture fragments.

This is an Open Access (OA) journal, and articles are distributed under the terms of the [Creative Commons Attribution-NonCommercial-ShareAlike 4.0 License](https://creativecommons.org/licenses/by-nc-sa/4.0/), which allows others to remix, tweak, and build upon the work non-commercially, as long as appropriate credit is given and the new creations are licensed under the identical terms.

For reprints contact: reprint@ipinnovative.com

1. Introduction

Radial head fractures are the most frequent fracture type reported around the elbow.^{1,2} Fractures have been documented to occur in isolation or with other associated osseous and soft tissue injuries.³⁻⁶ With awareness for the potential patterns of injury essential in determining the appropriate management to attain restoration of

elbow function.⁷ Diagnosis is routinely made with plain radiographs, although the use of further imaging modalities such as CT is increasing with an aim to better understand the injury patterns that occur.^{2,8} The Mason classification is the most commonly used system for classifying these injuries throughout the literature.^{9,10} Management includes non operative treatment for isolated stable radial head fractures (Mason 1 and type 2), with a variety of operative techniques used for the unstable fracture patterns (Manson

* Corresponding author.

E-mail address: drsambitpanda@gmail.com (S. K. Panda).

type 3 and type 4). Recently there has been an increased appreciation for the role of the radial head in elbow stability, the benefits and limitations of the fracture classification systems available, as well as the clinical relevance of associated injuries.^{1,3} However, despite intensive research into these injuries, controversies still exist regarding the role of further imaging modalities, the use of non-operative management, as well as the indication and technique for operative intervention.¹¹ There is a lack of prospective short and long term patient reported outcome data for the simple isolated radial head and neck fractures, which clearly defines the indication and outcome following the management of these injuries.

2. Aims and Objective

To analyse the clinical and functional outcome of patients with head and neck fracture of radius managed by conservative method, open reduction and internal fixation, radial head prosthesis and radial head excision and to analyse the early and late complication following different modalities of treatment in radial head and neck fracture

3. Observation and Result

The study consists of 80 cases of radial head and neck fracture out of which 62 were radial head fracture and 18 were radial neck fracture. They were treated by various methods in MKCG Medical College, from September 2017 to October 2019. The following observation were made in the study.

1. Age incidence: Age variation in the series were from 5 to 80 years Radial head and neck fractures were found to have high incidence in 40 to 60 years of age group.
2. Sex incidence: From 80 cases there were 42 females and 38 males i.e. 53% females and 47% males. Male and female ratio in incidence were nearly equal.
3. Side of fracture: Right side was involved in 46 patients and left in 34 patients none had the sides involved in the same patient.
4. Mode of injury: Most of the injuries were caused by simple fall, while other causes are fall from height, direct blow, sports and motor vehicle accident.
5. Types of fracture

Types of fractures	No. of patients	Percentage
Mason type 1	25	31.25
Type 2	15	18.75
Type 3	16	20
Type 4	6	7.5
Radial neck fracture angulation <30	6	7.5
Angulation >30	12	15

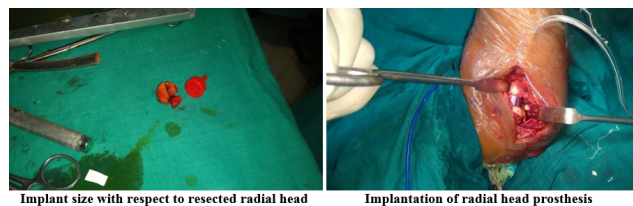


Fig. 1: Radial head arthroplasty in mason type 3 radial head fracture

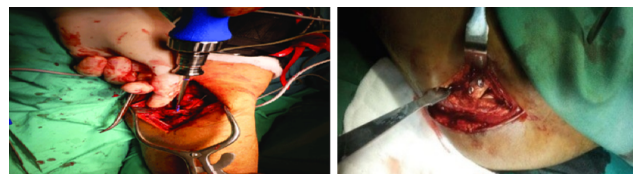


Fig. 2: Open reduction and internal fixation of radial head fracture by screw

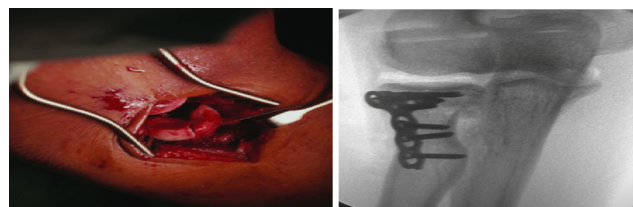


Fig. 3: Open reduction and internal fixation of radial head fracture by plate

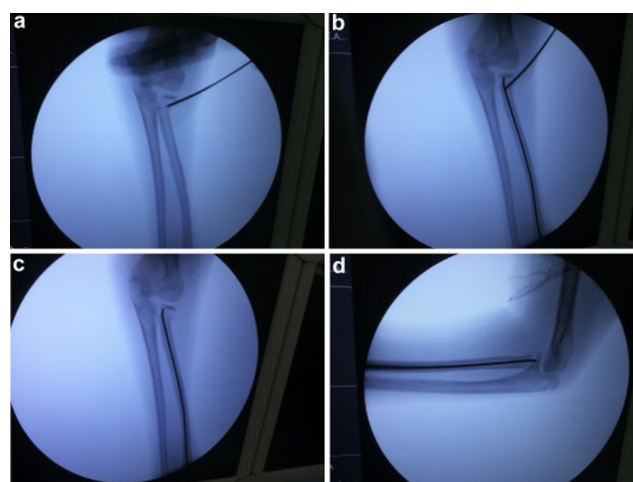


Fig. 4: Close reduction and internal fixation of radial neck under fluoroscopy.

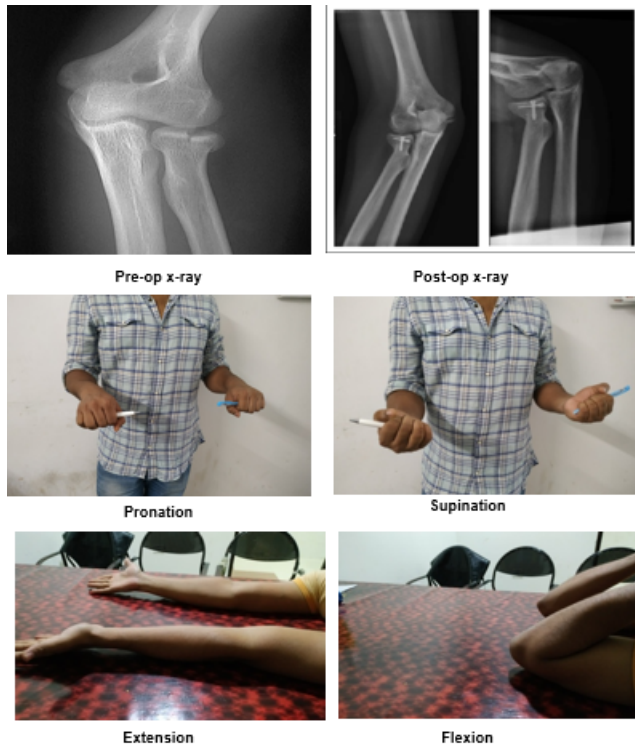


Fig. 5: Follow up case of mason type 2 radial head fracture managed by open reduction and internal fixation by screw at 6 month.

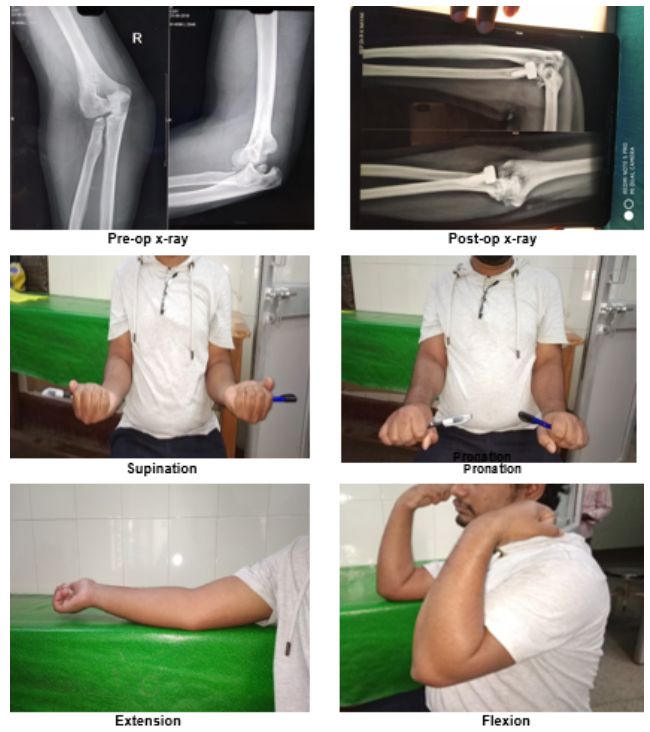

Fig. 7: Follow up case of mason type 4 radial head fracture treated by radial head arthroplasty at 6 months.

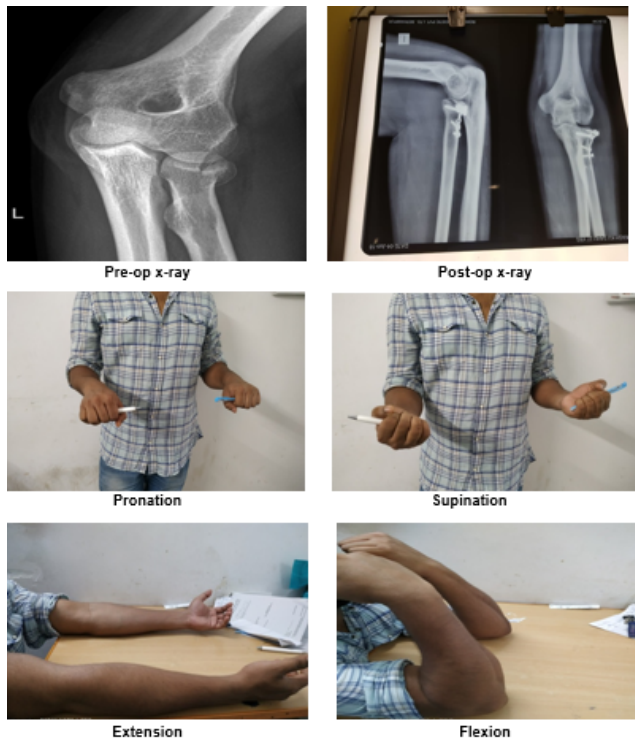

Fig. 6: Follow up case of mason type 2 radial head fracture treated by open reduction and internal fixation by plate at 6 months.

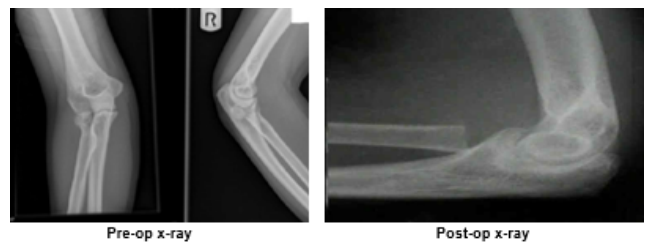


Fig. 8: Follow up case of mason type 3 radial head fracture treated by radial head excision at 1 year.

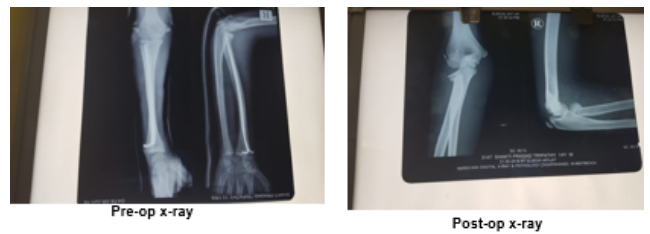

Fig. 9: Follow up case of radial neck fracture treated by close reduction and internal fixation by k-wire at 3 months

4. Discussion

The incidence of radial head and neck fracture has increased in last few years due to change in life style and increase road traffic accidents. The best management in these fractures is still uncertain. The present study was conducted to assess the results of radial head and neck fracture treated by various methods like conservative method, screw fixation, plate fixation, radial head excision, radial head arthroplasty and k-wire fixation for radial neck fracture.

The radial head and neck fractures occur more commonly in middle age group. Numerous age related studies point towards this and our study is consistent with this finding. In our study majority of the patients i.e. 37 patients (46%) were from age group of 40 to 60 years. Average age of the patient was 44.25 years.

Our study showed incidence of radial head and neck in male and female are nearly equal. In our study fracture occurred on right side in 46 patients and on left side in 34 patients. It is probably because most patients in our study group were right handed persons.

On the basis of mayo elbow performance score most mason type 1 fracture had excellent results, mason type 2 fractures had mostly good results and 2 had poor results due to non-union which were managed conservatively. All mason type 1 fractures united by conservative methods. All mason type 2 fractures (6) showed excellent and good results which were managed by open reduction and fixation with screw. All mason type 2 fractures (6) and all radial neck fractures (6) showed excellent to good results which were fixed by plate. Out of 4 mason type 3 fractures which were fixed by plate 1 showed poor result and 1 showed fair result. This is probably because of non union in 2 patients of mason type 3 fracture having more than 3 parts fracture. In mason type 3 fracture all pts (6) showed excellent to good results which were treated by radial head arthroplasty. All mason type 4 fractures (3) showed excellent to good result which were treated by radial head arthroplasty. Among radial head excision groups (9), 5 pts showed excellent to good results and 3 had fair to poor results. All paediatrics radial neck fractures (3) having >30 deg angulation were treated by k-wire fixation and showed excellent to good results and similarly all adult radial neck fractures (3) which were fixed by k-wire also showed excellent to good results. Radial head and neck fractures which were managed conservatively showed a mean flexion arc of 141 deg, mean rotation arc of 170 deg and a mean MEPS of 93. Similarly ones which fixed with screws showed mean flexion arc of 141 deg, mean rotation arc of 172 deg and a mean MEPS of 95. Those fractures which were fixed with plate showed mean flexion arc of 142 deg, mean rotation arc of 165 deg and a mean MEPS of 90. Radial head excision showed a mean flexion arc of 120 deg, mean rotation arc of 150 deg and a mean MEPS of 83. Radial head arthroplasty showed a mean flexion arc of 148 deg, mean rotation arc of 176 deg and a

mean MEPS of 94. Those fractures which are fixed with k-wires showed a mean flexion arc of 145 deg, mean rotation arc of 175 deg and a mean MEPS of 94.

Excision of the radial head has also been used for Mason type II fracture management.^{12,13} Zarattini et al. Retrospectively reviewed 59 patients with Mason type II fractures. Twenty-four patients were treated with radial head excision and 35 were treated with open reduction and internal fixation. At average follow-up of 157 months and 125 months, respectively, patients treated with open reduction and internal fixation had less residual pain, greater range of motion, and better strength than patients treated with radial head excision. Additionally, patients treated with fixation had a lower incidence of severe posttraumatic arthritis.

5. Conclusion

Radial head injuries range from minimally displaced to comminuted displaced fractures with elbow instability (Mason types I and through IV). Appropriate management of radial head injury is important in restoring the normal mechanics and anatomy of the elbow joint.^{14,15} Associated bony and ligamentous injury must be addressed at the same time. Mason type I fracture can be treated conservatively.⁹ The optimal (Surgical) treatment for mason type II and III fractures is still uncertain. With ORIF is a viable option. We prefer this method when it can be technically easily accomplished.^{16–18} Radial head arthroplasty is needed for more complex injuries, and the surgeon should always have implants available in the operating room when managing these injuries.^{10,19,20} However, the preferential use of either ORIF or replacement continues to cause much debate and controversy. Headless screw fixation technique provides a minimal invasive surgical option with less dissection and soft tissue stripping, thus reducing the risk of injury to the associated ligaments and nerves. While there is a trend that this technique gives better functional outcome in simple fracture, it provides good functional outcome in simple fracture advocating use as an alternative to plate fixation. Current evidence supports open reduction and internal fixation of simple Mason type II fractures. For Mason type III fractures, controversy still exists regarding the optimal treatment. Studies currently show good to excellent results with radial head replacement in the majority of patients with Mason type III fractures with three or more fracture fragments. Clinical outcomes for elbow joint stability, grip strength, pain frequency, and range of extension and supination motions were in favour of ORIF, compared with radial head excision, which is also associated with more complications.^{21,22} Radial neck fracture with angulation <30 deg can be managed conservatively and angle > 30 deg managed with open reduction and internal fixation with plate especially in adults. In case paediatric age group it can be managed with pinning. K-wire can be used in adult

fracture neck of radius.^{23,24}

6. Conflict of Interest

The authors declare that there are no conflicts of interest in this paper.

7. Source of Funding

None.

References

- Akesson T, Herbertsson P, Josefsson PO. Primary nonoperative treatment of moderately displaced two-part fractures of the radial head. *J Bone Joint Surg Am.* 2006;88(9):1909–14. doi:10.2106/JBJS.E.01052.
- Guitton TG, Ring D. Interobserver reliability of radial head fracture classification: two-dimensional compared with three-dimensional CT. *J Bone Joint Surg Am.* 2011;93(21):2015–21. doi:10.2106/JBJS.J.00711.
- Beingessner DM, Dunning CE, Gordon KD. The effect of radial head fracture size on elbow kinematics and stability. *J Orthop Res.* 2005;23(1):210–7. doi:10.1016/j.orthres.2004.06.001.
- M B. The elbow and its disorders. M B, editor. Saunders, Philadelphia; 1985. p. 355–355.
- Kaplan EB. The etiology and treatment of epicondylitis. *Bull Hosp Joint Dis.* 1968;29(1):77–83.
- Rineer CA, Guitton TG, Ring D. Radial head fractures: loss of cortical contact is associated with concomitant fracture or dislocation. *J Shoulder Elbow Surg.* 2010;19(1):21–5. doi:10.1016/j.jse.2009.05.015.
- Halls AA, Travill A. Transmission of pressures across the elbow joint. *Anat Rec.* 1964;150:243–7. doi:10.1002/ar.1091500305.
- Itamura JM, Roidis NT, Chong AK. Computed tomography study of radial head morphology. *J Shoulder Elbow Surg.* 2008;17(2):347–54. doi:10.1016/j.jse.2007.07.019.
- Herbertsson P, Josefsson PO, Hasselius R. Uncomplicated Mason type-II and III fractures of the radial head and neck in adults. A long-term follow-up study. *J Bone Joint Surg Am.* 2004;86(3):569–74. doi:10.2106/00004623-200403000-00016.
- Li N, Chen S. Open reduction and internal-fixation versus radial head replacement in treatment of Mason type III radial head fractures. *Eur J Orthop Surg Traumatol.* 2014;24(6):851–5. doi:10.1007/s00590-013-1367-y.
- Rosenblatt Y, Athwal GS, Faber KJ. Current recommendations for the treatment of radial head fractures. *Orthop Clin North Am.* 2008;39(2):173–85. doi:10.1016/j.ocl.2007.12.008.
- Hotchkiss RN. Displaced fractures of the radial head: internal fixation or excision? *J Am Acad Orthop Surg.* 1997;5(1):1–10. doi:10.5435/00124635-199701000-00001.
- Ikeda M, Sugiyama K, Kang C. Comminuted fractures of the radial head. Comparison of resection and internal fixation. *J Bone Joint Surg Am.* 2005;87(1):76–84. doi:10.2106/JBJS.C.01323.
- Cheung EV, Steinmann SP. Surgical approaches to the elbow. *J Am Acad Orthop Surg.* 2009;17(5):325–33.
- Schimizzi A, MacLennan A, Meier KM, Chia B, Catalano LW, Glickel SZ, et al. Defining a safe zone of dissection during the extensor digitorum communis splitting approach to the proximal radius and forearm: an anatomic study. *J Hand Surg Am.* 2009;34(7):1252–5. doi:10.1016/j.jhssa.2009.04.026.
- Iacobellis C, Visentin A, Aldegheri R. Open reduction and internal fixation of radial head fractures. *Musculoskeletal Surg.* 2012;96(1):81–6.
- Ikeda M, Yamashina Y, Kamimoto M. Open reduction and internal fixation of comminuted fractures of the radial head using lowprofile mini-plates. *J Bone Joint Surg Br.* 2003;85(7):1040–4. doi:10.1302/0301-620x.85b7.13823.
- Lindhovius AL, Felsch Q, Ring D. The long-term outcome of open reduction and internal fixation of stable displaced isolated partial articular fractures of the radial head. *J Trauma.* 2009;67(1):143–6. doi:10.1097/TA.0b013e31818234d6.
- Chen X, Wang SC, Cao LH, Yang GQ, Li M, Su JC, et al. Comparison between radial head replacement and open reduction and internal fixation in clinical treatment of unstable, multi-fragmented radial head fractures. *Int Orthop.* 2011;35(7):1071–6.
- Ruan HJ, Fan CY, Liu JJ. A comparative study of internal fixation and prosthesis replacement for radial head fractures of Mason type III. *Int Orthop.* 2009;33(1):249–53. doi:10.1007/s00264-007-0453-3.
- Iftimie PP, Garcia JC, Forcada ILG, Pedrouzo JEG, Gomà JG. Resection arthroplasty for radial head fractures: long-term follow-up. *J Shoulder Elbow Surg.* 2011;20(1):45–50. doi:10.1016/j.jse.2010.09.005.
- Lindhovius AL, Felsch Q, Doornberg JN. Open reduction and internal fixation compared with excision for unstable displaced fractures of the radial head. *J Hand Surg.* 2007;32(5):630–6.
- Harrington IJ, Sekyi-Otu A, Barrington TW. The functional outcome with metallic radial head implants in the treatment of unstable elbow fractures: a long-term review. *J Trauma.* 2001;50(1):46–52.
- Johnston GW. A follow-up of one hundred cases of fracture of the head of the radius with a review of the literature. *Ulster Med J.* 1962;31(1):51–6.

Author biography

Surai Soren, Assistant Professor

Ashok Kumar Nayak, Associate Professor

Rabindra Kumar Nayak, Assistant Professor

Sambit Kumar Panda, Associate Professor

Pravash Ranjan Parida, Senior Resident

Cite this article: Soren S, Nayak AK, Nayak RK, Panda SK, Parida PR. Evaluation of results of fracture head and neck of radius managed by various methods. *Panacea J Med Sci* 2021;11(2):269–273.