

Content available at: <https://www.ipinnovative.com/open-access-journals>

Indian Journal of Obstetrics and Gynecology Research

Journal homepage: [www.ijogr.org](http://www.ijogr.org)

## Case Report

# Syphilis in pregnancy: The menace continues to haunt

Manisha Jhirwal<sup>1,\*</sup>, Charu Sharma<sup>1</sup>, Shashank Shekhar<sup>1</sup>, Apoorva Tak<sup>1</sup>, Poonam Elhance<sup>2</sup>

<sup>1</sup>Dept. of Obstetrics & Gynecology, All India Institute of Medical Sciences, Jodhpur, Rajasthan, India

<sup>2</sup>Dept. of Pathology, All India Institute of Medical Sciences(AIIMS), Jodhpur, Rajasthan, India



### ARTICLE INFO

#### Article history:

Received 18-03-2021

Accepted 30-04-2021

Available online 25-08-2021

#### Keywords:

Congenital syphilis

Syphilis

Penicillin

### ABSTRACT

Syphilis in pregnancy remains an important medical condition due to its adverse perinatal consequences and potential to cause congenital syphilis. The cases of congenital syphilis have been reported worldwide as there is increase in cases of syphilis in women. We hereby present a case of 34-year-old multigravida who was diagnosed with syphilis during her first antenatal visit in second trimester and managed. The baby did not show any signs of congenital syphilis. This report highlights the diagnostic workup, management and possible complications of syphilis in pregnancy.

**Key Messages:** Universal screening of all pregnant women at first antenatal visit with a non-treponemal test should be used for screening for syphilis in pregnancy.

This is an Open Access (OA) journal, and articles are distributed under the terms of the [Creative Commons Attribution-NonCommercial-ShareAlike 4.0 License](https://creativecommons.org/licenses/by-nc-sa/4.0/), which allows others to remix, tweak, and build upon the work non-commercially, as long as appropriate credit is given and the new creations are licensed under the identical terms.

For reprints contact: [reprint@ipinnovative.com](mailto:reprint@ipinnovative.com)

## 1. Introduction

Syphilis is a sexually transmitted infection (STI) caused by the spirochete *Treponema pallidum* which is of particular concern during pregnancy because of the risk of transplacental infection to the fetus.<sup>1</sup> Stillbirths and childhood mortality due to syphilis are continuously being reported each year.

The national HIV program data reveals that the prevalence of syphilis among pregnant women attending antenatal care was 0.23% in 2014–2015 which was increased slightly to 0.16% in 2016–2017.<sup>2</sup> However, In India there is lack of reporting and stigma attached to sexually transmitted diseases.

Globally the estimated total number of congenital syphilis (CS) cases per 100,000 live births fell from 539 in 2012 to 473 in 2016.<sup>3</sup> Fetus can be affected from as early as 8–10 weeks of gestation and affection increases

with gestation.<sup>4</sup> Once the fetus is infected wide spread dissemination occurs and any organ system can be infected. Presentation is varied from abortion to still birth to low birth weight baby and depends upon the stage of syphilis, gestational age, maternal treatment and immunological response of fetus. Rate of transmission is higher for primary, secondary and early latent syphilis with transmission rate as high as 80–100%.<sup>5</sup> Routine antenatal screening, timely diagnosis and proper management of the infection in the pregnant women are important in order to prevent adverse outcome. The Menace of syphilis continues to haunt! Here we are presenting a case of secondary syphilis in pregnancy.

## 2. Case History

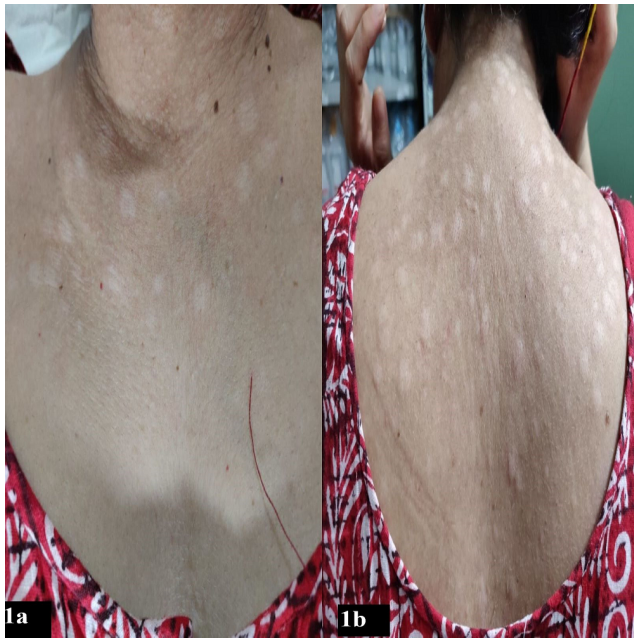A 34-year-old pregnant female, G<sub>2</sub>P<sub>1001</sub>, reported at 24 weeks gestation. During her workup, the venereal disease research laboratory test (VDRL) was found to be reactive, rapid plasma regain (RPR) titre was 1:32 and *Treponema pallidum* haemagglutination (TPHA) titre was 1:2500. She

\* Corresponding author.

E-mail address: [jhirwalm@aiimsjodhpur.edu.in](mailto:jhirwalm@aiimsjodhpur.edu.in) (M. Jhirwal).

had history of rashes around her mouth and all over the body one year back and ulcers in the mouth three months before conception but she did not take any treatment.

Second trimester ultrasonography (USG) reported no gross congenital anomalies in fetus. She had multiple well-defined hypopigmented plaques over the neck, chest, upper back and forearm, suggestive of secondary syphilis (Figure 1 a,b). Hence, she was treated with single dose of benzathine penicillin G 2.4 million units intramuscularly.

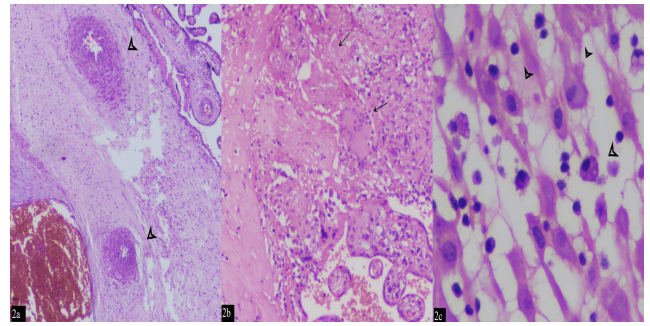


**Fig. 1:** **a:** Multiple well defined round skin colored to hypopigmented plaques distributed over neck; **b:** Lesions over upper chest

She delivered a baby boy of 1.4 kg by emergency preterm caesarean section (CS) at 32 weeks due to preterm premature rupture of membrane. Second dose of Injection benzathine penicillin was given as her RPR titres were high (1:32) even after first dose of benzathine penicillin. Neurosyphilis was ruled out.

There were no obvious congenital anomalies in the baby and no features suggestive of congenital syphilis. Baby received prophylactic single dose of Inj benzathine penicillin (50,000IU/kg) for prevention of congenital syphilis. Placental tissue histopathology report was positive for syphilis and included the triad of enlarged hypercellular villi, proliferative fetal vascular changes and villitis (Figure 2 a,b,c).

The newborn was tested negative for nontreponemal serologic test with no physical evidence of syphilis. The mother and baby was discharged on day 14 post-delivery in satisfactory condition. In follow up period of one-year baby was asymptomatic.



**Fig. 2:** **a:** Shows chorionic villi with arrow tips at Langhans giant cell with granuloma and necrosis, H & E stain, 10x; **b:** Second image with arrow tips highlighting thick walled vessels with concentric; **c:** Third image with arrow tips highlighting plasma cells, the top one with cytoplasmic; Russell bodies, H&E stain, 40x

### 3. Discussion

Syphilis in pregnancy remains an important cause of perinatal morbidity and mortality. It can lead to congenital syphilis due to transplacental transmission, especially in the third trimester leading to high rates of adverse fetal outcomes. It is important to evaluate the pregnant women in early pregnancy so that adequate treatment can be given to improve the fetal and neonatal outcome.<sup>6</sup> There are four stages of syphilis. Primary syphilis presents with painless ulcer called chancre in mouth or genitals; secondary syphilis presents 4-8 weeks after primary ulcer with rashes over the body and fever, fatigue and malaise; tertiary syphilis presents 1-10 years after initial infection with aortic insufficiency, aortic aneurysm, tabes dorsalis etc.<sup>7</sup>

Latent syphilis develops when primary or secondary syphilis is not treated but clinical manifestations resolve.

Our patient presented in the second trimester with rashes over the body. She had a prior history of ulcers in the mouth and her laboratory tests were also positive for syphilis. Hence a diagnosis of secondary syphilis was made. In a recent study done by Kulkarni et al, 33 new cases of syphilis were reported in the general population in 16 months duration with the majority of cases being secondary syphilis but the data about pregnancy was not clear in their study.<sup>8</sup>

There are two types of diagnostic tests for syphilis- non-treponemal and treponemal. The non-treponemal tests are VDRL and RPR which can be qualitative or quantitative. The treponemal tests are specific to syphilis and include TPFA, FTA-ABS, TPPA. Among these, FTA-ABS assay has highest sensitivity (85–100%) to detect all stages of syphilis.

According to the Centers for Disease Control and Prevention (CDC), an adequate response is defined as at least a fourfold decrease in non-treponemal antibody titre. CSF examination and retreatment should be considered if there is no four-fold decrease in non-treponemal test titre

within 3 months after treatment for primary or secondary syphilis or latent syphilis regardless of apparent duration.<sup>9</sup> In the present case, the titres were the same even after seven weeks of the first dose of benzathine penicillin, hence repeated the dose of Benzathine Penicillin G in mother and also given prophylactic treatment to the baby. Despite Injection Benzathine Penicillin G maternal treatment is said to be inadequate if mother delivers in 30 days of treatment, if there are clinical signs of infection at the time of delivery or there is fourfold rise in maternal antibody titre from pre-treatment titre.<sup>7</sup>

In case of syphilis, sonographic evaluation of fetus is important to look for signs of congenital syphilis like ascites, hydrops, hepatomegaly, fetal anemia or a thickened placenta. No such features were present in the antenatal scans of our patient which suggests that we started the treatment timely, however, post-delivery the histopathological examination of placenta showed the syphilitic triad. Women treated for syphilis during the second half of pregnancy are at risk for premature labor, fetal growth restriction, fetal infection, fetal distress leading to fetal death.<sup>7</sup> If mother is not treated for syphilis, babies presents with problems like blindness, deafness, and seizures in early neonatal period.<sup>10</sup> The recommended treatment for primary, secondary and early latent syphilis of less than one-year duration is Benzathine penicillin G 2.4 million units as a single injection some recommend a second dose 1 week later. For latent syphilis of unknown or more than one-year duration and tertiary syphilis weekly 3 doses of Benzathine penicillin G 2.4 million units are recommended.<sup>11</sup>

#### 4. Conclusion

Universal screening of all pregnant women at first antenatal visit with a non-treponemal test should be used for screening for syphilis in pregnancy.<sup>12</sup> Pregnant women proven to have syphilis by treponemal tests are to be treated adequately according to the stage and duration of syphilis. This can result in better fetal and neonatal outcomes.

#### 5. Source of Funding

None.

#### 6. Conflict of Interest

The author declares no conflict of interest.

#### 7. Acknowledgement


We acknowledge Dr. Abhishek Bhardwaj, Additional Professor, Dermatology, AIIMS Jodhpur, for clinical

opinion.

#### References

1. Phiske MM. Current trends in congenital syphilis. *Indian J Sex Transm Dis AIDS*. 2014;35(1):12–20.
2. National AIDS Control Organization, Ministry of Health and Family Welfare, Government of India. Annual Report 2015-16.
3. Korenromp EL, Rowley J, Alonso M, Mello MB, Wijesooriya NS, Mahiane SG. Global burden of maternal and congenital syphilis and associated adverse birth outcomes- Estimates for 2016 and progress since 2012. *PLoS One*. 2019;14(2):e0211720. doi:10.1371/journal.pone.0211720.
4. Santis M, Luca C, Mappa I, Spagnuolo T, Licameli A, Straface G, et al. Syphilis Infection during Pregnancy: Fetal Risks and Clinical Management. *Infect Dis Obstet Gynecol*. 2012;doi:10.1155/2012/430585.
5. Watson-Jones D, Chagalucha J, Gumodoka B, Weiss H, Rusizoka M, Ndeki L, et al. Syphilis in pregnancy in Tanzania. I. Impact of maternal syphilis on outcome of pregnancy. *J Infect Dis*. 2002;186(7):940–7.
6. Kulkarni V, Parchure R, Darak S. Let's not let the guard down! - Early indications of syphilis resurgence? *Indian J Dermatol Venereol Leprol*. 2019;85:246–7.
7. Pradhan M, Jain S. Syphilis in Pregnancy. *J Fetal Med*. 2020;21:1–7.
8. Workowski KA, Bolan GA. Sexually transmitted diseases treatment guidelines, 2015. MMWR. Recommendations and reports: Morbidity and mortality weekly report. Recommendations and reports. *MMWR Morb Mortal Wkly Rep*. 2015;64(RR-03):1.
9. Genc M, Ledger WJ. Syphilis in pregnancy. *Sex Transm Infect*. 2000;76(2):73–9. doi:10.1136/sti.76.2.73.
10. Newman L, Kamb M, Hawkes S, Gomez G, Say L, Seuc A, et al. Global estimates of syphilis in pregnancy and associated adverse outcomes: analysis of multinational antenatal surveillance data. *PLoS Med*. 2013;10(2):e1001396. doi:10.1371/journal.pmed.1001396.
11. WHO guideline on syphilis screening and treatment for pregnant women. Geneva: World Health Organization; 2017. Licence: CC BY-NC-SA 3.0 IGO.
12. US Preventive Services Task Force. Screening for syphilis infection in pregnancy: reaffirmation recommendation statement. *Ann Intern Med*. 2009;150:705–9.

#### Author biography

**Manisha Jhirwal**, Assistant Professor  <https://orcid.org/0000-0002-5413-3074>

**Charu Sharma**, Associate Professor

**Shashank Shekhar**, Professor

**Apoorva Tak**, Senior Resident

**Poonam Elhance**, Professor

**Cite this article:** Jhirwal M, Sharma C, Shekhar S, Tak A, Elhance P. Syphilis in pregnancy: The menace continues to haunt. *Indian J Obstet Gynecol Res* 2021;8(3):434-436.