

Content available at: <https://www.ipinnovative.com/open-access-journals>

Indian Journal of Orthopaedics Surgery

Journal homepage: <https://www.ijos.co.in/>

## Case Report

# Osteochondroma of rib: A case report

Abhijit Chandge<sup>1,\*</sup>, Narendra D Kulkarni<sup>2</sup>, Ashish M Chandge<sup>3</sup>

<sup>1</sup>Dept. of Orthopedic, Dr. Hedgewar Hospital, Aurangabad, Maharashtra, India

<sup>2</sup>Dept. of Surgery, Dr. Hedgewar Hospital, Aurangabad, Maharashtra, India

<sup>3</sup>Gurukrupa Diagnostic Centre, Ratnagiri, Maharashtra, India



### ARTICLE INFO

#### Article history:

Received 24-08-2021

Accepted 09-10-2021

Available online 01-12-2021

#### Keywords:

Osteochondroma

Rib

### ABSTRACT

**Introduction:** Osteochondroma is the most common benign tumor of bone, occurring either as an isolated lesion or in the context of hereditary multiple exostoses.<sup>1</sup> In both cases, osteochondroma can arise from the ribs, and is often asymptomatic. In fact, the diagnosis often follows the onset of serious complications either from mechanical interference with the neighboring anatomical structures, or from malignant degeneration.<sup>1,2</sup>

**Case Report:** We present a case of swelling over right side of chest wall in 40 year old male patient. X-ray and CT scan showed bony swelling over right ninth rib. Tumor was resected to avoid future complication. Subsequently, histological examination confirmed the diagnosis of osteochondroma and showed the lack of dysplastic changes.

**Conclusion:** Various studies have shown that the surgical resection of osteochondroma is necessary in adults to avoid future complications of haemothorax, pneumothorax, intercostals neuralgia and malignant transformation, hence we resected tumor in this case.

This is an Open Access (OA) journal, and articles are distributed under the terms of the [Creative Commons Attribution-NonCommercial-ShareAlike 4.0 License](https://creativecommons.org/licenses/by-nc-sa/4.0/), which allows others to remix, tweak, and build upon the work non-commercially, as long as appropriate credit is given and the new creations are licensed under the identical terms.

For reprints contact: [reprint@ipinnovative.com](mailto:reprint@ipinnovative.com)

## 1. Introduction

Osteochondroma (exostoses) is the result of dysplasia of the peripheral zone of the growth plate.<sup>3</sup> Surgery is required if tumor formation occurs in adulthood. Such pathological bony outgrowths should always be resected in adults to avoid future complications.<sup>4</sup>

## 2. Case Report

A 40 yrs old male patient presented with swelling over Right side of lower chest wall near distal part of sternum since 3 yrs. Initially small sized swelling gradually increased in size to present status over 3 yrs. On examination- Swelling approximately 6 x 4 cm in size situated over anterior part

of chest wall near distal most part of sternum on right side. It was firm Hard, non-pulsatile, non mobile. Skin over swelling was normal & freely mobile, No restriction of chest movements or difficulty in respiration.

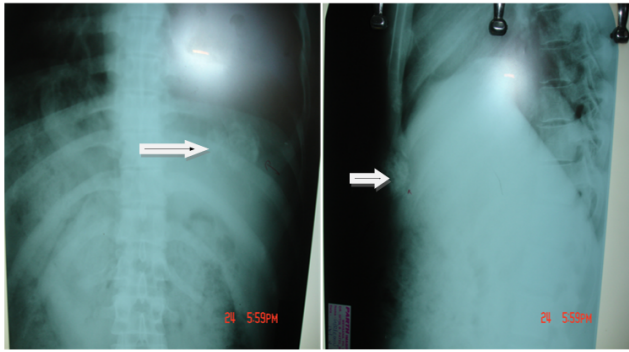
Patient was taken under General Anaesthesia in supine position. Incision taken directly over the swelling. Skin, subcut, muscle cut. Swelling was reached and removed completely from the surface of rib. Surface of rib was cauterized and bone wax was applied over cauterized area. As there was small rent in pleura, we put Foleys catheter as a chest drain. Romovac drain & Foleys catheter was removed after 2 day. Suture removal was done on 14<sup>th</sup> day.

## 3. Discussion

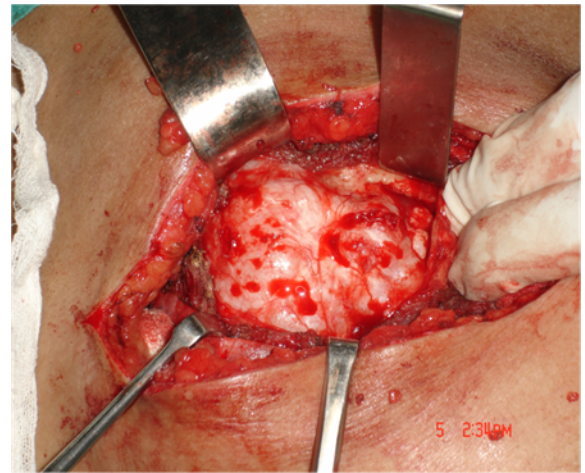
Osteochondroma of ribs are exceedingly rare. They may present as swelling over the chest wall or as incidental

\* Corresponding author.

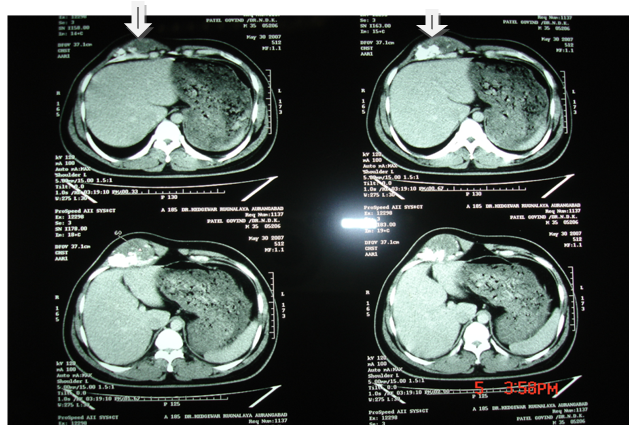
E-mail address: [dramchandge@gmail.com](mailto:dramchandge@gmail.com) (A. Chandge).



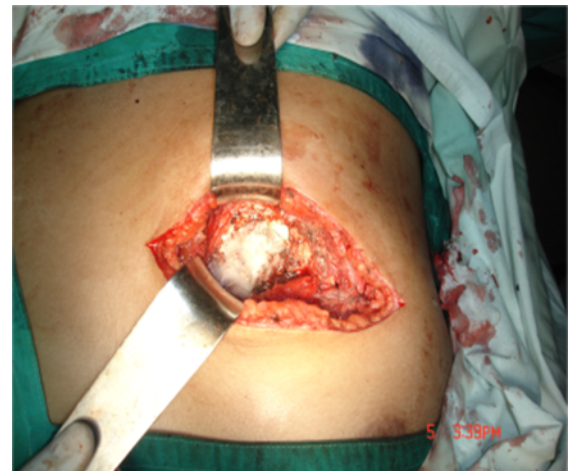**Fig. 1:** X-ray—AP view and lateral view showing tumor



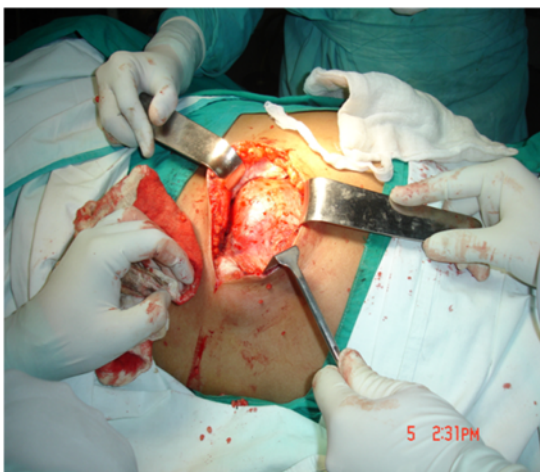**Fig. 4:** Wound showing tumor



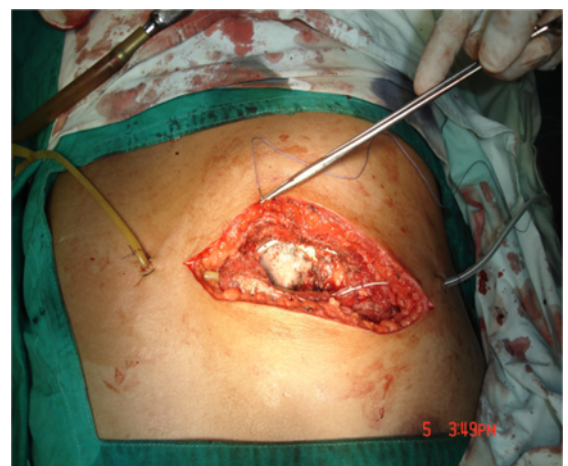**Fig. 2:** CT scan showing tumor



**Fig. 5:** Surface of rib cauterized and bone wax applied

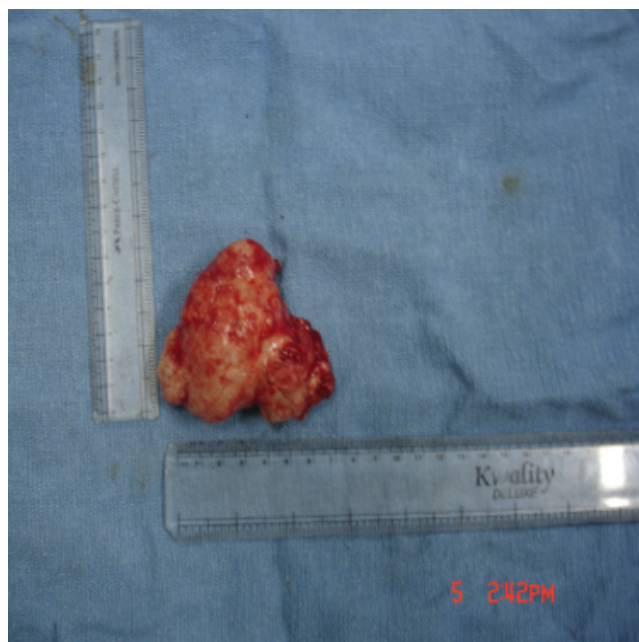

**Fig. 3:** Incision taken directly over swelling

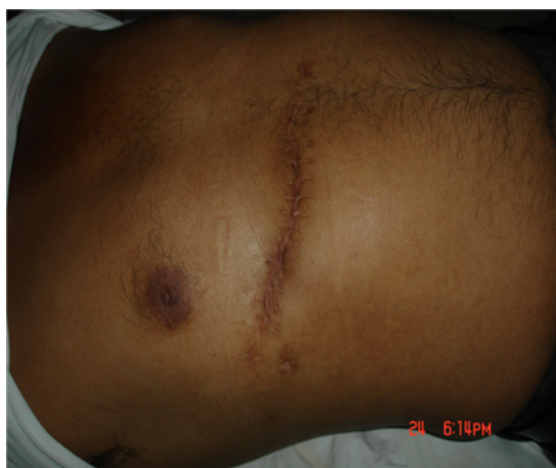

**Fig. 6:** Foleys catheter kept as chest drain as there was rent in pleura





**Fig. 7:** Excised tumor



**Fig. 8:** Postop 3 months

finding on chest radiograph. It may occur as a solitary lesion or in the context of hereditary multiple exostoses (HME).<sup>1</sup> Isolated lesions occur in infants, but are occasionally found in adults.

The radiographic appearance of an osteochondroma shows a smooth and lobulated surface; the deep aspect is generally well mineralized in a homogeneous manner. When the lesion is on a rib, in most cases the chest radiograph is not helpful in determining the exact site and location of the lesion. Computed tomography (CT) is the most sensitive examination to localize the lesion and to study its morphology and relationships with neighboring anatomical structures. CT scan is superior to radiography in identifying the unmineralized soft-tissue

component of these lesions. This examination may yield useful information regarding tumor extension, which in turn may aid in surgical planning. CT scan also helps establish the nature of the lesions and differentiates between osteochondroma and chondrosarcoma, even if only biopsy gives us the exact knowledge of the lesion's nature.

The exostoses are usually asymptomatic and complications are often the result of mechanical interference with neighboring anatomic structures.<sup>5–7</sup> As the mediastinum and lungs move during respiration, the spurs of these exostoses could damage the adjacent structures; causing life threatening conditions such as pneumothorax by injuring the lung, or hemothorax by injuring the diaphragm, pleura or heart.<sup>4,8</sup> It is generally believed that the risk of malignant degeneration of an isolated lesion to chondrosarcoma is around 1%–2%.<sup>1,3</sup> Because of these future potential complications, it is always recommended to remove this tumor in adults.<sup>4</sup>

#### 4. Source of Funding

None.

#### 5. Conflict of Interest

The authors declare no conflict of interest.

#### References

1. Clavert JM. Exostose solitaire et maladie exostosante. In: Lascombes P, Lefort G, editors. Les tumeurs osseuses de l'enfant. Montpellier, France: Sauramps Médical; 1996. p. 39–53.
2. Tomares SM, Jabra AA, Conrad CK, Beauchamp N, Phoon CK, Carrol JL. Hemothorax in a child as a result of costal exostosis. *Pediatrics*. 1994;93:523–5.
3. Schmale GA, Conrad EU, Raskind WH. The natural history of hereditary multiple exostoses. *J Bone Joint Surg Am*. 1994;76:986–992.
4. Teijeira F, Baril C, Young ED. Spontaneous hemothorax in a patient with hereditary multiple exostoses. *Ann Thorac Surg*. 1989;48:717–8.
5. Kane PJ, Coulthard A, Raghavan R, Jenkins A. Osteochondroma of the rib: an unusual cause of paraparesis. *Surg Neurol*. 1994;41:414–7.
6. Tang WM, Luk KD, Leong JC. Costal osteochondroma. A rare cause of spinal cord compression. *Spine*. 1998;23:1990–3.
7. Tuncer S, Erden I, Aydin N, Oge D. Acute spinal cord compression in hereditary multiple exostoses: case report. *Paraplegia*. 1989;27:402–5.
8. Reynolds JR, Morgan E. Haemothorax caused by a solitary costal exostosis. *Thorax*. 1990;45:68–9.

#### Author biography

**Abhijit Chandge**, HOD  <https://orcid.org/0000-0001-7372-1595>

**Narendra D Kulkarni**, HOD

**Ashish M Chandge**, Consultant Radiologist

**Cite this article:** Chandge A, Kulkarni ND, Chandge AM. Osteochondroma of rib: A case report. *Indian J Orthop Surg* 2021;7(4):356–358.