

Content available at: <https://www.ipinnovative.com/open-access-journals>

Indian Journal of Orthopaedics Surgery

Journal homepage: <https://www.ijos.co.in/>

## Case Report

# Subtalar joint dislocation: An uncommon injury, revisited

Anish Vernekar<sup>1,\*</sup>, Arun Krishnamoorthi<sup>1</sup>, S M Bandekar<sup>1</sup>

<sup>1</sup>Dept. of Orthopaedics, Goa Medical College, Goa, India



### ARTICLE INFO

#### Article history:

Received 11-06-2021

Accepted 12-10-2021

Available online 01-12-2021

#### Keywords:

Dislocation

Subtalar joint

Reduction

### ABSTRACT

Subtalar joint dislocations are very uncommon and occur following high energy injury, usually following motor vehicular accidents. They account for around 1-2% of dislocations. We present to you, a few cases of subtalar joint dislocation managed initially by closed reduction, followed by open reduction under anesthesia, with excellent functional outcome. Close to fifty percent of patients suffering from complicated injury, are frequently at risk of developing complications. Avascular necrosis of the talus is the most common complication, following dislocation. Other long-term sequelae include osteochondral fracture and subtalar joint instability. This study is presented because of its rarity in clinical practice.

This is an Open Access (OA) journal, and articles are distributed under the terms of the [Creative Commons Attribution-NonCommercial-ShareAlike 4.0 License](https://creativecommons.org/licenses/by-nc-sa/4.0/), which allows others to remix, tweak, and build upon the work non-commercially, as long as appropriate credit is given and the new creations are licensed under the identical terms.

For reprints contact: [reprint@ipinnovative.com](mailto:reprint@ipinnovative.com)

## 1. Introduction

Subtalar joint dislocation, which is synonymous with peritalar joint dislocation, is characterized by concurrent dislocation of the joints in vicinity of the talus, which includes the talocalcaneal and talonavicular joints.<sup>1</sup>

In this infrequent type of dislocation, the talus maintains its normal anatomical relation with the ankle mortise, while the calcaneus and navicular bones are dislocated under it. The sporadic type of dislocation is attributed to high energy trauma.<sup>1,2</sup>

“The etiology of subtalar dislocation was found to be 43.7% due to motor vehicular accidents. 32.9% was attributed to fall from height. Sports injury accounted for 13.9% cases and rest 9.5% due to miscellaneous causes. It also concluded that males were more commonly affected than females.”<sup>3-7</sup>

In this case report, we would like to present few cases of subtalar joint dislocation and their management that we encountered, in our clinical practice.

## 2. Case Report 1

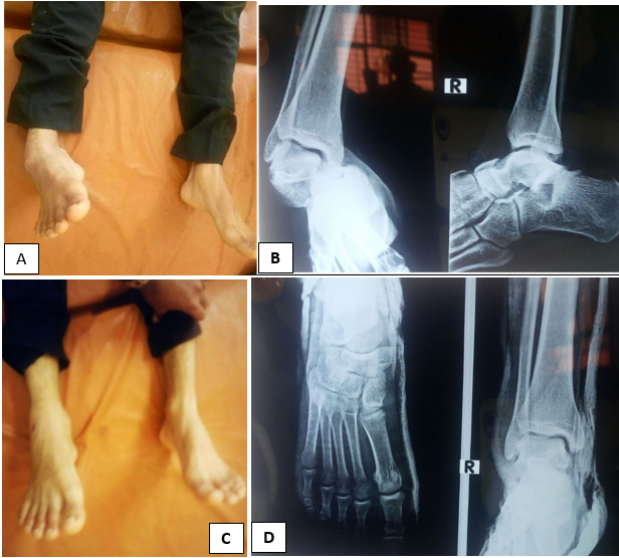A 23-year-old male, came to casualty following a Motor vehicle accident. Examination revealed medial dislocation of the right subtalar joint. Radiological study revealed subtalar joint dislocation, without any bony fracture. After sedation, closed manipulation was attempted and reduction achieved. Post reduction radiograph showed congruent reduction of subtalar joint. Patient was then managed with below knee plaster cast.

## 3. Case Report 2

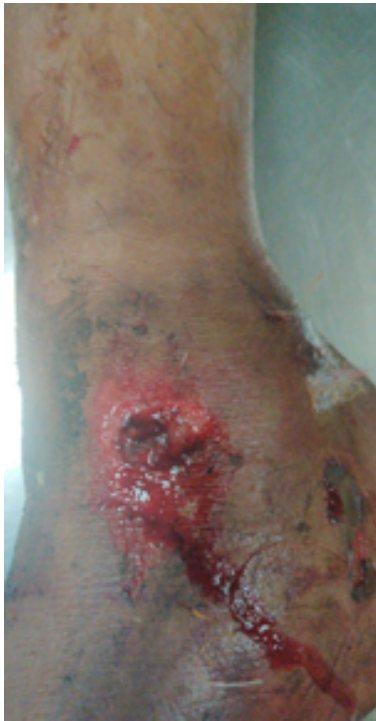On the 29th November 2020 a 50-year-old male, presented to the Emergency Department of Goa Medical College, following a Motor Vehicle Accident. Initial examination of the patient revealed a haemodynamically stable patient with supinated right fore-foot. During secondary survey, an abrasion was noted just behind the medial malleolus (Figure 2). Radiographs (Figure 3 A and B) revealed subtalar dislocation and this was further confirmed by CT scan. (Figure 4) Initially, reduction was attempted under sedation in casualty which failed.

\* Corresponding author.

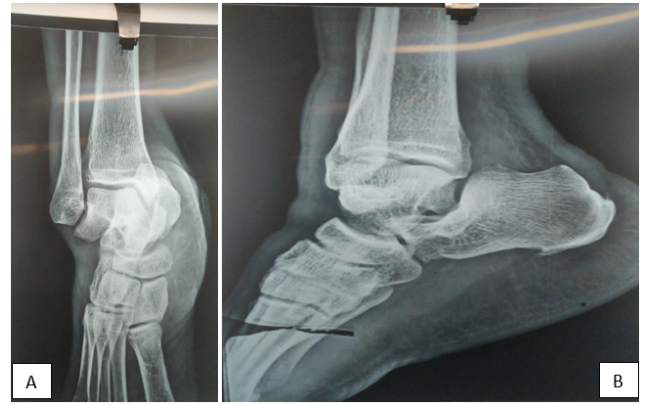E-mail address: [vernekaranish2013@gmail.com](mailto:vernekaranish2013@gmail.com) (A. Vernekar).



**Fig. 1:** A: Pre reduction clinical picture; B: Plain x-ray (AP and lateral view) showing subtalar joint dislocation; C: Showing post reduction clinical picture with; D: Plain radiograph (AP and lateral) showing congruent reduction of subtalar joint

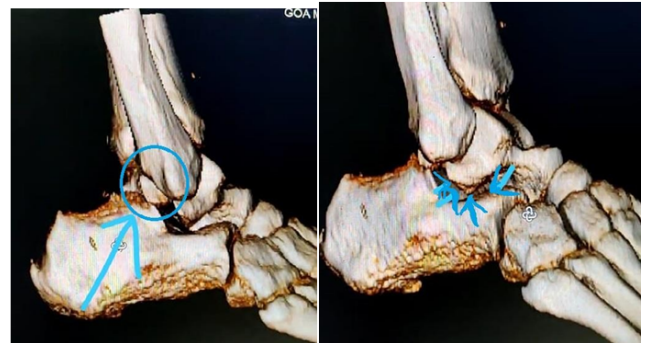


**Fig. 2:** Clinical picture showing abrasion over medial malleolus



**Fig. 3:** A: Antero-posterior view showing subtalar joint dislocation; B: Lateral radiograph showing subtalar joint dislocation.

Another attempt for closed reduction was done under sedation, which was successful. A repeat x-ray and CT scan was done to confirm the reduction. Post reduction CT revealed presence of osteochondral fragment within the subtalar joint, (Figure 4) which prevented congruent reduction of the subtalar joint.

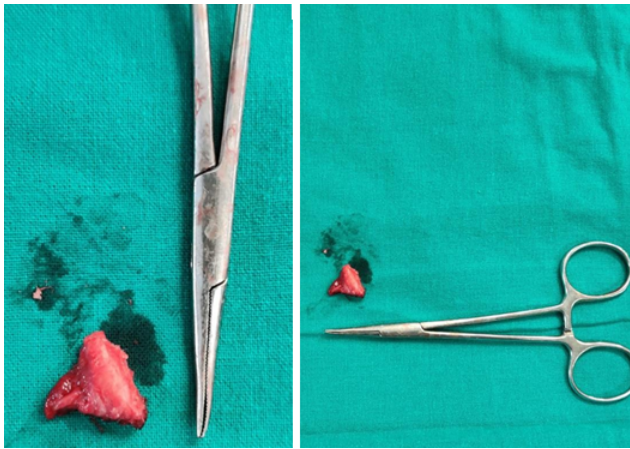


**Fig. 4:** CT 3d recon showing avulsion of posterior process of talus, which is intra-articular and causing incongruent reduction

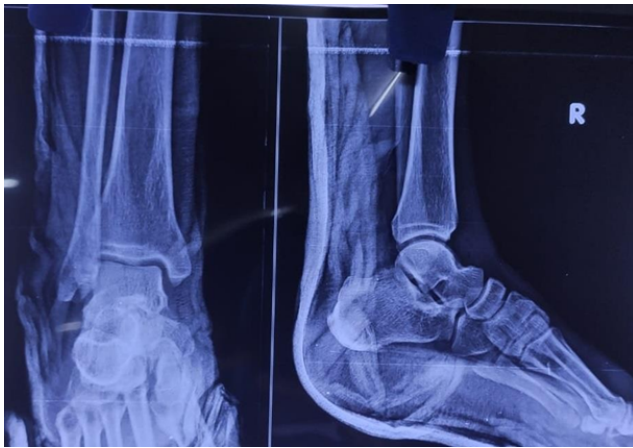Hence patient was planned for open reduction and removal of the fragment. Open reduction was performed and the loose fragment was removed (Figure 5) following this congruent reduction was confirmed under c-arm. Post operative x-ray showed congruent reduction of subtalar joint. (Figure 6)

Patient was then placed in below knee slab and non weight bearing for 3 weeks. Stitch removal was done after 2 weeks. Follow up check x-ray showed congruent alignment of subtalar joint. There was no fracture involved of surrounding tarsal bones. Full weight bearing was resumed after 6 weeks and full range of motion of ankle joint was achieved.





**Fig. 5:** Intra-op avulsion fragment removal, measuring, 1.5x1x1 cms



**Fig. 6:** Post op plain x-ray (AP and lateral view) showing congruent reduction of subtalar joint

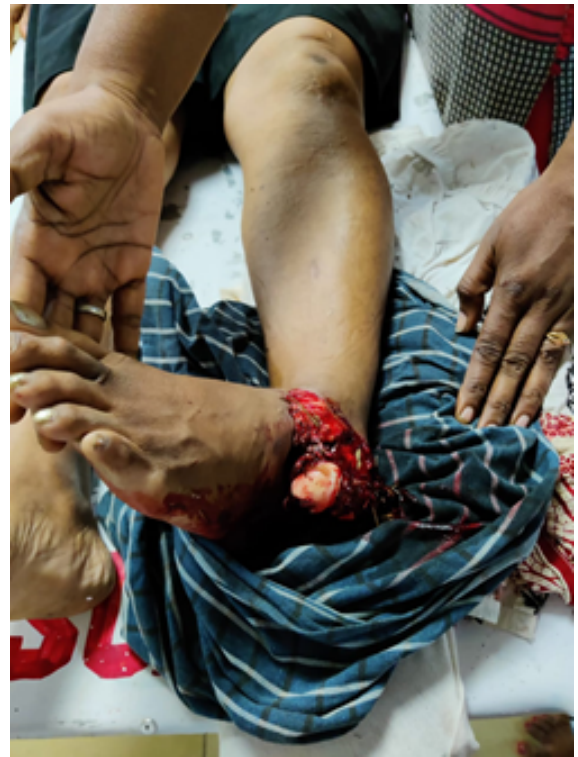#### 4. Case Report 3

A 35-year old patient came to casualty with injury to left ankle following motor vehicle accident. Examination revealed an open subtalar dislocation with exposed talus. Following lavage and debridement, reduction was attempted which was unstable. Patient was then operated under spinal anesthesia. K wire fixation was done under c-arm guidance.

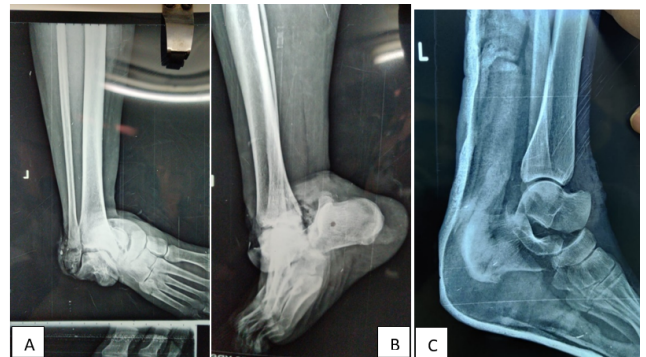#### 5. Discussion

Subtalar joint dislocation is an infrequent type of dislocation and this is credited to the presence of tough ligaments surrounding the talus, the strong joint capsule which maintains the anatomical relationship between the talus and the calcaneum.<sup>2,8</sup> Hence, they represent approximately 1% of all traumatic dislocations.<sup>9</sup>

Subtalar dislocations are classified based on the position of dislocated foot, along with the relation between calcaneus



**Fig. 7:** Clinical picture showing open subtalar dislocation with exposed talus and inversion of foot

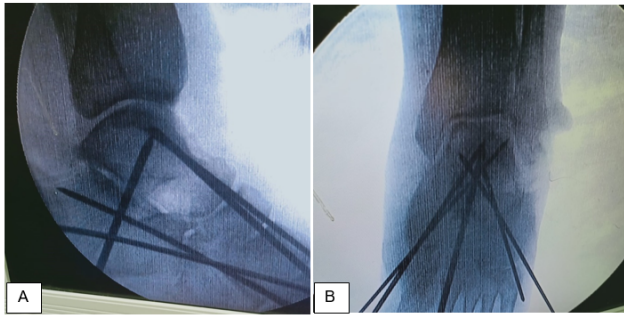


**Fig. 8:** **A:** Antero-posterior view x-ray medial subtalar joint dislocation; **B:** Lateral x-ray showing subtalar joint dislocation; **C:** Lateral x-ray showing incongruent reduction of subtalar joint

and talus. It was first introduced by in the year 1853 by Broca and later modified by Malgaigne et al in 1856.<sup>10</sup>

They are classified into medial dislocation, wherein the dislocated foot and calcaneus lie medial to talus and lateral dislocation defined by lateral position of foot and calcaneus with respect to the talus. Medial dislocations are most common, comprising of 85% of all dislocations. Anterior and Posterior dislocations are extremely rare.<sup>11</sup>

Forced inversion, with the hind foot in equinus leads to medial dislocations. They usually occurs following low-



**Fig. 9:** **A:** Lateral x-ray showing congruent reduction of subtalar joint, with k-wire fixation; **B:** Lateral x-ray showing congruent reduction of subtalar joint, with k-wire fixation

energy trauma where, the sustentaculum talus acts as the pivot. The overall prognosis is usually good with less incidence of avascular necrosis of talus. Exclusive ligamentous dislocation has excellent functional outcome and prognosis after proper reduction.<sup>12,13</sup>

In contrast, forced eversion of foot, with high energy trauma leads to lateral peritalar dislocation. The overall prognosis is generally poor, as they are commonly associated with fractures of surrounding bones and more frequent incidence of avascular necrosis of talus. Hence, it is imperative to diagnose associated fractures of lateral process of talus and sustentaculum tali, which leads to osteoarthritis of subtalar joint.<sup>14</sup>

There is no consensus on the duration of immobilization after reduction. Early weight bearing protocol is advocated, in uncomplicated cases, after a below knee cast for a period of 3-4 weeks. In complicated cases with instability, the use of an external fixator is advisable; hence delaying ambulation for a period of up to 6-12 weeks, depending on the extent of additional fractures of the tarsal and metatarsal bones.<sup>15</sup>

## 6. Conclusion

Uncomplicated, low-energy subtalar dislocations that are stable after closed reduction can be mobilized early and usually have excellent prognosis. Increasing severity of trauma, with associated fractures usually have poor outcomes. The most common complication following subtalar joint dislocation is post-traumatic arthritis involving the subtalar joint, reported rates being 25-89%. Osteonecrosis of talus is second most common complication.<sup>16</sup>

If closed reduction is done immediately following trauma, excellent functional outcomes are expected in majority of patients.

## 7. Source of Funding

None.

## 8. Conflict of Interest

The authors declare no conflict of interest.

## References

1. Giannoulis D, Papadopoulos DV, Lykissas MG, Koulouvaris P, Gkiatas I, Mavrodontidis A. Subtalar dislocation without associated fractures. Case report and review of literature. *World J Orthop.* 2015;6:374–9.
2. Kulambi V, Gaurav M. Lateral subtalar dislocation: A case report. *Foot Ankle Online J.* 2014;7(3):4.
3. James D. Functional outcome after early mobilization in isolated subtalar dislocation. Case report and review of current evidence. *J Orthop Traumatol Rehabil.* 2017;9:50–2.
4. Hoexum F, Heetveld MJ. Subtalar dislocation: two cases requiring surgery and a literature review of the last 25 years. *Arch Orthop Trauma Surg.* 2014;134:1237–49.
5. Simon LC, Schulz AP, Faschingbauer M, Morlock M, Jürgens C. Basketball Foot—long-time prognosis after peritalar dislocation. *Sportverletz Sportschaden.* 2008;22(1):31–7.
6. Goldner JL, Poletti SC, Gates HS, Richardson WJ. Severe open subtalar dislocations. Long-term results. *J Bone Joint Surg Am.* 1995;77:1075–7.
7. Garofalo R, Moretti B, Ortolano V, Cariola P, Solarino G, Wettstein M, et al. Peritalar dislocations: a retrospective study of 18 cases. *J Foot Ankle Surg.* 2004;43:166–72.
8. Carvera TP. Subtalar dislocation Case report and literature review. *Global J Med Res.* 2016;16:1.
9. Black K, Ehler KJ. A stress fracture of lateral process of talus in a runner. A case report. *J Bone Joint Surg Am.* 1994;76(3):441–3.
10. Hotouras A, Sandiford N, Rao S. Medial subtalar dislocation: A case report. *Int J Orthop Surg.* 2006;5:1–4.
11. Hoexum F, Heetveld MJ. Subtalar joint dislocation: Two cases requiring surgery and literature review of last 25 years. *Arch Orthop Trauma Surg.* 2014;134(9):1237–49.
12. Wagner R, Blattert TR, Weckbach A. Talar dislocations. *Injury.* 2004;35(2):36–45.
13. Waldrop J, Ebraheim NA, Shapiro P, Jackson WT. Anatomical considerations of posterior tibialis tendon entrapment in irreducible lateral subtalar dislocation. *Foot Ankle.* 1992;13:458–61.
14. Rammelt S, Goronzy J. Subtalar dislocations. Missed and associated injuries after subtalar dislocation: the role of CT. *Foot Ankle Int.* 2001;22:324–8.
15. Karampinas PK, Kavroudis E, Polyzois V, Vlamis J, Pneumaticos S. Open talar dislocations without associated fractures. *Foot Ankle Surg.* 2014;20:100–4.
16. Goldner JL, Poletti SC, Gates HS, Richardson WJ. Severe open subtalar dislocations. Long term results. *J Bone Joint Surg Am.* 1995;77(7):1075–9. doi:10.2106/00004623-199507000-00015.

## Author biography

**Anish Vernekar**, Senior Resident

**Arun Krishnamoorthi**, Senior Resident

**S M Bandekar**, HOD

**Cite this article:** Vernekar A, Krishnamoorthi A, Bandekar SM. Subtalar joint dislocation: An uncommon injury, revisited. *Indian J Orthop Surg* 2021;7(4):348-351.