



Original Research Article

Dual mobility total hip arthroplasty for treatment of displaced fracture neck of femur

Aubrey Conrad Franco^{1,*}, Sharath Ramanatha Kittankere¹, Naresh Shetty¹, Ashok Kumar P¹, Rahul P¹¹Dept. of Orthopaedics, M. S. Ramaiah Medical College, Bangalore, Karnataka, India

ARTICLE INFO

Article history:

Received 21-12-2020

Accepted 23-07-2021

Available online 26-08-2021

Keywords:

Aged

Femoral neck fractures

Arthroplasty

Visual analogue scale

Hip Fractures

Pain

ABSTRACT

Introduction: Total hip arthroplasty (THA) for femoral neck fracture (FNF) cases is five times associated with the dislocation risk compared to THA for osteoarthritis. It is highlighted that a THA with dual mobility cup has lower rates of dislocation in elective surgery and revision procedures. However, there is a paucity in studies regarding this treatment area. The objective of this study was to evaluate the functional outcome of displaced FNF with dual mobility THA.

Materials and Methods: Two-year prospective study comprised of 25 patients with <10 days old displaced FNF, aged >55 years. Clinical and pain evaluation were done using Harris Hip score (HHS) and visual analogue scale (VAS) score. Paired T test was used to compare mean values and a $P \leq 0.05$ was considered statistically significant.

Results: Most patients were aged 55-65 years and had comorbidities (84%). A significant change in pre- and post-operative HHS (81.86 ± 11.37 vs. 90.67 ± 7.86) as well as pre- and post-operative (1 and 6 month) VAS scores (6.40 ± 0.82 vs. 1.56 ± 0.65 and 6.40 ± 0.82 vs. 0.32 ± 0.48 ; $P < 0.0001$) were noted. Three cases of complications and no dislocations were noted. A significant difference in LLD (1.77 ± 0.40 vs. 2.33 ± 0.29 , $P = 0.0261$) and flexion (113.64 ± 10.71 vs. 95 ± 13.29 , $P = 0.0381$) was observed between cases without and with post-operative complications respectively.

Conclusion: Current cement-less dual mobility THA is associated with a pain free mobile hip and durable acetabular fixation with an increased range of movements at the hip. Dual mobility cup may be considered a valuable option to prevent post-operative dislocation in elderly patients with FNF.

This is an Open Access (OA) journal, and articles are distributed under the terms of the [Creative Commons Attribution-NonCommercial-ShareAlike 4.0 License](https://creativecommons.org/licenses/by-nc-sa/4.0/), which allows others to remix, tweak, and build upon the work non-commercially, as long as appropriate credit is given and the new creations are licensed under the identical terms.

For reprints contact: reprint@ipinnovative.com

1. Introduction

Femoral neck fracture (FNF) is a global primary public health concern. Nearly 3 and 12 billion USD are respectively spent for managing elderly patients (>60 years) suffering from hip fractures in the United Kingdom and United States of America annually.^{1,2} In India, there were 0.6 million cases of osteoporotic hip fracture in 2004, which is expected to significantly rise by 9.3% by 2025 due to increase in the elderly population.^{3,4} Elderly people are

fragile and suffer from multiple medical co-morbidities such as anemia, hypertension and diabetes mellitus.⁵ Females are reported to be more prone to hip fractures with a male to female ratio of 2:1.⁶ Moreover, patients with a displaced FNF are also associated with an increased morbidity and mortality, along with reduced mobility and function.⁷

Researchers have reported that primary cost determinants for hemi- or total hip arthroplasty (THA) is around €26,399/patient for the first two years. A majority of the amount is used in the first year, for rehabilitation and nursing expenses.⁸ Therefore, cost reduction is mainly emphasized by many researchers by focusing on the improvement

* Corresponding author.

E-mail address: hmmr.submission@gmail.com (A. C. Franco).

in surgery time, along with efficiency of rehabilitation phase post hip fracture surgery. Furthermore, an ongoing discussion about the optimal treatment for displaced FNF in elderly patients has been taking place for decades.^{9,10}

Researchers have evaluated the THA with a conventional cup as well as a dual mobility cup (DMC) and have highlighted that a THA with DMC has lower rates of dislocation in elective surgery and revision procedures.^{11,12} However, there is a dearth in literature on the effects of THA with DMC for treating patients with displaced femoral neck fractures and only a few studies on dual mobility THA as a treatment modality in FNF have shown good results. Therefore, the present research was focused on assessing the functional outcome of dual mobility total hip replacement for FNF due to it being a relatively newer implant with little data available regarding the implant in the Indian population.

2. Materials and Methods

This prospective study was conducted from December 2015 to August 2017 at a tertiary care centre. Approval from the institutional ethics committee and written informed consent from all patients undergoing dual mobility arthroplasty was acquired before the commencement of the study. Patients with displaced FNF <10 days old (Garden type 3-4) and aged >55 years were included, and those with co-existing secondary osteoarthritis, avascular necrosis, infective pathology, tuberculosis and rheumatoid arthritis were excluded from this study.

2.1. Sample size

Based on a previously conducted study⁷ that revealed a 95% success rate with dual mobility cup, considering a relative precision of 12% and desired confidence interval of 95%, a minimum of 14 subjects were needed for the current study. Hence, a total of 25 patients having FNF were enrolled for this study.

2.2. Pre-operative patient assessment

All patients were assessed preoperatively with radiographs of pelvis with both hips – anteroposterior (AP) view and relevant blood investigations along with Harris hip score (HHS), visual analogue scale (VAS) score, vertical and horizontal offset on X-ray pelvis and length of limb shortening (clinically). The HHS was a questionnaire-based assessment of patients before undergoing surgery, regarding their preinjury condition.¹³ VAS score was taken to assess the amount of pain,¹⁴ while the amount of limb shortening was measured using a non-stretchable measuring tape.

Vertical and horizontal offset was measured from the X-rays using Osirix software. The distance between the centre of femoral head and tip of lesser trochanter on the normal unaffected hip was defined as vertical offset. Horizontal

offset was measured as the distance between the centre of femoral head and the anatomic axis of the femur on the normal side (Figure 1),¹⁵ and patients were followed up at one and six months for HHS and VAS scores, and later at one year for any case of dislocation.

Patients were counselled regarding the consequences of total hip replacement (inability to sit on the floor, sit cross legged or squat post-operatively) and were operated by trained orthopedic surgeons using the posterior approach (Figure 2), under combined epidural and spinal anesthesia.

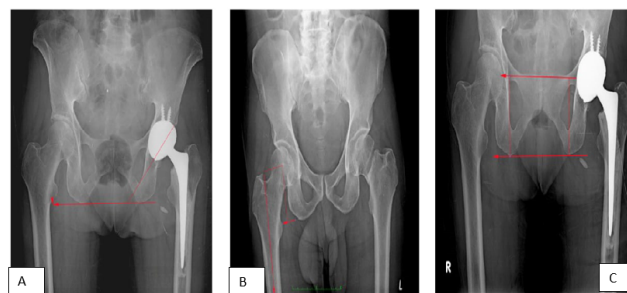


Fig. 1: Vertical and horizontal offset and cup inclination measurements a): Cup inclination measurement; b): Leg length measurement and c): Horizontal and vertical offset measurement

2.3. Statistical analysis

Data was analyzed using R v 3.6.2 and results were presented as frequency distribution, percentages, mean and standard deviation. Wilcoxon test was used to compare means of VAS and HHS scores from pre-operative and post-operative follow-up, along with success rate with respect to limb length discrepancy (LLD), cup inclination, flexion, extension, abduction, adduction, external and internal rotation. $p \leq 0.05$ was considered as statistically significant.

2.4. Implants used

Evolutis Dual mobility THA implants or Stryker implants—MDM cup and Exeter stem were used. Captiv DM uncemented acetabular cups with hydroxyapatite coating of various sizes along with uncemented femoral stems with metal heads of 28 mm size and HPE crosslinked acetabular cup liners. Femoral head sizes of size 22.2 and 28 mm were used.

2.5. Operative procedure

All patients were managed preoperatively with skin traction and foot end elevation of bed. Patients were operated under combined epidural and spinal anesthesia. Cefuroxime injection (3 g) was given 30 mins prior to skin incision. The surgical procedure is outlined in Figure 2 a-q. Patients were positioned on right or left lateral position with the affected hip facing upwards on the operating table. The

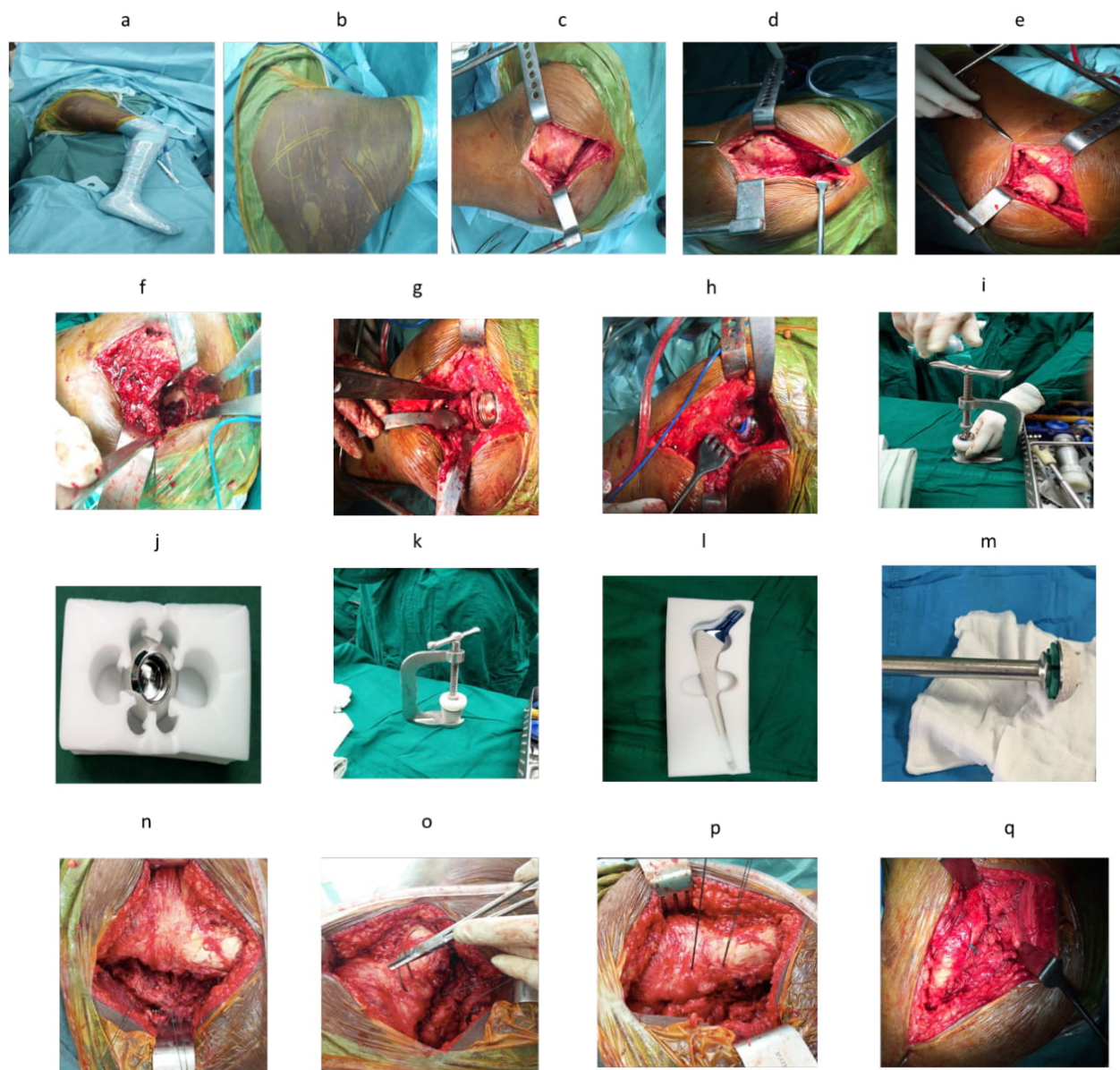


Fig. 2: Details of surgical procedure along with implant; **a):** Patient positioned in lateral position with affected side facing upwards; **b):** Skin incision marked for Moore’s approach; **c):** Charnley’s retractor applied after splitting gluteus maximus fibers and care take to avoid sciatic nerve; **d):** Interval between gluteus medius and piriformis; **e):** Femoral head being delivered out using cork screw and Hohmann retractors; **f):** Acetabulum floor visualized and labrum excised prior to Acetabular reaming; **g):** Acetabular cup Parallel to TAL-transverse acetabular ligament; **h):** Acetabular cup with liner; **i):** Loading of the femoral head into the liner to achieve “snap-fit”; **j):** Femoral head (metal); **k):** Femoral head with the polyethylene liner; **l):** femoral stem; **m):** Acetabular DMC; **n):** Ethibond sutures taken through short external rotators (SER) and capsule Prior to detaching from GT (greater trochanter); **o):** Passing the sutures through drill holes made in the GT; **p):** Post repair to GT and **q):** SER and capsule approximated to GT

pelvis was stabilized anteriorly with a pelvis post at the level of pubic symphysis, and posteriorly with a post maintained at the level of posterior superior iliac spine with adequate padding. Axillary padding was kept, and ipsilateral upper limb maintained on an aeroplane splint. The opposite knee was kept in semi flexed position to prevent forward tilting of pelvis and for intra-operative limb length assessment. Proper padding in all pressure points (knee, axilla and forearms) was done (Figure 2 a).

The operative site was prepared preoperatively by scrubbing before painting, and the affected hip was draped in a sterile manner with disposable drapes. The outline of the greater trochanter was marked with a skin pen (Figure 2 b). Patients were operated by using the Posterior Moore approach¹⁶ as described by Moretti et al.¹⁷ Trial implant insertion was followed by insertion of the final implants. Vertical offset was measured intra-operatively from the base of lesser trochanter to centre of femoral head and compared to preoperative measurement. Later, the hip was reduced, and stability was then confirmed in all movements and shuck test done. Whenever shuck test laxity was noted, next neck size was used, with care not to cause lengthening and a combined anteversion was measured.

Wound wash was given and short external rotators (SER) were repaired to greater trochanter (GT)¹⁸ wherein using a 2.7 mm drill bit, two holes were made in the GT and SER attached to it, followed by application of a suction drain of size 14 and later fixed using Mersilk sutures. The wound was closed in layers using interrupted sutures (Vicryl No. 1 and 2-0), followed by skin stapling. Immediately post-operation, an abduction pillow was put before shifting patient out of the operation theater.

2.6. Post-operative protocol

The suction drains were removed after day 2 post-operation, followed by suture removal on day 12 post-operation. Ambulation was started on day 1 post-operation with full weight bearing with walker. Abduction pillow was maintained between the legs immediately post-surgery and patients were advised to follow it until six weeks. On an average, patients were discharged on day 5 post-operation and followed up at one month, six months and one year after removal of sutures. Plain radiographs were taken on each follow up visit to assess the implant position. All patients received only three doses of one parenteral antibiotic and the first dose of anticoagulant therapy (low molecular weight Heparin 40mg) was administered subcutaneously within 12 hours of surgery and continued once daily for five days post-surgery, followed by oral dose of Ecospirin (75mg) once daily for three weeks. Calcium supplementation was also given for three months post-surgery.

2.7. Post-operative patients assessment

Post operatively, patients were examined clinically and radiologically at one and six months. Post-operative check radiographs were analyzed for vertical offset, horizontal offset, cup inclination and leg length. Cup inclination and leg length were measured.¹⁹ Radiographs were also analyzed for signs of osteolysis and migration of implants.

3. Results

The mean age of the patients was 67.25±8.37 years and mean duration of hospital stay was five days. The majority belonged to the age group of 55-65 years (48%) with female predominance of 56% and had comorbidities (84%) (Tables 1 and 2). Among patients having comorbidities, the most frequent were hypertension (44%) and diabetes mellitus (36%). All patients sustained the fracture after history of self-fall while walking. Right sided NOF was the seen in 60% of patients. Most patients had a surgery time of 2-3 h (52%), radiological LLD of <2 mm (52%), clinical LLD of <5 mm (72%), cup inclination of 41-50° (92%), flexion of 110-120° (76%) and abduction of 30-40° (76%). Many patients had abduction and external rotation of 30-40° and internal rotation and adduction of 10-20°. The mean range of movement was noted to be 111.40±12.38°, 12.00±4.56°, 32.00±6.77°, 34.80±6.20°, 17.00±5.00° and 15.60±3.63° for flexion, extension, abduction, adduction, external and internal rotation, respectively. In majority of patients, the HSS was 90-100 in both the pre- and post-operative stage, and Table 3 the VAS score at the pre- and post-operative (one and six months) stages were 3-6 (56%) and 0-2 (1-month: 92% and 6-month: 100%) respectively, indicating profound improvement in the post-surgical period (Table 1).

A significantly lower mean HSS was noted in the preoperative period, compared to HSS six months post-op (81.86±11.37 vs. 90.67±7.86; p<0.0001), indicating that post surgery, there was an improvement in the patients' condition. VAS score was significantly reduced on comparing preoperative with post-operative scores at one (6.40±0.82 vs. 1.56±0.65) and six months (6.40±0.82 vs 0.32±0.48; p<0.0001) (Table 3).

In this study, 3 patients had intra- or post-operative complications (periprosthetic fracture, acetabulum fracture and foot drop). Among patients with complications, there was a significant increase in limb length discrepancy (1.77±0.40 vs. 2.33±0.29; p=0.0261) and significant reduction in flexion (113.64±10.71 vs. 95±13.29; p=0.0381) compared to patients without any complications (Table 4).

4. Discussion

Till date, there have been only a few studies that have focused on issues pertaining to the use of dual mobility THA

Table 1: Description of patient population

| Parameters | No. of patients (N=25) | | |
|---|------------------------|----|------|
| | n | % | |
| Age (Years) | 55-65 | 12 | 48 |
| | 65-75 | 8 | 32 |
| | above 75 | 5 | 20 |
| Gender | Female | 14 | 56 |
| | Male | 11 | 44 |
| Diagnosis | Left NOF | 10 | 40 |
| | Right NOF | 15 | 60 |
| Duration of Surgery (Hours) | <2 | 13 | 52 |
| | 2-3 | 12 | 48 |
| | >3 | 0 | 0 |
| Radiological Limb length discrepancy (mm) | <2 | 13 | 52.0 |
| | 2-3 | 11 | 44.0 |
| | >3 | 1 | 4.0 |
| Clinical limb length discrepancy (mm) | <5 | 18 | 72.0 |
| | 5-7 | 7 | 28.0 |
| | >10 | 0 | 0 |
| Cup inclination (Degrees) | 30-40 | 0 | 0.0 |
| | 41-50 | 23 | 92.0 |
| | >50 | 2 | 8.0 |
| Flexion (Degrees) | <110 | 4 | 16.0 |
| | 110-120 | 19 | 76.0 |
| | >120 | 2 | 24.0 |
| Extension (Degrees) | <5 | 2 | 8.0 |
| | 5-15 | 23 | 92.0 |
| | >15 | 0 | 0.0 |
| Abduction (Degrees) | <30 | 5 | 20 |
| | 30-40 | 19 | 76 |
| | >40 | 1 | 4 |
| External rotation (Degrees) | <30 | 3 | 12 |
| | 30-40 | 20 | 80 |
| | >40 | 2 | 8 |
| Internal Rotation (Degrees) | <10 | 1 | 4 |
| | 10-20 | 21 | 84 |
| | >20 | 3 | 12 |
| Adduction (Degrees) | <10 | 1 | 4 |
| | 10-20 | 24 | 96 |
| | >20 | 0 | 0 |
| Preoperative HHS | <70 | 3 | 12 |
| | 70-79 | 9 | 36 |
| | 80-89 | 3 | 12 |
| Post-surgery 6 months HHS | 90-100 | 10 | 40 |
| | <70 | 0 | 0 |
| | 70-79 | 3 | 12 |
| Pre-operative VAS scale | 80-89 | 4 | 16 |
| | 90-100 | 18 | 72 |
| | 0-2 | 0 | 0 |
| 1-month Post-operative VAS scale | 3-6 | 14 | 56 |
| | 7-9 | 11 | 44 |
| | 10 | 0 | 0 |
| 6-month Post-operative VAS scale | 0-2 | 23 | 92 |
| | 3-6 | 2 | 8 |
| | 7-9 | 0 | 0 |
| | 10 | 0 | 0 |
| | 0-2 | 25 | 100 |
| | 3-6 | 0 | 0 |
| | 7-9 | 0 | 0 |
| | 10 | 0 | 0 |

NOF: Neck of femur fracture; HHS: Harris Hip Score; VAS: visual analogue scale

Table 2: Details of comorbidities among patients

| Comorbidities | Number of Patients (N=25) | |
|----------------------------------|---------------------------|----|
| | n | % |
| Absent | 4 | 16 |
| Diabetes mellitus | 9 | 36 |
| Hypertension | 11 | 44 |
| Hepatitis B | 3 | 12 |
| Right side hemiplegia | 1 | 4 |
| Right distal radius fracture | 1 | 4 |
| Bilateral distal radius fracture | 1 | 4 |
| Cardiac pacemaker in situ | 2 | 8 |
| History of alcohol consumption | 1 | 4 |
| T12 compression fracture | 1 | 4 |
| COPD | 3 | 12 |
| Parkinson's disease | 1 | 4 |
| Anaemia | 1 | 4 |

COPD: Chronic obstructive pulmonary disease and percentages can be more than 100% as patients have more than one comorbidity

Table 3: Comparative account of Harris Hip and VAS score at preoperative and post-operative stages

| Variables | | Mean ± SD | p-value |
|------------------|-------------------------|-------------|--|
| Harris Hip Score | Pre-operation | 81.85±11.37 | 0.00008168* |
| | 6-months post-operation | 90.67±7.86 | |
| VAS Score (mm) | Pre-operation | 6.40±0.82 | 0.00000523 [¥] * and 0.00000497 [€] * |
| | 1-month post-operation | 1.56±0.65 | |
| | 6-months post-operation | 0.32±0.48 | |

VAS: Visual analogue scale

* indicates the P<0.001

[¥]denotes P value on comparing the visual analogue scale score between pre-operation and 1-month post-operation

[€]denotes P value on comparing the visual analogue scale score between pre-operation and 6-month post-operation

Table 4: Comparison of various variables in relation to success rate

| Variables | Complication | | Total | p-value |
|-------------------------|---------------|---------------|--------------|---------|
| | Absent (N=22) | Present (N=3) | | |
| Limb length discrepancy | 1.77±0.40 | 2.33±0.29 | 1.84±0.43 | 0.0261* |
| Cup Inclination | 47.64±5.19 | 46.33±3.21 | 47.48±4.96 | 0.673 |
| Flexion | 113.64±10.71 | 95±13.29 | 111.40±12.38 | 0.0381* |
| Extension | 12.73±3.69 | 6.66±7.64 | 12.00±4.56 | 0.1255 |
| Abduction | 32.95±6.11 | 25.5±8.66 | 32.00±6.77 | 0.1255 |
| External rotation | 35.45±6.15 | 30±5.0 | 34.80±6.20 | 0.1307 |
| Internal rotation | 17.04±5.04 | 16.66±5.77 | 17.00±5.00 | 1.0 |
| Adduction | 15.91±3.66 | 13.33±2.89 | 15.60±3.63 | 0.1801 |

for the treatment of acute displaced FNF. This is one such prospective study among a handful, that has analyzed the use of dual mobility cup in southern region of India with respect to dislocation, revision rate and functional outcome after THA with captive DMC. Researchers have highlighted that dual mobility THA has good clinical short to long-term results with significantly less pain, lower dislocation rates and better outcomes represented by quality of life and functional scores.^{20–23}

The mean duration of surgery reduced over a period, which may be partly explained by a possible learning curve with the introduction of a new implant. All patients had cementless implants except for three. The acetabular cup

was a peripheral locking cup with spikes and did not have the option of screw fixation which may have been beneficial. Cup inclination in majority of the patients was 41–50° in our study. Similar results were reported by Carulli et al.,²⁴ where the mean cup inclination was 45.4° (range 42–49°). The hip post-operative range of motion at 6 months was found to provide good range of movements in all planes and in accordance with the study findings of Le Duff et al.²⁵ Majority of the patients in our study exhibited 110–120° for flexion, 30–40° for external rotation, 10–20° for internal rotation, 10–20° for adduction and 30–40° for abduction ranges of motion. Similar results were reported in an earlier conducted study, where mean ranges of motion of 120° for

flexion, 40° for external rotation, 20° for internal rotation, 20° for adduction and 40° for abduction.²⁶

Most of our patients prior to fall were active and had good functional capacity. However, majority of our patients had excellent and good results post-operatively. The change in HHS post-surgery was significantly higher compared to before surgery ($p < 0.001$). Results of Fahad et al.²⁷ were in concordance with present study findings and reported significantly higher HHS post-operatively ($p < 0.01$). However, they compared bipolar hemiarthroplasty vs. THA with DMC. A pre- and post-operative scoring with a validated HHS in the present study has taken account of lifestyle of study population, whose activities of daily living involve sitting down on the floor without wearing shoes. This may have aided to provide more information about the functional results of these implant systems. Significant improvement in the VAS score 6 months post-surgery was noted as well (0.32 ± 0.48). In a study where direct anterior approach was employed, median VAS score of 0 was reported during the 3 months to 1-year post-surgical follow-up period.²⁶ Moreover, researchers have ruled out concerns about the potential wear by using a mean annual volumetric polyethylene wear of 54.3 mm^3 .²⁸ Therefore, DMC may be a choice in severe osteoporosis cases, however, the fixation quality remains questionable for longer period of time.

Post-surgical complications were analyzed, and three complications in total were noted. One patient had post-operative foot drop which did not improve up to one-year post surgery. Another patient sustained an acetabulum wall fracture Paprovsky Type B1 and required a single plating of posterior column and cemented cup fixation. The third patient sustained a periprosthetic fracture Vancouver Type B1 after history of a repeat fall which was treated by cable fixation alone. One of the most common post-operative complications noticed in patients post-THA is fracture.²⁹

IPD is peculiar to the DMC due to bottle opener effect. However, this study did not note any intra-prosthetic dislocation (IPD) post-operatively on follow up. Similar findings were noted by Tarasevicius et al.,³⁰ who also reported no dislocation at one-year post-surgery follow up. In contrast to our study, a dislocation rate of 1.4% (3/214 patients) was reported by Adam et al.,³¹ in a prospective multicentric study. The DMC has ability to increase the scale of movement before impingement and dislocation, which may be a probable reason for reduced dislocation rates.³² Furthermore, the IPD incidence in newer designs is possibly low due to the polished neck and reduced wearing of the liner at third articulation.³³ However, medical practitioners must be aware of these conditions so that they do not miss dislocation, which may result in extreme metallosis and DMC failure.

In this study, the limiting factor is the short follow up period despite the promising initial results. The short-term results after implantation of DMC as a part of THA in displaced FNF need a longer follow up of 10 years or more

for more validation.

5. Conclusion

Currently cementless dual mobility THA is associated with pain-free, mobile hip with durable acetabular fixation with increased range of movements at the hip. However, appropriate care must be taken about its specific complications, such as intra-prosthetic dislocation. THA with DMC has reduced dislocation rates in FNF, and therefore, may be considered a valuable option for displaced FNF in elderly patients.

6. Source of Funding

None.

7. Conflict of Interest

None.

References

- Burge R, Worley D, Johansen A, Bose U. PAM3: The Cost of Osteoporotic Fractures in The United Kingdom. Value Heal [Internet]; 2001. Available from: <https://linkinghub.elsevier.com/retrieve/pii/S1098301511711627>.
- Burge RT, Worley D, Johansen A, Bhattacharyya S, Bose U. The cost of osteoporotic fractures in the UK: Projections for 2000-2020. *J Med Econ*. 2001;4:51–62.
- Kanis JA, Johansson H, Oden A, Johnell O, Laet CD, Eisman JA, et al. A family history of fracture and fracture risk: A meta-analysis. *Bone*. 2004;35(5):1029–37.
- Mithal A, Kaur P. Osteoporosis in Asia: A call to action. *Curr Osteoporos Rep*. 2012;10:245–7.
- Dhibar D, Gogate Y, Aggarwal S, Garg S, Bhansali A, Bhadada S. Predictors and outcome of fragility hip fracture: A prospective study from North India. *Indian J Endocrinol Metab*. 2019;23(3):282–8.
- Cummings SR, Melton LJ. Osteoporosis I: Epidemiology and outcomes of osteoporotic fractures. *Lancet*. 2002;359(9319):1761–7.
- Bensen AS, Jakobsen T, Krarup N. Dual mobility cup reduces dislocation and re-operation when used to treat displaced femoral neck fractures. *Int Orthop*. 2014;38(6):1241–5.
- Burgers P, Hoogendoorn M, Woensel EAC, Poolman RW, Bhandari M, Patka P. Total medical costs of treating femoral neck fracture patients with hemi- or total hip arthroplasty: a cost analysis of a multicenter prospective study. *Osteoporos Int*. 2016;27(6):1999–2008.
- Gebhard JS, Amstutz HC, Zinar DM, Dorey FJ. A comparison of total hip arthroplasty and hemiarthroplasty for treatment of acute fracture of the femoral neck. *Clin Orthop Relat Res*. 1992;(282):123–31.
- Lee SB, Sugano N, Nakata K, Matsui M, Ohzono K. Comparison between bipolar hemiarthroplasty and THA for osteonecrosis of the femoral head. *Clin Orthop Relat Res*. 2004;(424):161–5. doi:10.1097/01.blo.0000128217.18356.87.
- Grazioli A, Ek ETH, Rüdiger HA. Biomechanical concept and clinical outcome of dual mobility cups. *Int Orthop*. 2012;36(12):2411–8.
- Stroh A, Naziri Q, Johnson AJ, Mont MA. Dual-mobility bearings: A review of the literature. *Expert Rev Med Devices*. 2012;9(1):23–31.
- Harris WH. Traumatic arthritis of the hip after dislocation and acetabular fractures: treatment by mold arthroplasty. An end-result study using a new method of result evaluation. *J Bone Joint Surg Am*. 1969;51(4):737–55.
- Kumar RTV, Gadi D, Pai M, Rao R. Clinoradiological outcome of short segment fusion in thoracolumbar vertebral fractures... A study of 20 cases. *Int J Sci Res*. 2015;4(1):505–9.

15. Dastane M, Dorr LD, Tarwala R, Wan Z. Hip offset in total hip arthroplasty: quantitative measurement with navigation. *Clin Orthop Relat Res.* 2011;469(2):429–36.
16. Moore AT. The self-locking metal hip prosthesis. *J Bone Joint Surg Am.* 1957;39(4):811–27.
17. Moretti VM, Post ZD. Surgical approaches for total hip arthroplasty. *Indian J Orthop.* 2017;51(4):368–76.
18. Ranawat CS, Meftah M, Potter HG, Ranawat AS. The posterior approach in THR: Assuring capsular stability. *Orthopedics.* 2011;34(9):452–5.
19. Vanrusselt J, Vansevenant M, Vanderschueren G, Vanhoenacker F. Postoperative radiograph of the hip arthroplasty: what the radiologist should know. *Insights Imaging.* 2015;6(6):591–600.
20. Lei G, Zeng K, Li K. Short-term follow-up of ribbed anatomic cementless total hip arthroplasty. *Zhongguo Xiu Fu Chong Jian Wai Ke Za Zhi.* 2007;21(3):244–250.
21. Mainard D, Guillemin F, Cuny C, Mejat-Adler E, Galois L, Delagoutte J. Evaluation à un an de la qualité de vie après arthroplastie totale de hanche et de genou [Quality of life assessment one year after total hip or knee arthroplasty]. *Rev Chir Orthop Reparatrice Appar Mot.* 2000;86(5):464–73.
22. Macaulay W, Nellans KW, Garvin KL, Iorio R, Healy WL, Rosenwasser MP. Prospective randomized clinical trial comparing hemiarthroplasty to total hip arthroplasty in the treatment of displaced femoral neck fractures: Winner of the Dorr Award. *J Arthroplasty.* 2008;23(6):2–8.
23. Simian E, Chatellard R, Druon J, Berhouet J, Rosset P. Dual mobility cup in revision total hip arthroplasty: Dislocation rate and survival after 5 years. *Orthop Traumatol Surg Res.* 2015;101(5):577–81.
24. Carulli C, Macera A, Matassi F, Civinini R, Innocenti M. The use of a dual mobility cup in the management of recurrent dislocations of hip hemiarthroplasty. *J Orthop Traumatol.* 2016;17(2):131–6.
25. Duff M, Wisk LE, Amstutz HC. Range of motion after stemmed total hip arthroplasty and hip resurfacing - A clinical study. *Bull NYU Hosp Jt Dis.* 2009;67(2):177–81.
26. Thürig G, Schmitt JW, Slankamenac K, Werner CM. Safety of total hip arthroplasty for femoral neck fractures using the direct anterior approach: a retrospective observational study in 86 elderly patients. *Patient Saf Surg.* 2016;10:12.
27. Fahad S, Khan MZN, Aqueel T, Hashmi P. Comparison of bipolar hemiarthroplasty and total hip arthroplasty with dual mobility cup in the treatment of old active patients with displaced neck of femur fracture: A retrospective cohort study. *Ann Med Surg (Lond).* 2019;45:62–5.
28. Boyer B, Philippot R, Geringer J, Farizon F. Primary total hip arthroplasty with dual mobility socket to prevent dislocation: A 22-year follow-up of 240 hips. *Int Orthop.* 2012;36(3):511–8.
29. Khan M, Valle CJD, Jacofsky DJ, Meneghini RM, Haddad FS. Early postoperative complications after total hip arthroplasty: current strategies for prevention and treatment. *Instr Course Lect.* 2015;64:337–46.
30. Tarasevicius S, Busevicius M, Robertsson O, Wingstrand H. Dual mobility cup reduces dislocation rate after arthroplasty for femoral neck fracture. *BMC Musculoskelet Disord.* 2010;11:175.
31. Adam P, Philippe R, Ehlinger M, Roche O, Bonnet F, Molé DD. Dual mobility cups hip arthroplasty as a treatment for displaced fracture of the femoral neck in the elderly. A prospective, systematic, multicenter study with specific focus on postoperative dislocation. *Orthop Traumatol Surg Res.* 2012;98(3):296–300.
32. Plummer DR, Haughom BD, Valle CJD. Dual mobility in total hip arthroplasty. *Orthop Clin North Am.* 2014;45(1):1–8. doi:10.1016/j.ocl.2013.08.004.
33. Luthra JS, Riyami A, Allami M, K M. Dual mobility total hip replacement in a high risk population. *SICOT J.* 2016;2:43. doi:10.1051/sicotj/2016037.

Author biography

Aubrey Conrad Franco, Resident

Sharath Ramanatha Kittankere, Associate Professor

Naresh Shetty, Senior Professor

Ashok Kumar P, Professor

Rahul P, Assistant Professor

Cite this article: Franco AC, Kittankere SR, Shetty N, Kumar P A, Rahul P. Dual mobility total hip arthroplasty for treatment of displaced fracture neck of femur. *Indian J Orthop Surg* 2021;7(3):246-253.