

Content available at: <https://www.ipinnovative.com/open-access-journals>

Indian Journal of Orthopaedics Surgery

Journal homepage: <https://www.ijos.co.in/>

Original Research Article

A study of titanium elastic nailing in the surgical management of fracture shaft of femur in children

M A Q Ansari¹, Amaan Mahajabeen^{1,*}, Ambreen Fatima¹¹Dept. of Orthopaedics, Khaja Bandanawaz Institute of Medical Sciences, Gulbarga, Karnataka, India

ARTICLE INFO

Article history:

Received 22-07-2021

Accepted 22-07-2021

Available online 26-08-2021

Keywords:

Paediatric fractures

Femur

TENS

Flynn's criteria

ABSTRACT

The most common fractures among long bones are femoral fractures. Femoral shaft fractures account for 1.6% of all paediatric bony injuries. Treatment of long bones fractures in children continues to enhance as newer techniques evolve. Previously most of the fractures were effectively managed conservatively & only unstable and displaced fractures were taken up for fixation. Children in the age group of 5-17 years are treated either with traction, hip Spica, flexible/elastic stable retrograde intramedullary nail, or external fixator.

Objective: To study the outcome of Titanium Elastic Nailing System (TENS) for the treatment of femoral shaft fractures in children.

Materials and Methods: This prospective study was carried out at the Department of Orthopaedics, in our hospital. 30 patients, 5-17 years aged, with fracture shaft of the femur were treated by closed reduction internal fixation with flexible Titanium nailing, followed up clinically and radiologically every 2 weeks upto 2 months, then monthly till bony union and full weight bearing by the patient.

Results: The clinical results were evaluated using Flynn's criteria of scoring as, Excellent in 28 patients (93.33%), Satisfactory in 2 patients (6.67%) and poor in none. Full weight bearing was possible in mean time of 10.1 weeks (range; 7-12 weeks).

Conclusion: CRIF with TENS is very effective in management of paediatric shaft femur fractures in the age group of 5-17 years with advantages of lower rate of infection, early union, early mobilization and good range of movements.

This is an Open Access (OA) journal, and articles are distributed under the terms of the [Creative Commons Attribution-NonCommercial-ShareAlike 4.0 License](https://creativecommons.org/licenses/by-nc-sa/4.0/), which allows others to remix, tweak, and build upon the work non-commercially, as long as appropriate credit is given and the new creations are licensed under the identical terms.

For reprints contact: reprint@ipinnovative.com

1. Introduction

Femoral shaft fractures are among the foremost common major pediatric injuries treated by orthopaedic surgeons. They represent 1-2% of all fractures in the paediatric population males are affected more commonly than females.¹

The treatment has traditionally been age-related, influenced by the location and type of the fracture and associated injuries. Because of rapid healing and spontaneous correction of angulations, most of the femoral

shaft fractures in children are often treated conservatively by immobilization in a Spica cast either immediately or after a period of traction with good long term results.^{2,3}

The various methods of operative stabilization of paediatric femoral shaft fractures include external fixation, compression plating and rigid intramedullary nailing.⁴

These methods were associated with problems and complications like pin tract infections, loss of reduction, refracture after implant removal, growth arrest and avascular necrosis of the capital femoral epiphysis. There is little disagreement regarding the treatment of younger children (usually less than 5 years of age) and adults (>16 years). For children aged between 5 and 16 years, there are

* Corresponding author.

E-mail address: dramaan0915@gmail.com (A. Mahajabeen).

wide varieties of surgical and nonsurgical treatment options available with no clear consensus as to the preferred treatment.⁵

Titanium elastic nailing system (TENS) is a recent technique which allows stable reduction, maintenance of reduction and early mobilization.⁶

2. Materials and Methods

Children (5-17 years) with femoral shaft fractures admitted a tour hospital. Sample size was 30 cases.

The inclusion criteria was Simple femoral shaft fractures and Type I and II open fractures with ages between 5-17years, either sex. The exclusion criteria was Type III open fractures, metaphyseal fractures and all the factors contraindicated for this procedure. In this study, 30 cases of femoral shaft fractures in children admitted in the orthopedic department were selected. Through clinical history was taken including age, sex, personal, past history. Routine Blood investigations were done including CBC, RBS, Serum Bilirubin, HIV, HBSAg, BT, CT, PT. X-rays Pre-operative, post-operative and at follow up were taken.

All patients were primarily immobilized with Thomas splint. Pre-operative x rays were taken as follows - X ray full length femur AP view and Lateral view. Anesthesia fitness taken and patient was posted for surgery. The diameter of the nail was assessed preoperatively on radiographs taking the nail diameter as 40% of the isthmus (narrowest part of the medullary canal). The size of flexible nail should be approximately 40% of the diameter of the femoral canal at its most narrow point. A systemic antibiotic, usually a third generation cephalosporin was administered just before induction of patients by anaesthetists. The surgery was performed with the patient under general anaesthesia. The position of the patient is supine on the fracture table with a traction boot and the c -arm was so adjusted that anteroposterior and lateral views of the injured femur would be obtained intraoperatively. The standard technique of titanium elastic nailing in femur is Retrograde (ascending). Perineal post was well padded to avoid any injury to the nearby structures. Image intensifier was used to locate the position of skin incision and for creating entry hole within the metaphysis. The entry point was 2.5-3 cm above the physis. The entry points were at an equivalent level both medially and laterally. Two longitudinal incisions were made on the lateral and medial aspect of the distal femur, starting 3 cm above the physis and extending distally for 2.5 cm. Fascia was dissected along the line of incision and blunt dissection was carried out till the periosteum was reached. Medullary canal was opened using an awl or drill bit.

The next largest drill bit size relative to the diameter of nail was selected. The drill bit was started perpendicular to the bone surface, then slowly angulated to 45° in relation to axis of shaft and 10° anteriorly. Then the drill bit was advanced at this angle until it reached the

medullary canal. The two nails of an equivalent diameter were selected in order that the bending forces are equal, avoiding malalignment. The proper nail diameter shouldn't be over forty percent (40%) of the width of the canal. Hence both the nails of equal size should be filling 80% of the isthmus region of the medullary canal. The opening was made slightly larger than the selected nail diameter. The traumatic tip is formed as a skip, which guarantees better gliding inside the cortex. Two Titanium nails of the same size were inserted in all cases. Both nails were inserted about 2 cm proximal to distal femoral physis from medial and lateral sides. Lateral nail was directed till it was within 2 cm of proximal femoral capital physis whereas medial nail was inserted till it was about 1 cm from greater trochanteric physis. Diameter of individual nail was selected as per Flynn et al's formula (Diameter of nail= Width of the narrowest point of medullary canal on Antero posterior and Lateral view x 0.4mm). All titanium nails were bent at insertion site and cut near to bone leaving 1.5-2cm of nail protruding for later easy removal.

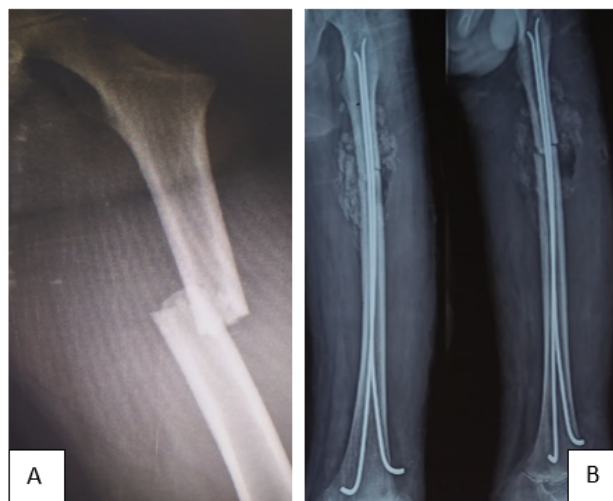


Fig. 1: A: Pre-operative showing fracture shaft of left femur; **B:** Post-operative image taken on 6 weeks showing callus formation and uniting fracture shaft of femur

Average operative time for this procedure was 1hour. Post-operative X-ray femur full length taken in AP and Lateral view. On the 1st or 2nd postoperative day, patients were started on static quadriceps and knee bending exercises. After discharge, patients were called for follow-up after every 2 weeks up to two months and subsequently at monthly intervals. Patients were assessed clinically and radiologically at each follow-up. Time of weight bearing was individualized depending on fracture pattern, stability of reduction and rigidity of fixation. The final results were evaluated using criteria by Flynn et al.⁷ All patients were immobilized for 6 weeks in Thomas splint. Intravenous antibiotics and analgesics given. Static quadriceps and Static

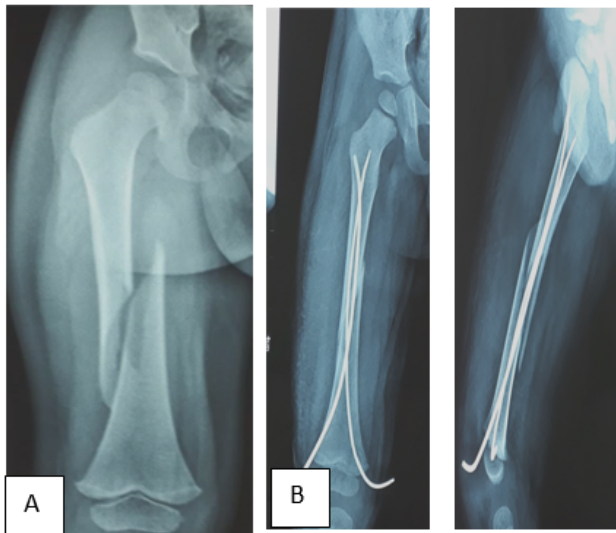


Fig. 2: **A:** Pre-operative showing fracture shaft of femur; **B:** Post-operative image taken on 9 weeks showing union

hamstrings exercises started from 2nd post-operative day.

After 6 weeks Thomas splint was removed and active and passive hip, knee and ankle range of movements were started and non-weight bearing started with the help of walker. Serial radiographs taken at 6 weeks, 12 weeks, 24 weeks. Full weight bearing was allowed once radiographic and clinical union was achieved. The functional outcome was assessed using Flynn’s scoring criteria. The duration of follow up was up to 24 months. Nail removal was usually done at 7-9 months post op after fracture union.

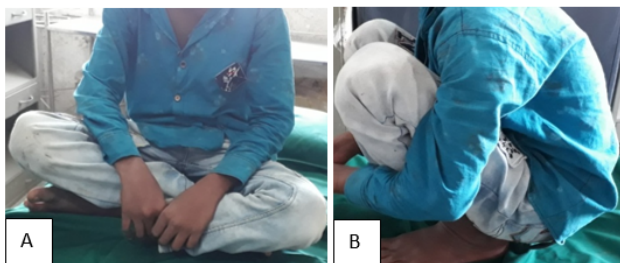

Fig. 3: **A:** Post-operative Image After 8 weeks patient in cross leg position; **B:** Post-operative image after 8 weeks patient in squatting position

3. Results

In the present study we included 30 cases treated with titanium elastic nailing system. All the femoral shaft fractures were stabilized with two titanium elastic nails of same diameter. Length of nail was 45 cm, which was cut to required length accordingly during surgery. The diameter of nail chosen varied from 2 - 5 mm.

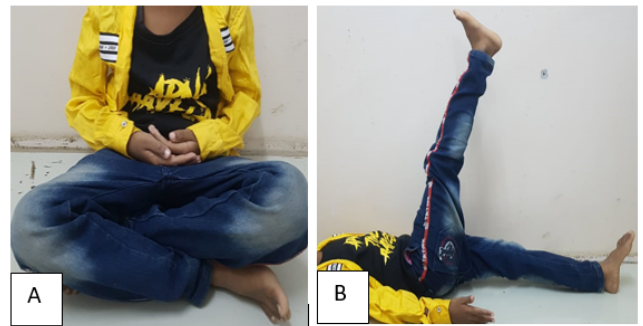

Fig. 4: **A:** Post-operative image taken at 7 weeks with patient in cross leg position; **B:** Post-operative Image taken at 7 weeks with patient in straight leg position

In the present study age distribution was from 5-17 years. Majority of the patients i.e. 56.67% (17/30) were in the age group of 9-12 years, followed by 30% (09/30) patients in 5-8 years and 13.33% (04/30) were among 13-17 years.

The youngest patient was 05 years and oldest patient was 17 years. The mean age in our study was 9.8 years. According to gender distribution males were predominant i.e. 73.3% (22/30) as compared to females is 26.6% (08/30). Male: Female ratio was 2.7:1.

Table 1: Functional outcome according to flynn score criteria

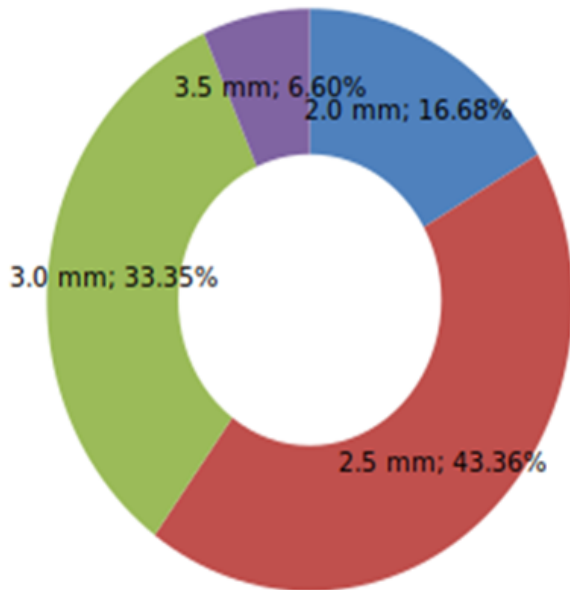
Clinical outcome	No of patients	%
Excellent	28	93.33%
Satisfactory	02	6.67%
Poor	-	-
Total	30	100%

Fall from Height was the major cause of femur fracture in children i.e. 76.67% (23/30). Road traffic Accident (RTA) constituted 13.33% (04/30) and only 10% (03/30) due to fall while playing. Right femur was involved in 53.33% (16/30) cases and left femur in 46.67 (14/30) cases. 50% (15/30) were oblique fractures, 36.67% (11/30) were transverse fractures, and 13.33% (04/30) were spiral fractures. 93.33% (28/30) were closed fracture and 6.67% (02/30) were open fracture. 73.33% (22/30) cases were operated between 2 to 4 days and 26.67% (08/30) cases were operated between 5-7 days. Closed reduction was done on 93.33% (28/30) cases and 6.67% (02/30) cases by Open Reduction.

Nail diameter which was calculated by Flynn et al formula 43.33% (13/30) cases were treated with 2.5mm nails. In 33.33% cases (10/30) 3mm nails were used, 16.67% (05/30) cases were treated with 2mm nails, 6.67% (02/30) of cases were treated with 3.5mm nails as seen in Figure 1. 53.33% (16/30) patients stayed about 6-9 days, 26.67% (08/30) patients stayed for 10-12 days and 20% (08/30) patients stayed for more than 12 days in hospital. Average stay in hospital was 9.4 days.

Table 2: Showing comparative studies related to flynn's scoring criteria

Clinical outcome	Bagul Rahul et al study (n=30)	Mohit Khanna et al study (n=45)	Avinash Pulateet al study (n=20)	Present study (n=30)
Excellent	27(90%)	40 (88.8%)	12(60%)	28(93.3%)
Satisfactory	03(10%)	05(11.1%)	07(35%)	02(6.6%)
Poor	-	-	01(5%)	-

**Fig. 5:** Showing 2.5mm nail was most commonly used compare to 3.55mm nail in our study

Time to union ranged from 8 to 12 weeks. Time for union of 10 weeks duration was noted in 73.33% (22/30) cases. In 10% (03/30) cases it was 08 weeks and 16.67% (05/30) cases it was 12 weeks. Average union time was 10.1 weeks.

According to Flynn score criteria, excellent clinical outcome was noted in 93.33% (28/30) cases and 6.67% cases (02/30) showed satisfactory outcome. Short term complications were noted in 17 cases which included: Knee stiffness in 03 cases (10%) and reduced after 3 weeks of physiotherapy. Thigh pain was noted in 04 cases (13.3%) and were treated with analgesics. Nail impingement was seen in 13.3% (04/30) cases and were treated with analgesics and early removal of nail. Malunion were noted in 01 case (3.3%) in a 12 year old male.

4. Discussion

Paediatric trauma represents a great opportunity for positive impact on paediatric healthcare. Management of paediatric long bone fractures presents special challenges to the orthopaedic surgeons owing to smaller size, the presence of Open physis and immature vascular pattern.

Spica cast immobilization and casting resulted in limb length discrepancy, angulations, rotational deformity and

economical complications.⁸ Solid antegrade intramedullary nailing had resulted in avascular necrosis of the femoral head, trochanteric epiphysiodesis and coxa valga.⁹

TENS nailing limit the amount of permanent deformation, as they are elastic, biocompatible and promote healing by limiting stress shielding and no metal sensitivity reactions are observed.¹⁰ Literature suggests there were excellent union rates in TENS nailing of paediatric femoral shaft fractures.¹¹

It aims to develop early bridging callus and contributes to rapid restoration of bone continuity. Titanium elastic nail is advantageous over other surgical methods particularly in 5-14 years age group because it is a simple, is a load sharing internal splint that doesn't violate open physis, allows early mobilization and maintains alignment. Titanium elastic nailing system (TENS) works on the basic principle of three-point fixation —providing flexible, axial, translational and rotational stability.

Micro-motion conferred by the elasticity of the fixation promotes faster external bridging callus formation. The periosteum is not disturbed and being a closed procedure there is no disturbance of fracture hematoma, there by less risk of infection.¹²

Titanium Elastic Nailing System (TENS), as a surgical procedure in paediatric femoral shaft fractures has various advantages such as early union due to repeated micro motion at the fracture site which promotes callus formation, less chance of physeal damage, early mobilization, early weight bearing, small scar, less injury to the encompassing soft tissue, better patient compliance, simple removal and high patient satisfaction.¹³

All children achieved union in a mean time of 10.1 weeks This was in similar findings with Bagul Rahul R et al.¹⁴ study where mean duration of union was 10 weeks. Where as in the study conducted by Vishal Kumar Mishra et al.¹⁵ mean duration of union was 8.2 weeks.

Patients had full range of hip and knee motion except in one patient who had knee stiffness and treated by physiotherapy. Similar findings were noted in the studies conducted by different authors. Vishal Kumar Mishra et al¹⁵ study all patient has full range of movement at 24 weeks. Kanthimathi et al¹⁶ in his study all 25 patient had full range of motion.

Whereas Flynn J M et al.¹⁷ reported 2 cases of knee stiffness, which required manipulation under general anaesthesia.

According to Flynn's score criteria results were Excellent 93.3% (28/30) cases and satisfactory outcome in 6.6% cases (02/30) in our study. Our study had similar findings when compared to Bagul Rahul et al¹³ & Mohit Khanna et al¹⁸ study. Whereas Avinash Pulate et al¹⁹ had noted poor outcome in one case.

Complications such as knee stiffness in 03 cases (10%) & Nail impingement was seen in 13.3% (04/30) cases. In Saurabh Gupta et al²⁰ study 70% Shaft fractures cases had no complications, only 20% had Irritation at entry site, 5% had Infection and proximal nail migration. In DiveshJalan et al²¹ study the most common complication encountered was soft tissue irritation at the nail entry site seen in 6 cases.

There was no limb length discrepancy. Where as in Vishal Kumar Mishra et al¹⁵ study in 82.5% cases no limb length discrepancy. But limb lengthening as noted in 04 cases (10%) and < 1cm shortening were in 3 cases (7.5%). In DiveshJalan et al.²¹ study lengthening was noticed in 4 (13.33%) cases, while no patient had shortening.

No patient had varus/valgus angulations, anterior and posterior angulations and rotational malalignment. Malunion was noted in 01 case (3.3%). Flynn et al.²² reported 10 (4.3%) cases of minor angulations out of 234 fractures treated with titanium elastic nails.

Singh et al.²³ reported angulations in both anteroposterior and varus/valgus planes was seen in two cases and one case, in which two different diameter nails had to be used, had posterior bowing of 10° and 10° of varus tilt.

5. Conclusion

TENS (Titanium Elastic Nailing System) has distinct advantages in terms of short operative time, short duration of hospital stay, fracture stability, early mobilization, early union, and early return to function, reasonable bone healing time, good range of movements of knee, good functional outcome and low incidence of complications.

Our study results show that CRIF with Titanium Elastic Nailing is effective with advantages of lower rates of infection, early union, early mobilization and can be used successfully regardless of fracture location and fracture pattern. The indication for TENS in paediatric femoral fractures are expanding as their advantages are realized and complications of the operative methods of stabilization are reported.

Titanium Elastic Nailing System is a simple, easy minimal invasive procedure appears to be safe and reliable method, which has good long term results in the treatment of paediatric shaft fractures of long bones in children aged 5-17 years.

6. Source of Funding

None.

7. Conflict of Interest

The author declares no conflict of interest.


References

- Loder RT, O'Connell PW, Finberg JR. Epidemiology and mechanism of femur fracture in children. *J Pediatr Orthop.* 2006;26(5):561–6.
- Irani RN, Nicholson JT, Chung SMK. Long-term results in the treatment of femoral-shaft fractures in young children by immediate spica immobilisation. *J Bone Joint Surg Am.* 1976;58:945–51.
- Henderson OL, Morrissy RT, Gerdes MH, McCarthy RE. Early casting of femoral shaft fractures in children. *J Pediatr Orthop.* 1984;4:16–21.
- Skak SV, Overgaard S, Nielsen JD, Andersen A, Nielsen ST. Internal fixation of femoral shaft fractures in children and adolescents: Ten to twenty one year follow up of 52 fractures. *J Pediatr Orthop.* 1996;5:195–9.
- Clinkscales CM, Peterson HA. Isolated closed diaphyseal fractures of the femur in children: comparison of effectiveness and cost of several treatment methods. *Orthopaedics.* 1997;20:1131–6.
- Hedin H. Surgical treatment of femoral fractures in children Comparison between external fixation and elastic intramedullary nails: A review. *Acta Orthop Scand.* 2004;75(3):231–40.
- Flynn JM, Hresko T, Reynolds RA, Blasler RD, Davidson R, Kasser J. Titanium elastic nails for pediatric femur fractures: a multicenter study of early results with analysis of complications. *J Pediatr Orthop.* 2001;21(1):4–8.
- Martinez AG, Carroll NC, Sarwark JF. Femoral shaft fractures in children treated with early spica cast. *J Pediatr Orthop.* 1991;11:712–6.
- Beatty JH, Austin SM, Warner WC. Interlocking intramedullary nailing of femoral shaft fractures in adolescence: preliminary results and complications. *J Pediatr Orthop.* 1994;14:178–83.
- Ligier JN, Metaizeau JP, Prevot J, Lascombes P. Elastic stable intramedullary nailing of femoral shaft fractures in children. *J Bone Joint Surg.* 1988;70:74–7.
- Kanthimathi B, Kumar A. Flexible Intramedullary Nailing for Paediatric Shaft of Femur Fractures-Does the Number of Nails Alter the Outcome. *Malays Orthop J.* 2011;5(2):28–33.
- Gwyn DT, Olney BW, Dart BR, Czuwala PJ. Rotational control of various pediatric femur fractures stabilized with titanium elastic intramedullary nails. *J Pediatric Orthop.* 2004;24(2):172–9.
- Flynn JM, Skaggs DL, Sponseller PD. The operative management of pediatric fractures of the lower extremity. *J Bone Joint Surg Am.* 2002;84(12):2288–300.
- Rahul BR, Basavaraj SS, Pramod PN, Sanjay DS, Vivek P, Swaroop SS. Surgical management of fracture shaft femur in children and adolescents with titanium elastic nailing system. *Int J Orthop Sci.* 2017;3(4):330–5.
- Mishra VK, Kumar A, Kumar GS, Sarang S. Functional Outcome Of Fracture Shaft of Femur In Pediatric Age Group Treated With Titanium Elastic Nailing System. *Int J Med Biomed Stud.* 2020;4(1):175–9.
- Kanthimathi B, Kumar A. Flexible Intramedullary Nailing for Paediatric Shaft of Femur Fractures-Does the Number of Nails Alter the Outcome. *Malays Orthop J.* 2011;5(2):28–33.
- Flynn JM, Skaggs D, Waters P. Femoral shaft fractures. In: Flynn JM, Skaggs D, Waters P, editors. *Rockwood & Wilkins' Fractures in Children.* Philadelphia: Wolters Kluwer; 2014. p. 987–1026.
- Khanna M, Jitendrawadhvani A, Batra. Tens For The Surgical Management Of Femoral Shaft Fractures In 6-14 Years Age Group Children."Pediatric Traumatology. *Orthopaedics and Reconstructive Surgery.* 2017;5.
- Pulate A, Jadhav A, Binoy N. Titanium elastic nailing in pediatric femoral diaphyseal fractures in the age group of 5–16 years – A short term study. *J Int Med Res.* 2018;46(1):440–7.

20. Gupta S, Hegde J. Prospective Study of Management of Diaphyseal Fractures of Femur in Paediatric Age Group by Titanium Elastic Nailing System. *J Med Thesis*. 2014;2(1):19–23.
21. Divesh J, Rajesh C, Sharma VK. Results of titanium elastic nailing in paediatric femoral diaphyseal fractures-report of 30 cases. *Chin J Traumatol*. 2013;16(2):77–83.
22. Flynn JM, Luedtke LM, Theodore J. Comparison of titanium elastic nails with traction and a spica cast to treat femoral fractures in children. *J Bone Joint Surg Am*. 2004;86(4):770–7.
23. Singh J, Virk JS, Anoopkalia, Mittal N. Flexible intramedullary nails: the panacea for paediatric femoral shaft fractures. *Int J Res Orthop*. 2017;3:411–6.

Author biography

M A Q Ansari, Professor

Amaan Mahajabeen, Junior Resident  <https://orcid.org/0000-0002-4310-9220>

Ambreen Fatima, Junior Resident

Cite this article: Ansari MAQ, Mahajabeen A, Fatima A. A study of titanium elastic nailing in the surgical management of fracture shaft of femur in children. *Indian J Orthop Surg* 2021;7(3):227-232.