

Content available at: <https://www.ipinnovative.com/open-access-journals>

Indian Journal of Pathology and Oncology

Journal homepage: www.ijpo.co.in

Case Report

Neuroendocrine carcinoma admixed adenocarcinoma of cervix: A case report of young female

Lal Chand Mittal ^{1,*}¹Sawai Mansingh Medical College, Jaipur, Rajasthan, India

ARTICLE INFO

Article history:

Received 22-07-2021

Accepted 19-08-2021

Available online 23-11-2021

Keywords:

Neuroendocrine carcinoma

Adenocarcinoma cervix

Immunohistochemical

ABSTRACT

Neuroendocrine carcinoma coexisted with adenocarcinoma in cervix is very rare. This disease has a very poor prognosis and so far no standard treatment has been obtained. A 35-years-old woman seeks medical attention with chief complaint of bleeding per vagina outside of menstruation. Ultrasound shows cervical mass of 4.2 cm × 2.9 cm. Microscopic biopsy suggestive of a mixture of neuroendocrine cervical carcinoma and adenocarcinoma, moderate-poor differentiation. Several immunohistochemical staining of the biopsy tissue was done to detect neuroendocrine and adenocarcinoma. In biopsy tissue, P63 immunohistochemical staining was performed to detect squamous cell carcinoma with negative results. Furthermore chromogranin, synaptophysin, CD 56, NSE, and P40 immunohistochemical staining were performed to detect neuroendocrine with positive results and so did CK 19, CEA, and CK 7 staining to detect positive adenocarcinomas. This rare case had a positive immunohistochemical staining of both neuroendocrine carcinoma and adenocarcinoma cervix. Patient received definitive concurrent chemoradiotherapy.

This is an Open Access (OA) journal, and articles are distributed under the terms of the [Creative Commons Attribution-NonCommercial-ShareAlike 4.0 License](https://creativecommons.org/licenses/by-nc-sa/4.0/), which allows others to remix, tweak, and build upon the work non-commercially, as long as appropriate credit is given and the new creations are licensed under the identical terms.

For reprints contact: reprint@ipinnovative.com

1. Introduction

A mixture of neuroendocrine carcinoma and adenocarcinoma in the cervix is a tumor that has characteristics of neuroendocrine differentiation and cervical adenocarcinoma, this disease is very rare. Neuroendocrine tumors in the cervix can arise from neuroendocrine granule cells that are normally present in the cervix or from the cervical reserve/stem cells. There are 4 classifications of this type of tumor, namely typical carcinoid tumors, atypical carcinoid tumors, small cell carcinomas, and large cell carcinomas.¹ Small cell carcinoma types are more common than other types, which is around 2% to 5% of all cervical cancers.² Some studies state that only 4% of small cell carcinomas are coexistent with adenocarcinoma.³ This type of tumor has a

poor prognosis and so far no standard treatment has been obtained for this type of tumor.⁴

2. Case Presentation

A 35-years-old woman presented with chief complaint of bleeding outside of menstruation. This bleeding persisted as from the last year accompanied by discomfort in the lower abdomen. Patients also experience vaginal discharge accompanied by blood since the last 6 months. Patient had history of using 6-month oral contraception.

The physical examination showed an exophytic mass of 4 cm diameter in the portio of cervix. Ultrasound shows enlarged portio with a mass of 4.2 cm × 2.9cm. Temporary diagnosis of this patient is cervical Ca stage II and recommended for biopsy of the cervix. Microscopic biopsy results showed invasive epithelial malignant tumor into the connective tissue formed mostly solid structures,

* Corresponding author.

E-mail address: drlmittal@gmail.com (L. C. Mittal).

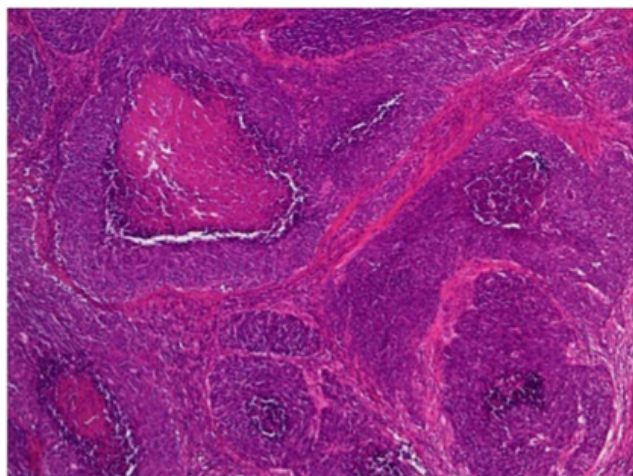


Fig. 1: Histological finding of surgical biopsy of cervical tumor (H& E stain, original magnification X 40). Relatively large tumor cell invasively proliferate with organoid nesting pattern and central necrosis

sheets, papillaries, and few form glands and cribriform structures (Figure 1).

Relatively large tumor cells which shows invasively proliferate with organoid nesting pattern and central necrosis. Immunohistochemical staining of the biopsy tissue was done by staining Chromogranin, synaptophysin, CD 56, NCAM, P40, p63 and Ki 67 to detect neuroendocrine carcinoma (Figure 2) In biopsy tissue, P63 immunohistochemical staining was negative result and chromogranin, synaptophysin, CD 56, NCAM were positive result. In biopsy tissue, P40 immunohistochemical staining was positive result and so did CK 19, CEA, and CK 7 staining to detect positive for confirming adenocarcinomas. Patient treated with concurrent chemoradiotherapy but outcome not so well. Furthermore, that patient received palliative chemotherapy for residual mass along with symptomatic management.

3. Discussion

I report a very rare case, a mixture of neuroendocrine carcinoma and adenocarcinoma of the cervix. Patient had clinical manifestations of bleeding outside the menstrual cycle accompanied by vaginal discharge and discomfort in the hip. This is consistent with the theory that states that tumors with small and large cell neuroendocrine carcinoma components have manifestation of vaginal bleeding, cervical mass, and/or abnormal cervical cytology. In biopsy tissue, P63 immunohistochemical staining was performed to detect squamous cell carcinoma with negative results. This was done to eliminate the diagnosis of squamous cell carcinoma. Usually, more frequent cases founded were squamous cell carcinoma or a mixture of squamous cell carcinoma with adenocarcinoma (adenosquamous carcinoma). Furthermore chromogranin, synaptophysin,

CD 56, NSE, and P40 immunohistochemical staining were performed to detect neuroendocrine with positive results and so did CK 19, CEA, and CK 7 staining to detect positive adenocarcinomas. This shows that this tissue is indeed a mixed case between neuroendocrine carcinoma and adenocarcinoma in cervix. In biopsy tissue, a mixture of neuroendocrine carcinoma and adenocarcinoma is suspected, immunohistochemical staining should also be done to detect adeno-squamous carcinoma. So that patient could get appropriate management and prognosis.

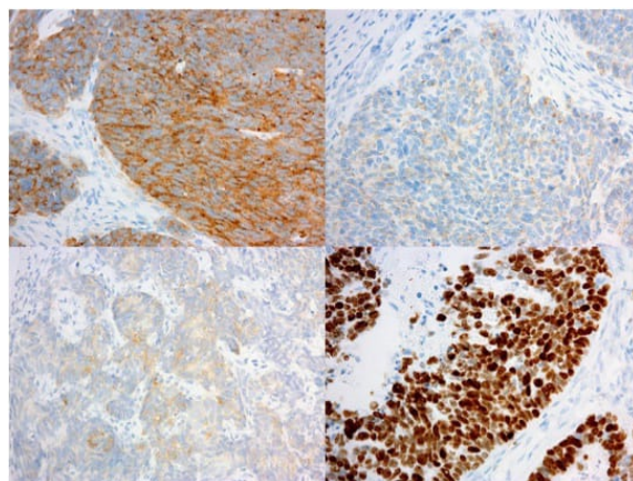


Fig. 2: Immunohistochemical findings of surgical specimen of cervical tumor (immunohistochemistry, original magnification \times 100). Immunohistochemical staining of the tumor was strongly positive for synaptophysin (upper left), weakly positive for chromogranin- A (upper right) and partially positive for NCAM (bottom left). The Ki-67 index of the tumor cells was almost 100% (bottom right)

4. Conclusion

This case is a mixture of neuroendocrine carcinoma and adenocarcinoma in cervix due to the positive markers supporting the carcinoma.

5. Source of Funding

None.

6. Conflict of Interest


None.

References

1. Kefeli M, Usubutun A. An update of neuroendocrine tumors of the female reproductive system. *Turk Patoloji Derg.* 2015;31(1):128–44.
2. Nishiumi Y, Nishimura T, Kashu I, Aoki T, Itoh R, Tsuta K. Adenocarcinoma in situ admixed with small cell neuroendocrine carcinoma of the cervix: A case report with cytological features. *Diagn Cytopathol.* 2018;46(9):752–5.

3. Toki T, Katayama Y, Motoyama T. Small-cell neuroendocrine carcinoma of the uterine cervix associated with micro-invasive squamous cell carcinoma and adenocarcinoma in situ. *Pathol Int.* 1996;46:520–5.
4. Ramalingam P, Malpica A, Deavers MT. Mixed endocervical adenocarcinoma and high-grade neuroendocrine carcinoma of the cervix with ovarian metastasis of the former component: A report of 2 cases. *Int J Gynecol Pathol.* 2012;31(5):490–6.

Author biography

Lal Chand Mittal, Assistant Professor  <https://orcid.org/0000-0002-8198-5280>

Cite this article: Mittal LC. Neuroendocrine carcinoma admixed adenocarcinoma of cervix: A case report of young female. *Indian J Pathol Oncol* 2021;8(4):500-502.