

Content available at: <https://www.ipinnovative.com/open-access-journals>

Indian Journal of Microbiology Research

Journal homepage: <https://www.ijmronline.org/>

Original Research Article

Emerging cases of mucormycosis in post Covid-19 disease patients

Sonu S Ahirwar^{1,*}¹Dept. of Lab Medicine, Vishesh Jupiter Hospital, Indore, Madhya Pradesh, India

ARTICLE INFO

Article history:

Received 06-09-2021

Accepted 08-09-2021

Available online 22-09-2021

Keywords:

Mucormycosis

Immunocompromised

Diagnosis

Covid-19

ABSTRACT

Purpose: Mucormycosis (MC) is a serious threat in this covid-19 pandemic situation; cases of MC continue to increase as post covid-19 disease affliction in India. It is a life-threatening disease that happens due to black mold. Mucormycosis is described as a potentially lethal infection amongst immune-compromised (IC) hosts, particularly in those with diabetes, leukemia, and lymphoma. Mortality rate of MC just doubles in IC host, delayed diagnosis increase the rate of mortality. Mucormycosis is difficult to diagnose which affects outcomes and results in a poor prognosis. The main objective of the study was to detect MC in the clinical species received during or post covid-19 treatment in our laboratory.

Materials and Methods: Basic microbiological methods such as gram stain and KOH smear were used for the detection of MC in the received clinical specimen and morphology was seen in the microscope.

Results: This is a cross-sectional observational study conducted in our microbiology laboratory for one month periods during May 15, 2021 to June 15, 2021 in a tertiary care hospital of central India. During study period our microbiology lab received n=35 suspected clinical specimens from N= 27 post covid-19 patients for MC diagnosis over one month period. Out of n=35 specimens, n=8 specimens (obtained from N=5 patients) were positive for MC by gram and KOH smear method and we saw filamentous fungi by conventional microscopic method.

Conclusions: The present study concluded that the cases of life threatening MC increase day by day in central India as post complication of covid-19 disease.

This is an Open Access (OA) journal, and articles are distributed under the terms of the [Creative Commons Attribution-NonCommercial-ShareAlike 4.0 License](https://creativecommons.org/licenses/by-nc-sa/4.0/), which allows others to remix, tweak, and build upon the work non-commercially, as long as appropriate credit is given and the new creations are licensed under the identical terms.

For reprints contact: reprint@ipinnovative.com

1. Introduction

The novel corona-virus 2019 (nCoV-2019) or Severe Acute Respiratory Syndrome Coronavirus-2 (SARS-CoV-2) was an outbreak from Wuhan, China in 2019 and spread rapidly on a global platform forming a global pandemic.^{1,2} Over one year of the outbreak and despite great efforts, there is no standard treatment of the disease. The covid-19 disease causes a range of mild to deadly pneumonia with association of other bacterial, viral and fungal co-infection.² Long hospital stay promotes secondary infections in the covid-19 patients and the immune-

compromised patients are more prone to develop severe opportunistic infections.^{3,4} The previous study suggests that fungal infection in hospitalized Covid19 patients is more common than others,⁵⁻⁷ as the nature of the disease is still mysterious, it can't be confirmed if it's a complication of the disease or its management.

Mucormycosis is a rare but severe fungal infection caused by the Mucorales species of phylum Zygomycota. Naturally, Mucorales occur in soil, their spores spread by air often contaminate foods, water, and clinical specimens. The *Mucor* sp., *Rhizopus* sp., *Asidia* and *Cunninghamella* are the main causative agent for MC in humans.^{3,8} Mucormycosis described as a potentially lethal infection amongst immune-compromised hosts, particularly

* Corresponding author.

E-mail address: ahirwarsonu822@gmail.com (S. S. Ahirwar).

in those with diabetes, leukemia, and lymphoma.⁹ During the fungal infection thrombosis and tissue necrosis are the major symptoms and require antifungal drug therapy and surgery to help remove the infected tissues. In this Covid19 era, the rate of MC cases rapidly growing in the Covid19 patients in India. Mucormycosis is difficult to diagnose which affects outcomes and results in a poor prognosis. Delay in diagnosis increase the mortality rate by about 35-66%.^{4,10}

2. Materials and Methods

A cross-sectional observational study conducted in a tertiary care hospital for two months period from 15, April 2021 to June 2021. The demographic details and clinical diagnosis were recorded from medical records. During the study period, our microbiology laboratory received various specimens such as nasal swabs, ET secretion, sputum, and tissues from our IPD departments such as ICU, and Covid19 ward for the detection of fungal infection in the specimens. Patients admitted in our hospital with a history of fever, cough, body ache and shortness of breath for 4-5 days with have positive report of nasopharyngeal/ oropharyngeal swab for covid19 RT-PCR were included in the present study. Wound swabs were rejected. If the specimens were transported to the laboratory in a sterile container and swabs, the aspirates were immediately performed direct microscopy, KOH smear preparation and gram's stain. Identification was done on the basis of morphology in the microscopy. Statistical analysis (Mean, % Value etc.) was done using MS excel 2013.

3. Observation & Results

Total of n=35 suspected sputum; nasal swab and BAL samples from N=27 of participants were received in our microbiology laboratory during study period. Age, sex and other demography details were collected before sample collection, the average age of the participants was 62.4 ± 9.4 years and the majority of participants were male (77.7%). Although, 44.4% participants belong to 41-60 year age and 55.6% of participant belongs to 61-80 year age (Table 1).

Out of N= 27 participants, 90.4% males and 66.6% of females had a history of autoimmune disease; all the participants had a conformed RT-PCR positive report for Covid-19. Moreover, all the participants had a history of long hospital stay during the treatment of covid19, the average hospital stay of all the participants were about 17 days (Table 2).

Moreover, our microbiology laboratory received multiple samples (sputum + nasal swab and BAL secretion from the same participants) from the five participants (Table 2). Out of n=35 specimens, total 8 specimen found positive for fungal smear i.e. n=5 sputum, n=3 nasal swabs and n=0 BAL specimens (Table 3). Positive report for fungal smear

were informed immediately to concern clinician.

Received specimens directly examine by microbiologist before acceptance in the microbiology laboratory and further processed for fungal detection. Fungal smear (KOH wet mount) and gram staining perform for morphological analysis Figure 1.

4. Discussion

Although India has not been able to actively control and limit the second wave of COVID-19, the number of new cases is now in decline. Despite this, emerging complications associated with COVID-19 are being reported with the fungal infection mucormycosis becoming a serious issue in India due to its unprecedented surge and high morbidity.^{4,10,11}

The term MC collectively known “black mold” or “black fungus” in India is a fungal infection caused by the order of mucorales. Order: Mucorales is the group of the filamentous fungus, comprises about 20 pathogenic species which are further divided into 12 genera.⁸ The genera of Mucorales are one of the best decomposers of organic materials and are often found in decaying organic materials such as rooted fruits and vegetables, plant litter, and animal manure.¹² The *Mucor* sp., *Rhizopus* sp., *Asidia* and *Cunninghamella* are the main causative agent for MC in humans.¹³ Spores of the mucorales are highly prevalent in the air. Patients acquire the infection by inhalation, ingestion or traumatic inoculation of the spores from the environment.¹⁴ Other than environmental factors, uncontrolled diabetes mellitus, inappropriate steroid therapy, increased iron accumulation, and the damage caused by the COVID-19 virus may responsible for the MC.^{4,11,15}

In our study we reported MC in N=5 participants who were long stayed in hospital on oxygen support. All the MC positive participants belong to >60 years age and all had a weakened immune system. Mortality rate of MC is very high, early diagnosis is very essential to reduce the sever morbidity and mortality of patients.¹⁶ The standard approaches for the treatment of MC are usually based on the combination of antifungal therapy and surgical removal of involved tissues.¹⁷

5. Conclusion

Mucormycosis is serious threats in this covid-19 pandemic situation; cases of MC continue to increase in post covid-19 disease patients in India. It is a life-threatening disease that happens due to black mold. Now, we are still learning more about the new and long-term manifestations of the Covid-19 infection. The MC occurring in the post Covid-19 patients are a secondary infection and directly linked with the virus, poor glycemia control, widespread use of corticosteroids, and invasive ventilation. Therefore, early screening and diagnosis are much-needed to prevent is a life-threatening

Table 1: Demographic profile of participants (N=27)

Characteristics	No. of participants	(%)
Age (in years)		
21-40	00	00%
41-60	12	44.4%
61-80	15	55.6%
Gender		
Male	21	77.7%
Female	06	22.3%
Past history of Disease (Immuno-compromised)		
Male	19	90.4%
Female	04	66.6%
Positive RT-PCR report of nasopharyngeal/ oropharyngeal swab for covid19		
Male	21	100%
Female	06	100%
Total stay in hospital (in days) N=27		
10-20 days	17	63.0%
> 20 days	10	37.0%
Type of specimens (n=35)		
Sputum	18	51.4%
Nasal swab	11	31.4%
BAL	6	17.2%

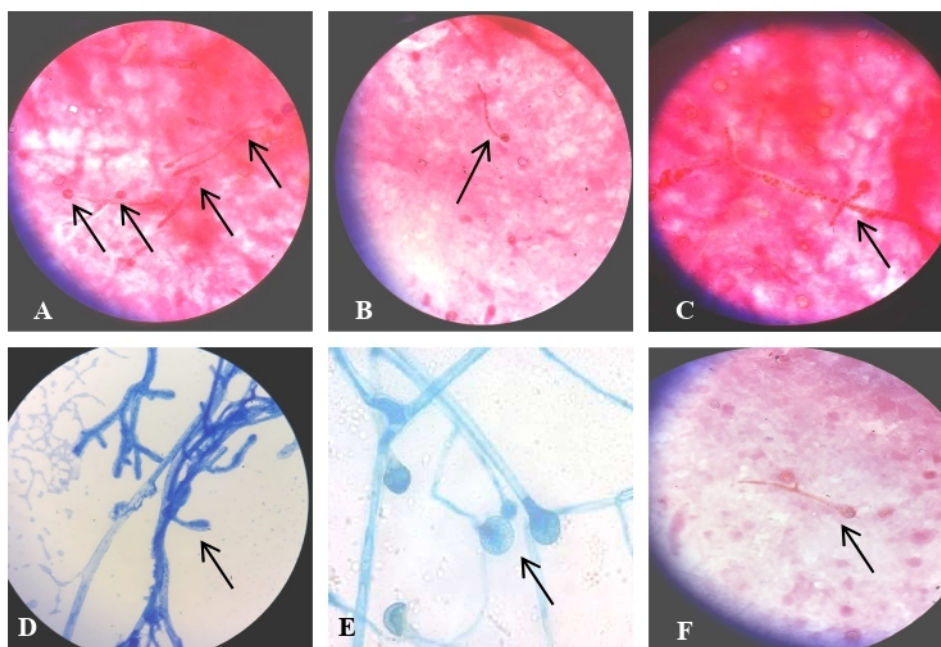
Table 2: Distribution of Participants (N = 27) and specimens (n = 35)

Participants ID	Age (Y)	Gender (M/F)	Types of specimen		
			Sputum (n =18)	Nasal swab (n=11)	BAL (n =6)
M-01	46*	M	√	×	√
M-02	58*	M	×	√	×
M-03	67	F	√	×	×
M-04	62	M	√	√	×
M-05	51*	F	√	×	×
M-06	76	M	√	√	√
M-07	55*	M	×	√	×
M-08	72	M	×	×	√
M-09	71	M	√	×	×
M-10	55*	M	×	√	×
M-11	64	F	√	×	×
M-12	71	M	√	×	√
M-13	66	M	√	×	×
M-14	59*	M	×	√	×
M-15	61	M	√	×	×
M-16	72	F	×	√	×
M-17	68	M	√	×	√
M-18	48*	M	√	×	×
M-19	53*	F	√	×	×
M-20	63	M	√	×	×
M-21	69	M	×	√	×
M-22	73	M	√	×	×
M-23	56*	M	√	×	×
M-24	68	M	×	√	×
M-25	57*	M	√	×	×
M-26	80	F	√	√	√
M-27	44*	M	×	√	×

Where, (*= < 60 years age participants), (√ = sample received) and (× = sample not received).

Table 3: Distribution of positive specimens for mucormycosis (n = 8)

Participants ID	Age (Y)	Gender (M/F)	Types of specimen		
			Sputum (n =5)	Nasal swab (n= 3)	BAL (n =0)
M-04	62	M	√	√	×
M-06	76	M	√	√	×
M-13	66	M	√	×	×
M-22	73	M	√	×	×
M-26	80	F	√	√	×

**Fig. 1:** Microscopic pictures of mucormycosis in sputum and nasal swab, (Images A, B, C = Gram's stain) and (Images D, E, F = KOH wet mount)

event cause by the black mold in post Covid-19 infection.

6. Source of Funding

Nil

7. Conflict of Interest

Nil

References

- Sharma A, Tiwari S, Deb MK, Marty JL. Severe acute respiratory syndrome coronavirus-2 (SARS-CoV-2): a global pandemic and treatment strategies. *Int J Antimicrob Agents*. 2020;56(2):106054. doi:10.1016/j.ijantimicag.2020.106054.
- Lai CC, Shih TP, Ko WC, Tang HJ, Hsueh PR. Severe acute respiratory syndrome coronavirus 2 (SARS-CoV-2) and coronavirus disease-2019 (COVID-19): The epidemic and the challenges. *Int J Antimicrob Agents*. 2020;55(3):105924. doi:10.1016/j.ijantimicag.2020.105924.
- Mahalaxmi I, Jayaramayya K, Venkatesan D, Subramaniam MD, Renu K, Vijayakumar P, et al. Mucormycosis: An opportunistic pathogen during COVID-19. *Environ Res*. 2021;201(6):111643. doi:10.1016/j.envres.2021.111643.
- Chavda VP, Apostolopoulos V. Mucormycosis – An opportunistic infection in the aged immunocompromised individual: A reason for concern in COVID-19. *Maturitas*. 2021;doi:10.1016/j.maturitas.2021.07.009.
- Kuehn BM. Pulmonary Fungal Infections Affect Patients with COVID-19. *JAMA*. 2020;324(22):2248. doi:10.1001/jama.2020.22914.
- Sharma S, Grover M, Bhargava S, Samdani S, Kataria T. Post coronavirus disease mucormycosis: a deadly addition to the pandemic spectrum. *J Laryngol Otol*. 2021;135(5):442–7. doi:10.1017/S0022215121000992.
- Arana C, Ramírez REC, Xipell M, Casals J, Moreno A, Herrera S, et al. Mucormycosis associated with COVID-19 in two kidney transplant patients. *Transpl Infect Dis*. 2021;doi:10.1111/tid.13652.
- Kwon-Chung KJ. Taxonomy of fungi causing mucormycosis and entomophthoromycosis (zygomycosis) and nomenclature of the disease: molecular mycologic perspectives. *Clin Infect Dis*. 2012;54(Suppl 1):S8–S15. doi:10.1093/cid/cir864.
- Afroze SN, Korlepara R, Rao GV, Madala J. Mucormycosis in a Diabetic Patient: A Case Report with an Insight into Its Pathophysiology. *Contemp Clin Dent*. 2017;8(4):662–6.
- Bhatt K, Agolli A, Patel MH, Garimella R, Devi M, Garcia E, et al. High mortality co-infections of COVID-19 patients: mucormycosis and other fungal infections. *Discoveries (Craiova)*. 2021;9(1):e126.
- Rao V, Arakeri G, Madikeri G, Shah A, Oeppen R, Brennan P. Post-COVID Mucormycosis in India: A formidable challenge. *Br J Oral*

- Maxillofac Surg.* 2021;doi:10.1016/j.bjoms.2021.06.013.
12. Divakar PK. Fungal Taxa Responsible for Mucormycosis“Black Fungus” among COVID-19 Patients in India. *J Fungi.* 2021;7(8):641. doi:10.3390/jof7080641.
 13. Ibrahim AS, Spellberg B, Walsh TJ, Kontoyiannis DP. Pathogenesis of mucormycosis. *Clin Infect Dis.* 2012;54(Suppl 1):S16–22. doi:10.1093/cid/cir865.
 14. Richardson MD, Rautemaa-Richardson R. Biotic Environments Supporting the Persistence of Clinically Relevant Mucormycetes. *J Fungi (Basel).* 2019;6(1):4. doi:10.3390/jof6010004.
 15. Moorthy A, Gaikwad R, Krishna S, Hegde R, Tripathi KK, Kale PG, et al. SARS-CoV-2, Uncontrolled Diabetes and Corticosteroids- An Unholy Trinity in Invasive Fungal Infections of the Maxillofacial Region? A Retrospective, Multi-centric Analysis. *J Maxillofac Oral Surg.* 2021;6:1–8. doi:10.1007/s12663-021-01532-1.
 16. Prakash H, Chakrabarti A. Global Epidemiology of Mucormycosis. *J Fungi (Basel).* 2019;5(1):26. doi:10.3390/jof5010026.
 17. Sipsas NV, Gamaletsou MN, Anastasopoulou A, Kontoyiannis DP. Therapy of Mucormycosis. *J Fungi (Basel).* 2018;4(3):90. doi:10.3390/jof4030090.

Author biography

Sonu S Ahirwar, Consultant Microbiologist

Cite this article: Ahirwar SS. Emerging cases of mucormycosis in post Covid-19 disease patients. *Indian J Microbiol Res* 2021;8(3):219-223.