



## Original Research Article

## Comparative study of anatomic and functional changes of the corneal endothelium in cataract patients undergoing phacoemulsification and MSICS

Gurvinder Khosa<sup>1,\*</sup>, Karanjit Singh<sup>1</sup>, Prempal Kaur<sup>1</sup>, Rajesh Kumar<sup>1</sup>, Shivani<sup>1</sup>, Upasna Ajmani<sup>1</sup>

<sup>1</sup>Dept. of Ophthalmology, Govt. Medical College, Amritsar, Punjab, India



## ARTICLE INFO

## Article history:

Received 14-01-2021

Accepted 24-01-2021

Available online 30-06-2021

## Keywords:

Astigmatism

Endothelial cell count

Manual small incision cataract surgery

Phacoemulsification

## ABSTRACT

**Aim:** The purpose of this study was to compare the effect of Phacoemulsification and Manual small incision cataract surgery (MSICS) on the corneal endothelium and to assess its impact on visual acuity and induced astigmatism.

**Materials and Methods:** In this prospective randomized study, 100 cases were randomly selected with the help of lottery system. 50 cases underwent phacoemulsification (group 1) and 50 underwent MSICS (group 2) by a single surgeon. The endothelial cell count, central corneal thickness, best corrected visual acuity and induced astigmatism was measured preoperatively and postoperatively on day 1, 7, 28 and on day 42.

**Results:** Mean endothelial cell loss (cells/mm<sup>2</sup>) in group 1 at the end of six weeks was 538.64 (20.59%) and in group 2 was 485.66 (19.20%) which was statistically insignificant ( $p > 0.05$ ). The mean central corneal thickness was reduced in both the groups with a mean of  $0.51 \pm 0.04$  mm in group 1 and  $0.50 \pm 0.03$  mm in group 2 which was statistically insignificant. Postoperative best corrected visual acuity of more than 6/18 was found in 49 (98%) cases in each group at six weeks, and was statistically insignificant ( $p$  value  $> 0.05$ ). Phacoemulsification group had statistically significant less mean postoperative astigmatism than MSICS group ( $p$  value  $< 0.05$ ).

**Conclusion:** Both groups gave similar statistically insignificant results in relation to endothelial cell loss, central corneal thickness and best corrected visual acuity at the end of six weeks, although the mean astigmatism was more in group 2 in comparison to group 1 with a statistically significant difference.

© This is an open access article distributed under the terms of the Creative Commons Attribution License (<https://creativecommons.org/licenses/by/4.0/>) which permits unrestricted use, distribution, and reproduction in any medium, provided the original author and source are credited.

### 1. Introduction

Cataract is a major cause of reversible blindness worldwide and surgery is currently the only treatment option.<sup>1</sup> Cataract surgery has seen in recent years a considerable evolution with respect to the surgical techniques. Phacoemulsification is the preferred technique in the developed world<sup>2</sup> while the surgery by MSICS is considered to be a cost effective way of cataract removal in the developing countries. Every cataract extraction, even in experienced hands and with modern techniques, involves some corneal decompensation, which has been reported to occur in about 1% of cataract extractions.<sup>3</sup> Morphological stability and functional

integrity of the corneal endothelium are necessary to maintain long term corneal transparency. Loss or damage of endothelial cells leads to an increase in corneal thickness, which may ultimately induce corneal decompensation and loss of vision.<sup>4</sup> Corneal astigmatism is also a by-product of cataract surgery and it plays an important role in recovery of visual function post surgery.

In developing countries such as India, where there is a cataract backlog, MSICS with intraocular lens (IOL) implantation promises to be a viable cost-effective alternative to phacoemulsification.<sup>5</sup> With approximately 6 million cataract surgeries being performed in India every year, it is important to determine the safest surgical technique for the cataract surgery. Hence, this study is an

\* Corresponding author.

E-mail address: [khosaginni@gmail.com](mailto:khosaginni@gmail.com) (G. Khosa).

attempt to compare the anatomic and functional changes to the corneal endothelium in cataract patients undergoing MSICS & Phacoemulsification at Regional Institute of Ophthalmology, Govt. Medical College, Amritsar, in relation to endothelial structure, corneal topographic changes, visual acuity and induced astigmatism.

## 2. Materials and Methods

This randomized prospective study was conducted on 100 cataract patients visiting Regional Institute of Ophthalmology, Govt. Medical College, Amritsar, after taking permission from Institutional Ethical Committee. Patients were randomly divided into two groups by lottery method, comprising 50 patients each who underwent phacoemulsification (group 1) and manual small incision cataract surgery (group 2). Grading of the cataract was not taken into consideration while allotment of the patient's to either of the two surgical techniques. Patients with senile cataract or presenile cataract of nuclear grade 2, 3 and 4 according to the LOCS III classification between the age group of 35-75 years, medically fit for cataract surgery under local anaesthesia and patients with normal corneal endothelium were included in the study. Patients with brown cataract, traumatic cataract, any corneal dystrophy and degenerations, past history of corneal or intraocular surgery, ocular diseases like glaucoma and uveitis and intraoperative complications i.e. posterior capsular rupture, vitreous loss were excluded from the study. The technique used in Manual small incision cataract surgery and phacoemulsification met the accepted standards worldwide. A written informed consent was taken in patient's vernacular language. All surgeries were performed by single surgeon and same type of single piece foldable hydrophilic posterior chamber intraocular lens was implanted. All patients underwent complete ophthalmic examination followed by measurement of central corneal thickness, endothelial cell count (specular microscopy) and pentacam study to know the corneal topography was performed preoperatively and postoperatively at day 1, day 7, day 28 and on 42<sup>nd</sup> day. Best corrected visual acuity was recorded at 6 weeks. All the parameters were tabulated and data analysis was performed using statistical package for the social sciences, version 21.0 for windows (IBM corp. SPSS, 2012, Armonk, NY) applying Chi square test, student unpaired sample t test and paired sample t test. P value < 0.05 was considered statistically significant. The operative technique used in both procedures met the surgical standards prevalent worldwide.

### 2.1. Surgical technique

After administering peribulbar anaesthesia and achieving asepsis, 50 patients underwent phacoemulsification (group 1) and 50 patients underwent Manual small incision cataract

surgery (group 2).

### 2.2. Phacoemulsification

A 2.8 mm superotemporal clear corneal incision was made and two side port incisions were given. Anterior capsule was stained with trypan blue dye. After filling viscoelastic in anterior chamber, continuous curvilinear capsulorhexis was done using 26 gauge cystitome, hydrodissection and hydrodelineation was done and emulsification of the nucleus was done by chop technique. The remaining cortical matter was cleaned using bimanual irrigation and aspiration cannula. Foldable posterior chamber IOL was implanted in the capsular bag. Anterior chamber was formed with balanced salt solution.

### 2.3. Manual small incision cataract surgery (MSICS)

A fornix based conjunctival flap was made. After giving self-sealing 6 mm superior scleral incision, sclerocorneal tunnel was made upto 1 mm of clear cornea. Side port incision was given and anterior chamber was entered with 2.8 mm keratome blade. Anterior capsule was stained with trypan blue dye. After filling the anterior chamber with viscoelastic, continuous curvilinear capsulorhexis was performed, sclerocorneal incision was enlarged by making side pouch incision on either side and hydrodissection was done. Viscoexpression of the nucleus was done and remaining lens matter was cleaned with reverse simcoe cannula. Foldable posterior chamber IOL was implanted inside the capsular bag. Anterior chamber was formed with balanced salt solution and conjunctiva was repositioned back over the sclerocorneal incision.

## 3. Results

### 3.1. Demographical values

The mean age was 56.26±8.73 in group 1 and 59.96±9.93 in group 2. 46% were males and 54% were females in group 1 and 42% were males and 58% were females in group 2. The demographic variables i.e. age and sexes were not statistically significant between the 2 groups (p value > 0.05).

### 3.2. Endothelial cell count

The mean preoperative endothelial cell count in group 1 was 2558.72±354.61 cells/mm<sup>2</sup>. Postoperatively on day 1, the mean endothelial cell count was reduced to 2331.54±365.65 cells/mm<sup>2</sup>. On day 42 the mean cell count was further reduced to 2020.08±361.47 cells/mm<sup>2</sup>. In group 2 the mean preoperative endothelial cell count was 2525.50±289.34 cells/mm<sup>2</sup>. Postoperatively on day 1 the mean endothelial cell count was reduced to 2355.28± 268.77cells/mm<sup>2</sup>. On day 42 the mean endothelial cell count was further reduced to 2039.84 ± 268.22 cells/mm<sup>2</sup>. The difference in mean

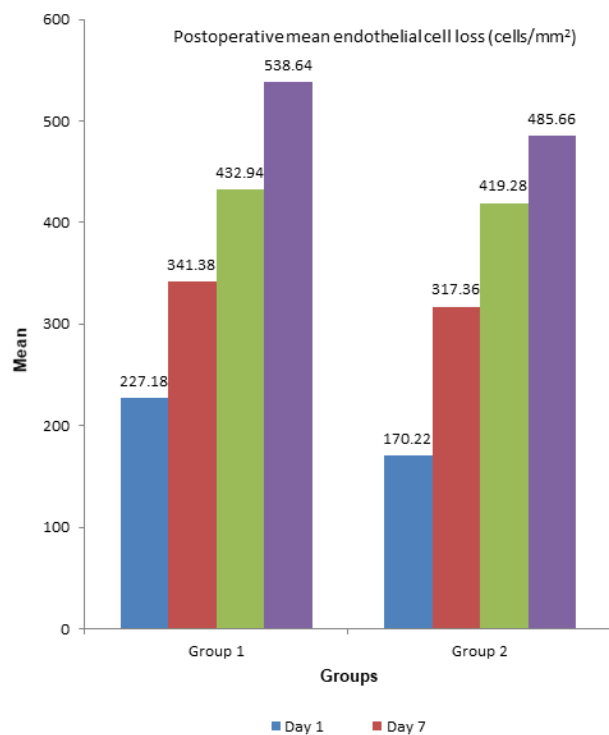
**Table 1:** Mean endothelial cell count (cells/mm<sup>2</sup>)

Groups	Preoperative Endothelial Cell count Mean±S.D.	Postoperative Endothelial Cell count Mean±S.D.			
		Day 1	Day 7	Day 28	Day 42
Group 1	2558.72±354.61	2331.54±365.65	2217.34±361.63	2125.78±356.73	2020.08±361.47
Group 2	2525.50±289.34	2355.28±268.77	2208.14±285.72	2106.22±272.06	2039.84±268.22
't' value	0.513	-0.370	0.141	0.308	-0.310
'p' value	0.609	0.0712	0.888	0.759	0.757
Significance	Not Significant	Not Significant			

endothelial cell count was not statistically significant at different postoperative intervals in both the groups. (Table 2)

### 3.3. Endothelial cell loss

In group 1, on first postoperative day there was loss of 227.18± 186.25 cells /mm<sup>2</sup> which further increased to 538.64± 350.08 (20.59%) on day 42. In group 2, a day after the surgery there was loss of 170.22± 152.40 cells /mm<sup>2</sup> which further increased to 485.66 ± 164.37 (19.20%) on day 42. The difference in mean endothelial cell loss was not significant at different postoperative intervals in both the groups (p >0.05). (Figure 1)

**Fig. 1:** Postoperative mean endothelial cell loss (cells/mm<sup>2</sup>)

### 3.4. Central corneal thickness

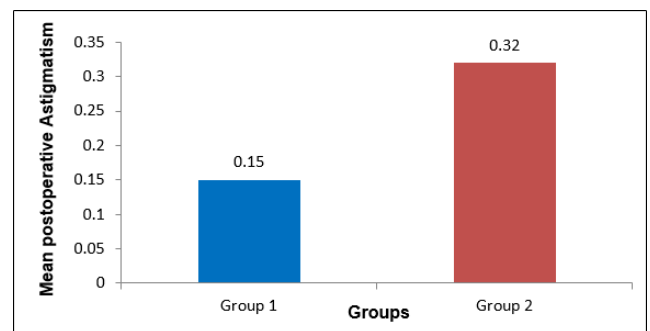
In group 1, the mean baseline central corneal thickness before surgery was 0.51±0.04 mm, which increased to 0.56±0.05 mm a day after surgery and in group 2, it was 0.50±0.04 mm before surgery which increased to 0.55±0.04 mm a day after surgery. The mean central corneal thickness was reduced closest to the preoperative value at day 42 in both the groups with a mean of 0.51±0.04 mm in group 1 and 0.50±0.03 mm in group 2. The difference in postoperative mean central corneal thickness was statistically not significant at all intervals in both groups.(Table 2)

### 3.5. Visual Acuity

In both groups, 49 cases each (98%) had postoperative best corrected visual acuity better than 6/18. The difference in postoperative best corrected visual acuity at 6 weeks was not statistically significant (p value = 1.0) (Table 3).

### 3.6. Post operative Astigmatism

The mean postoperative astigmatism in Group 1 was 0.154±0.22 D at 6 weeks and 0.32±0.34 D in Group 2 at 6 weeks. The difference was statistically significant between two groups (p value = 0.022). The mean postoperative astigmatism was less in Group 1 compared with Group 2 at 6 weeks. (Figure 2)

**Fig. 2:** Mean postoperative Astigmatism (In diopters)

**Table 2:** Postoperative Mean central corneal thickness (mm)

Groups	Postoperative Mean central corneal thickness ±S.D.(mm)			
	Day 1	Day 7	Day 28	Day 42
Group 1	0.56±0.05	0.53±0.04	0.52±0.04	0.51±0.04
Group 2	0.55±0.04	0.53±0.04	0.51±0.04	0.50±0.03
't' value	1.159	0.451	1.025	1.385
'p' value	0.249	0.653	0.308	0.169
Significance	Not Significant			

**Table 3:** Postoperative best corrected visual acuity at 6 weeks

Best Corrected visual acuity (BCVA)	Group 1	Group 2
VA≤6/18	1	1
VA>6/18	49	49
X <sup>2</sup>	0.000	
Df	1	
'p' value	1.00 (Not Significant)	

#### 4. Discussion

Phacoemulsification is the benchmark technique for cataract surgery.<sup>6,7</sup> Manual small incision cataract surgery has emerged as a cost effective alternative to phacoemulsification in the developing world.<sup>8</sup> Endothelial alteration is considered an important parameter of surgical trauma and essential for estimating the safety of the surgical technique. The percentage endothelial cell loss postoperatively in present study was more in group 1 as compared to group 2 in all postoperative intervals but the difference was not statistically significant ( $p > 0.05$ ). Similar result was found in a study by Ganekal S et al. who compared the morphological and functional endothelial changes after phacoemulsification versus MSICS and found that at the end of 6 weeks the endothelial changes were not statistically significant between the 2 groups.<sup>9</sup> Various other studies also comparing the endothelial cell loss at 6 weeks between phacoemulsification and manual small incision cataract surgery concluded statistically insignificant difference between the two groups.<sup>10-12</sup> In our study, maximum increase in central corneal thickness was seen postoperatively on day 1 in both the groups. The mean central corneal thickness was reduced closest to the preoperative value at day 42 in both the groups with a mean of  $0.512 \pm 0.038$  mm in group 1 and  $0.502 \pm 0.034$  mm in group 2. Similar increase in central corneal thickness postoperatively was seen in studies by Bolz et al., Ventura et al. and Cheng et al. which reported maximal increase in central corneal thickness occurred within 24 hours following cataract surgery followed by gradual decrease in corneal thickness.<sup>4,13,14</sup> Our results were also comparable to a study by Kongsap P, in which the central corneal thickness was greater in the phacoemulsification group on first day postoperatively ( $73 \mu$  increase in MSICS group and  $138 \mu$  in phaco group,  $p=0.008$ ) and it returned to preoperative levels 1 month postoperatively.<sup>15</sup>

In both the groups, 49 cases each (98%) had postoperative best corrected visual acuity better than 6/18. The difference in postoperative best corrected visual acuity at 6 weeks was not statistically significant ( $p$  value  $> 0.05$ ). The result of this study is comparable with numerous studies. In a study by Gogate et al., the corrected distance visual acuity at 6 weeks was better than 6/18 in 98.5% of patient's eyes in the phacoemulsification group and 97.3% of patient's eyes in the SICS group. Thus, there was no statistically significant difference in visual acuity between phacoemulsification and SICS.<sup>11</sup> Similar results were found in a study by Ashok Rathi et al as there was no statistically significant difference between the MSICS & Phacoemulsification in terms of BCVA at post-operative 1 month.<sup>16</sup>

In our study, there was no significant difference in mean astigmatism between both the groups during preoperative period. The mean postoperative astigmatism at six weeks in Group 1 was  $0.154 \pm 0.22D$  and  $0.32 \pm 0.34D$  in Group 2. The difference was statistically significant between two groups ( $p$  value  $< 0.05$ ). Mean astigmatism was much higher in MSICS group as compared to phaco group during all post-operative days and the mean differences were statistically significant. Similar results were found in a study conducted by Harakuni U et al. which observed SIA on 45th post-operative day in SICS group was  $+0.05$  while in phaco group was  $-0.53$  and this difference was statistically significant. SIA in phaco group was less compared to SICS group, showing phacoemulsification induced less post-operative astigmatism.<sup>17</sup> Study conducted by Khalaf M. et al. observed, at 3 months follow-up, the mean SIA was 2.08 in phaco group and in SICS group it was 2.96.<sup>18</sup>

#### 5. Conclusion

Our study concluded that both Phacoemulsification and MSICS gave similar statistically insignificant results in

relation to endothelial cell loss, central corneal thickness and best corrected visual acuity at the end of six weeks, although the mean astigmatism was more in group 2 in comparison to group 1. As the Manual small incision cataract surgery does not depend upon advanced technology and is more cost effective, it may be a favourable surgical procedure in those areas where high cost phacoemulsification techniques are still not accessible.

## 6. Source of Funding

None.

## 7. Conflict of Interest

The authors declare that there is no conflict of interest.

## References

- Thylefors B. The World Health Organization's programme for the prevention of blindness. *Int Ophthalmol*. 1990;14(3):211–9. doi:10.1007/bf00158321.
- Gogate P, Kulkarni S, Kulkarni S, Deshpande R, Joshi S, Palimkar A, et al. Safety and Efficacy of Phacoemulsification Compared with Manual Small-Incision Cataract Surgery by a Randomized Controlled Clinical Trial Six-Week Results. *Ophthalmology*. 2005;112(5):869–74. doi:10.1016/j.ophtha.2004.11.055.
- Pearce JL. Long term results of Binkhorst iris clip lens in senile cataract. *Br J Ophthalmol*. 1972;56:319–21.
- Ventura ACS. Corneal thickness and endothelial density before and after cataract surgery. *Br J Ophthalmol*. 2001;85(1):18–20. doi:10.1136/bjo.85.1.18.
- Muralikrishnan R, Venkatesh R, Prajna V, Frick K. Economic cost of cataract surgery procedures in an established eye care centre in Southern India. *Ophthalm Epidemiol*. 2004;11(5):369–80. doi:10.1080/09286580490888762.
- George R, Rupauliha P, Sripriya AV, Rajesh PS, Vahan PV, Praveen S. Comparison of Endothelial Cell Loss and Surgically Induced Astigmatism following Conventional Extracapsular Cataract Surgery, Manual Small-Incision Surgery and Phacoemulsification. *Ophthalm Epidemiol*. 2005;12(5):293–7. doi:10.1080/09286580591005778.
- Bourne RR, Minassian DC, Dart JK, Rosen P, Kaushal S, Wingaten N, et al. Effect of cataract surgery on the corneal endothelium; modern phacoemulsification compared with extracapsular cataract surgery. *Ophthalmology*. 2004;111:679–85.
- Venkatesh R, Tan CSH, Sengupta S. Phacoemulsification versus manual small-incision cataract surgery for white cataract. *J Cataract Refract Surg*. 2010;36:1849–54.
- Ganekal S, Nagarajappa A. Comparison of morphological and functional endothelial cell changes after cataract surgery: Phacoemulsification versus manual small-incision cataract surgery. *Middle East Afr J Ophthalmol*. 2014;21(1):56–60. doi:10.4103/0974-9233.124098.
- George R, Rupauliha P, Sripriya AV, Rajesh PS, Vahan PV, Praveen S. Comparison of Endothelial Cell Loss and Surgically Induced Astigmatism following Conventional Extracapsular Cataract Surgery, Manual Small-Incision Surgery and Phacoemulsification. *Ophthalm Epidemiol*. 2005;12:293–7. doi:10.1080/09286580591005778.
- Gogate P, Ambardekar P, Kulkarni S, Deshpande R, Joshi S, Deshpande M. Comparison of endothelial cell loss after cataract surgery: Phacoemulsification versus manual small-incision cataract surgery. *J Cataract Refract Surg*. 2010;36(2):247–53. doi:10.1016/j.jcrs.2009.09.023.
- Balan R. A Comparative Study of Endothelial Cell Loss In Small Incision Cataract Surgery and Phacoemulsification. *Kerala J Ophthalmol*. 2012;24(1):63–5.
- Bolz M, Sacu S, Drexler W, Findl O. Local corneal thickness changes after small-incision cataract surgery. *J Cataract Refract Surg*. 2006;32(10):1667–71. doi:10.1016/j.jcrs.2006.05.018.
- Cheng H, Bates AK, Wood L, Mcpherson K. Positive correlation of corneal thickness and endothelial cell loss. Serial measurements after cataract surgery. *Arch Ophthalmol*. 1988;106(7):920–2.
- Kongsap P. Visual outcome of manual small-incision cataract surgery: Comparison of modified Blumenthal and Ruit technique. *Int J Ophthalmol*. 2011;4:62–5.
- Rathi A, Singh N, Chauhan RS, Chugh JP, Jain G. A Comparative Study to Evaluate Visual Outcome in Post-Operative Patients of Manual Small Incision Cataract Surgery and Phacoemulsification. *Saudi J Med Pharm Sci*. 2020;06(04):353–8. doi:10.36348/sjms.2020.v06i04.004.
- Harakuni U, Bubanale S, Smitha KS, Tenagi AL, Kshama KK, Meena A, et al. Comparison of surgically induced astigmatism with small incision cataract surgery and phacoemulsification. *J Evol Med Dent Sci*. 2015;4(71):12354–60. doi:10.14260/jemds/2015/1784.
- Khalaf M, Mohamed K, Anbar M, Ammar H. Visual and astigmatic outcomes in manual small-incision cataract surgery versus phacoemulsification. *Egypt J Cataract Refract Surg*. 2016;22(2):37–41.

## Author biography

**Gurvinder Khosa**, Junior Resident

**Karanijit Singh**, Professor

**Prempal Kaur**, Professor and HOD

**Rajesh Kumar**, Associate Professor

**Shivani**, Junior Resident

**Upasna Ajmani**, Junior Resident

**Cite this article:** Khosa G, Singh K, Kaur P, Kumar R, Shivani, Ajmani U. Comparative study of anatomic and functional changes of the corneal endothelium in cataract patients undergoing phacoemulsification and MSICS. *Indian J Clin Exp Ophthalmol* 2021;7(2):358–362.