



Original Research Article

Ophthalmic manifestations of SARS-CoV-2 (COVID-19)

Sandhya Ramachandra¹, Aastha Garg^{2,*}¹Dept. of Ophthalmology, K C General Hospital, Bangalore, Karnataka, India²Dept. of Ophthalmology, Sri Devaraj Urs Medical College, Kolar, Karnataka, India

ARTICLE INFO

Article history:

Received 24-5-2021

Accepted 16-06-2021

Available online 30-06-2021

Keywords:

Cavernous sinus thrombosis

COVID- 19

Conjunctivitis

Dry eye disease

Ophthalmic manifestation

Orbital cellulitis

ABSTRACT

Introduction: The world has been dealing with the pandemic of COVID-19 since December 2019. The systemic manifestations of the disease are well known. Our study aims to evaluate the ocular manifestations of SARS-CoV-2 (COVID-19).

Methods: This cross-sectional observational study comprised of 60 subjects that tested positive for COVID-19 by RT-PCR, and admitted to the general wards of a tertiary care hospital of South India. Relevant medical history, ocular history, symptoms, signs and blood investigations data were obtained by communicating directly with the subjects and patient files. Ocular examination was done using diffuse torch light.

Results: 15% patients presented with conjunctivitis in association with increased conjunctival secretion, tearing and burning sensation. 3.33% patients presented with dry eye disease and orbital cellulitis each. 1.67% patients developed epiphora, cavernous sinus thrombosis and orbital cellulitis with retinal detachment each. A statistically significant correlation was found between the provisional diagnosis and C-reactive protein (CRP) values.

Conclusion: Conjunctival congestion can be one of the ocular symptoms of COVID-19. Asymptomatic COVID-19 patients may primarily present to an ophthalmologist with red eye, thus universal precautions must be taken while examining such cases. Evaluation of symptomatic patients with orbital cellulitis and cavernous sinus thrombosis can further aid in understanding the ophthalmic implications, pathogenesis and systemic involvement of this disease.

© This is an open access article distributed under the terms of the Creative Commons Attribution License (<https://creativecommons.org/licenses/by/4.0/>) which permits unrestricted use, distribution, and reproduction in any medium, provided the original author and source are credited.

1. Introduction

The world, since December 2019, is dealing with the emergence of a severe and acute respiratory coronavirus disease (COVID- 19), caused by severe acute respiratory syndrome coronavirus 2 (SARS-CoV-2).¹⁻¹³ What started with one patient in Wuhan province of China; was declared a pandemic by March 2020.²

Studies on the life cycle of coronavirus demonstrate that the infection begins with the spike of the glycoprotein of viral envelope attaching to the host cell receptor and host protease assisting the entry of the virion (via direct fusion or endocytosis) by cleaving and activating this receptor-spike

protein.^{3,12}

SARS-CoV-2 has been reported in tears and ocular tissues and thus, these secretions can be a source of transmission of infections.⁴

It has been observed that SARS-CoV-2 uses the cell entry receptor, angiotensin-converting enzyme 2 (ACE2), the expression and activity of which has been detected in the ocular surface, including cornea and conjunctiva, providing a trans-ocular entry potential for SARS-CoV-2.^{5,6} These receptors have also been identified in retina.¹⁰

Systemic manifestations of patients affected by COVID-19 are now widely known and manifold. These include fever, headache, dry cough, dyspnoea, pneumonia, myalgia, diarrhoea, anosmia, ageusia / dysgeusia and

* Corresponding author.

E-mail address: aasthagarg93@gmail.com (A. Garg).

coagulopathy.^{3,5} The neurological symptoms may be mild to severe ranging from dizziness and nausea/vomiting to altered mental status, ischemic or haemorrhagic stroke, acute necrotizing encephalopathy, and Guillain-Barre syndrome. Myocarditis, cardiac arrhythmias and heart failure have been seen in severe case.³

Several studies have been performed over the last year to know the ophthalmic implications of the disease. Conjunctivitis has been noted to be the most common ocular manifestation among which follicular conjunctivitis has been reported to be the commonest presentation.^{1–3,5,7–10} It may present either as an acute or a delayed onset symptom.¹⁰ Delayed onset or recurrent follicular conjunctivitis demonstrated a more severe form of disease as compared to the former.¹⁰ It was found to be more commonly associated in patients with severe systemic manifestations.³ Swabs taken from the conjunctival sac and tested for RT-PCR have shown positivity towards the viral RNA, irrespective of presence of ophthalmic manifestations.¹⁰ Rare cases of keratoconjunctivitis, ophthalmoparesis including abducens nerve palsies as an initial presenting symptom or within a few days of mild respiratory symptoms, respectively, have been reported.^{3,10,14,15} Pseudomembranous and haemorrhagic conjunctivitis as a late onset symptom of COVID-19 has also been demonstrated.^{10,16} Few cases of episcleritis have been reported, however such cases may be often self-limiting.¹⁰

The posterior segment manifestations of the disease are rare however; cases of isolated as well as combined central retinal artery occlusion (CRAO) and central retinal vein occlusion (CRVO) have been reported because these patients are in a pro-coagulant state, despite being on anticoagulants.⁵ Another plausible reason for development of CRVO in such patients has been purported to the state of pneumonia causing intermittent hypoxia that stimulates the release of endothelial tissue factors.¹⁰ This activates the extrinsic pathway of coagulation cascade which in turn causes a pro-thrombotic state.¹⁰

Cases of vitritis, acute retinal necrosis, splinter haemorrhages, soft and hard exudates have also been reported.¹⁰ The most important aspect to be considered before labelling these diseases as a viral manifestation is, to rule out other viral (example- herpes simplex, cytomegalovirus) and infectious (example- syphilis, bartonella, toxoplasma) agents which may provide similar retinal picture.¹⁰

COVID-19 is known to have a hypercoagulable presentation along with increased fibrinogen and D-dimers blood levels.^{17–20} This may lead to an increased incidence of cerebral venous sinus thrombosis (CVST) in such cases.^{19,20} Other inflammatory markers may also be higher in patients with ocular symptoms as compared to those without any.^{1,3,9,10,18–24}

Recent studies have reported a new spectacle of this disease spectrum in the form of rhino-orbital mucormycosis.^{25,26} It exists in the background of pre-existing morbidities like diabetes and indiscriminate use of steroids suppressing immunity.^{24,26,27} India has a significant number of type 2 diabetes mellitus patients and thus, the development of mucormycosis has to be considered significant.^{25–28}

The present study is being undertaken in a tertiary care hospital of South India to evaluate ocular manifestations of the disease and establish a relationship of their severity with inflammatory markers.

2. Materials and Methods

This cross-sectional study included 60 symptomatic and asymptomatic patients who tested positive for COVID-19 with nasopharyngeal throat swab RT-PCR. These patients were admitted to the general wards of a tertiary care hospital of South India. The patients included did not have an established ocular disease. The study was conducted from September 2020 to December 2020. Approval from institutional ethics committee was obtained. Patients with history of chronic usage of eye drops for any ocular conditions previously, allergic conjunctivitis, ocular (anterior and posterior segment) surgeries and contact lens usage were excluded.

A total of 60 patients fulfilling the inclusion and exclusion criteria were included in the study. The aim of the study was explained to participants and an informed consent was obtained before the start of examination. All patients underwent standard evaluation as per hospital protocol, such as detailed history, bedside visual acuity and diffuse torch light examination of anterior segment with the observer using appropriate Personal Protective Equipment (PPE). (Fundus examination was performed with indirect ophthalmoscope (IDO) for only one patient in whom high suspicion of retinal detachment was suspected). The findings were documented in the proforma on google forms to ensure no contact with the patient. The RT-PCR status, C- reactive protein, lactate dehydrogenase levels and serum ferritin levels of patients were also noted.

2.1. Statistical methods

Collected data was fed into Microsoft excel sheet and statistical analysis was performed with IBM SPSS 22 software. Provisional diagnosis was considered as primary outcome variable. C- reactive protein, lactate dehydrogenase isoenzyme and serum ferritin were considered as primary explanatory variable. Descriptive statistics were used to analyze data in accordance with the study objectives. Continuous variables were expressed as the mean \pm standard deviation with 95% confidence interval (CI; lower and upper bounds), median, minimum and

maximum, and percentage, where appropriate. Categorical variables were expressed as frequency and percent. Categorical outcomes were compared between study groups using the Chi square test. P value < 0.05 was considered statistically significant.

3. Results

3.1. Total 60 participants were included in the final analysis

As shown in Table 1, the mean age was 49.40 years, ranged between 10 to 84 years. Out of 60 participants 49 (81.67%) participants had common systemic symptoms of the disease. Majority (75.51%) participants had fever, followed by 55.10% participants who had shortness of breath and 46.94% participants had cough.

Table 1: Baseline and demographic variables

	Summary
Age	49.40±15.15 (range 10 to 84)
Does the patient have any of the widely known common symptoms	
No	11 (18.33%)
Yes	49 (81.67%)
Fever	37 (75.51%)
Shortness of breath	27 (55.10%)
Cough	23 (46.94%)
Fatigue	9 (18.37%)
Abdominal Pain	5 (10.20%)
Chills or Rigor	4 (8.16%)
Vomiting	4 (8.16%)
Sore Throat	3 (6.12%)
Chest Pain	3 (6.12%)
Headache	1 (2.04%)
Confusion/irritability	1 (2.04%)
Diarrhoea	1 (2.04%)
Has the patient been diagnosed with Pneumonia	35 (71.43%)
Unknown	1 (2.04%)
Any other symptoms if present	
1 episode of seizure	1 (1.67%)
Abdominal distension and bilateral scrotal swelling	1 (1.67%)
Decreased appetite	1 (1.67%)
H/O burning micturition	1 (1.67%)
No	56 (93.33%)
If No symptoms, why did the patient get tested for COVID-19 (N=10)	
Primary contact with COVID-19 positive case	6 (60.00%)
Pre-operative test	2 (20.00%)
Bleeding gums	1 (10.00%)
Swelling over the right cheek and drooping of upper lid, proptosis of the right eye	1 (10.00%)

The most commonly reported symptoms were redness of the eyes in 10%, burning sensation of eyes in 8.33% and excessive watering and itching of the eyes as 6.67% for each. 3.33% patients complained of diminution of vision. 1.67% patients reported drooping of monocular lid and dryness of eye for each. (Table 2)

Table 2: History of symptoms

History of symptom	Frequency	Percentage
Redness of eyes	6	10.00%
Burning sensation of eyes	5	8.33%
Excessive watering from eyes	4	6.67%
Itching of the eyes	4	6.67%
Swelling of the eyes	2	3.33%
Diminution of vision	1	1.67%
Drooping of the eyelid	1	1.67%
Dryness of eyes	1	1.67%
None	36	60.00%

Tables 3 and 4 summarize the findings of ocular examination of patients performed under diffuse torch light. All the participants were bilaterally orthophoric. 93.33% participants reported full and painless extra ocular movements in both eyes (BE) and 6.70% reported restricted and painful movements in one eye in all directions. 93.3% participants reported BE bedside visual acuity CF >3 meters, 5% patients reported to have vision of Perception of light (PL) and accurate Projection of Rays (PR), however, 1.67% patients reported PL vision but inaccurate PR.

Table 3: Summary of BE ocular examination

	Frequency	Percentages
BE ocular position		
Orthophoric	60	100%
BE extra ocular movements		
Full and painless	56	93.30%
Unilateral Restricted and painful in all directions	4	6.70%
BE bed side visual acuity		
CF>3M	56	93.33%
PL+ve PR accurate	3	5.00%
PL+ve PR inaccurate	1	1.67%

Under diffuse torch light examination, 6.67% participants had severe periorbital and eyelid edema for each respectively. 7 (11.67%) participants had mild serous conjunctival discharge, 3.33% participants each had mild and severe mucopurulent discharge. 15% patients had mild and 3.33% had severe conjunctival congestion. 1.67% patients had severe circumcorneal congestion. 93.3% participants had 3mm pupil round, regular, reactive to light. 5% had Grade III and 1.67% had Grade I Relative Afferent Pupillary Defect.

Maximum (15%) participants were diagnosed with conjunctivitis, 3.33% participants with dry eye disease

Table 4: Descriptive analysis of ocular signs under diffuse torch light examination (BE) in the study population (N=60)

Diffuse Torch Light Examination (BE)	Frequency	Percentages
Lids and Adnexa [Periorbital Edema]		
Severe	4	6.67%
None	56	93.33%
Lids And Adnexa [Eyelid Edema]		
Severe	4	6.67%
None	56	93.33%
Conjunctiva [Serous Discharge]		
Mild	7	11.67%
None	53	88.33%
Conjunctiva [Mucopurulent Discharge]		
Mild	2	3.33%
Severe	2	3.33%
None	56	93.33%
Conjunctiva [Conjunctival Congestion]		
Mild	9	15.00%
Moderate	1	1.67%
Severe	2	3.33%
None	48	80.00%
Conjunctiva [Circumcorneal Congestion]		
Severe	1	1.67%
None	59	98.33%
Pupil		
3mm RRRL	56	93.33%
Grade III RAPD	3	5.00%
Grade I RAPD	1	1.67%
Anterior Chamber		
Normal depth, Appears Quiet	59	98.30%
RE: Normal depth, quiet ; LE: Shallow AC	1	1.67%
Lens		
Clear	44	73.30%
Senile immature cataract	16	26.70%

Table 5: Descriptive analysis of provisional diagnosis and investigation parameters in the study population (N=60)

Provisional diagnosis	Frequency	Percentages
Conjunctivitis	9	15.00%
Dry Eye	2	3.33%
Orbital Cellulitis	2	3.33%
Cavernous Sinus Thrombosis	1	1.67%
Epiphora	1	1.67%
Orbital cellulitis with Retinal Detachment	1	1.67%
Nil ophthalmic manifestations	44	73.33%
C-Reactive protein		
Near positive	3	5.00%
Negative	18	30.00%
Positive	39	65.00%
Lactate dehydrogenase isoenzyme		
Normal	17	28.33%
Abnormal	43	71.67%
Serum Ferritin (N=52)		
Normal	34	65.38%
Abnormal	18	34.62%

and 3.33% with orbital cellulitis. 1 (1.67%) patient was given the provisional diagnosis of Orbital Cellulitis with Retinal Detachment and 1 (1.67%) patient Cavernous Sinus Thrombosis. Out of 60 participants, 39 (65%) participants had positive C- reactive protein. (Table 5, Figure 1)

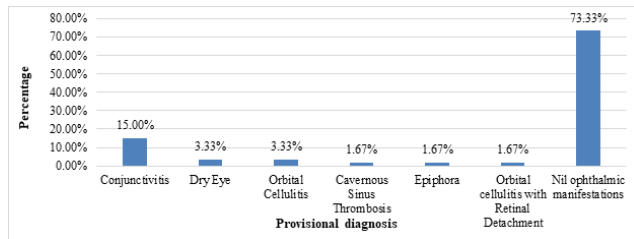


Fig. 1: Bar chart of provisional diagnosis

The difference in the proportion of provisional diagnosis with serum ferritin was found to be insignificant with a p value of 0.242. (Table 6, Figure 2)

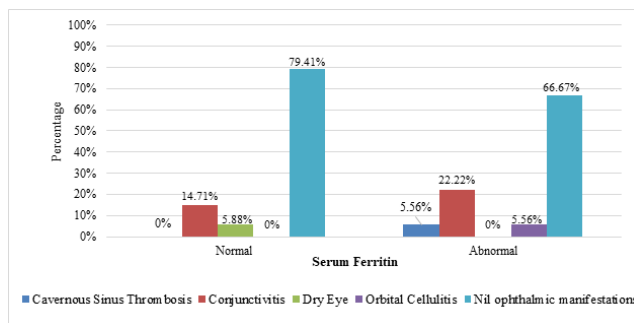


Fig. 2: Cluster bar chart of comparison of provisional diagnosis with serum ferritin (N=52)

The difference in the proportion of various provisional diagnoses to lactate dehydrogenase isoenzyme was found to be insignificant with a P- value of 0.197. (Table 7, Figure 3)

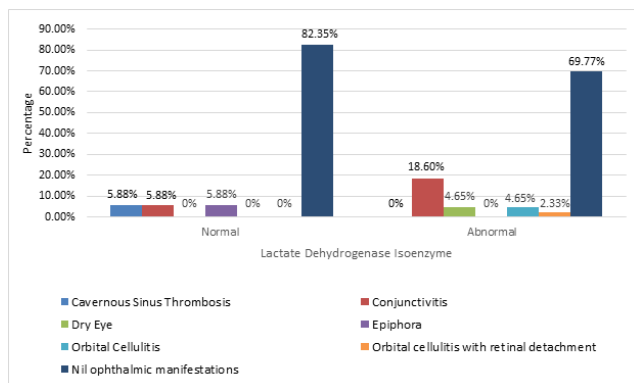


Fig. 3: Cluster bar chart of comparison of provisional diagnosis between lactate dehydrogenase isoenzyme (N=60)

The difference in the proportion of provisional diagnosis to C- Reactive Protein was found to be significant with a P-

value of 0.003. (Table 8, Figure 4)

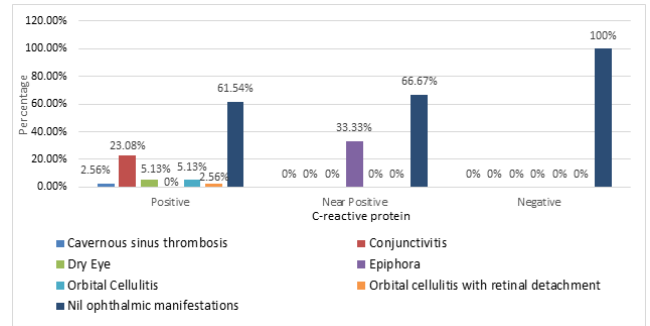


Fig. 4: Cluster bar chart of comparison of provisional diagnosis with C-Reactive Protein (N=60)

The difference in the proportion of provisional diagnosis to patients diagnosed with pneumonia was found to be insignificant with a P- value of 0.196. (Table 9, Figure 5)

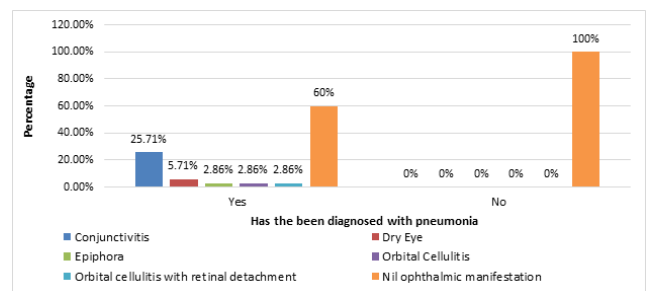


Fig. 5: Cluster bar chart of provisional diagnosis between has the been diagnosed with pneumonia (N=48)

4. Discussion

This study included 60 consecutive patients & all the samples were collected by a single observer.

The occurrence of conjunctivitis in COVID-19 remains relatively definite. Many studies have shown conjunctivitis to be the most common ophthalmic manifestation.^{2,5,8-11,13} In a study by Guan et al, the incidence was 0.8% to 7.9%.⁵ In a study by Chen L et al the incidence was 5%.⁵ In our present study, viral conjunctivitis was seen as the most common manifestation, in 9 of the 60 patients and thus, the incidence was 15.0%. These patients complained of symptoms such as redness in eyes (10%) associated with burning and itching sensation; and watering from eyes. On diffuse torch light examination they showed mild conjunctival congestion (15%) and serous discharge (11.7%). These patients did not report any associated history of chronic eye disease, inflammatory diseases or intraocular surgeries. A higher percentage in our study may be substantiated by the fact that the sample size considered in the study was less compared to the 535 patients considered in the study by Chen L et al. In a

Table 6: Comparison of provisional diagnosis with serum ferritin levels (N=52)

Provisional diagnosis	Serum Ferritin		P value
	Normal (N=34)	Abnormal (N=18)	
Cavernous Sinus Thrombosis	0 (0%)	1 (5.56%)	0.242
Conjunctivitis	5 (14.71%)	4 (22.22%)	
Dry Eye	2 (5.88%)	0 (0%)	
Orbital Cellulitis	0 (0%)	1 (5.56%)	
Nil ophthalmic manifestations	27 (79.41%)	12 (66.67%)	

Table 7: Comparison of provisional diagnosis with lactate dehydrogenase isoenzyme levels (N=60)

Provisional diagnosis	Lactate Dehydrogenase Isoenzyme		P value
	Normal (N=17)	Abnormal (N=43)	
Cavernous Sinus Thrombosis	1 (5.88%)	0 (0%)	0.197
Conjunctivitis	1 (5.88%)	8 (18.6%)	
Dry Eye	0 (0%)	2 (4.65%)	
Epiphora	1 (5.88%)	0 (0%)	
Orbital Cellulitis	0 (0%)	2 (4.65%)	
Orbital cellulitis with retinal detachment	0 (0%)	1 (2.33%)	
Nil ophthalmic manifestations	14 (82.35%)	30 (69.77%)	

Table 8: Comparison of provisional diagnosis with C - reactive protein (N=60)

Provisional diagnosis	C-reactive protein			P value
	Positive (N=39)	Near Positive (N=3)	Negative (N=18)	
Cavernous sinus thrombosis	1 (2.56%)	0 (0%)	0 (0%)	0.003
Conjunctivitis	9 (23.08%)	0 (0%)	0 (0%)	
Dry Eye	2 (5.13%)	0 (0%)	0 (0%)	
Epiphora	0 (0%)	1 (33.33%)	0 (0%)	
Orbital Cellulitis	2 (5.13%)	0 (0%)	0 (0%)	
Orbital cellulitis with retinal detachment	1 (2.56%)	0 (0%)	0 (0%)	
Nil ophthalmic manifestations	24 (61.54%)	2 (66.67%)	18 (100%)	

Table 9: Comparison of provisional diagnosis with those who have been diagnosed with pneumonia (N=48)

Provisional diagnosis	Has the patient been diagnosed with pneumonia		P value
	Yes (N=35)	No (N=13)	
Conjunctivitis	9 (25.71%)	0 (0%)	0.196
Dry Eye	2 (5.71%)	0 (0%)	
Epiphora	1 (2.86%)	0 (0%)	
Orbital Cellulitis	1 (2.86%)	0 (0%)	
Orbital cellulitis with retinal detachment	1 (2.86%)	0 (0%)	
Nil ophthalmic manifestation	21 (60%)	13 (100%)	

study by Wu P et al., where 38 patients were recruited in the study, 31.6% were diagnosed with conjunctivitis, thus, corroborating the fact that a smaller sample size may give a higher incidence of conjunctivitis.⁹ However, it must also be considered that conjunctivitis may develop as the common symptom due to increased hand-eye contact and poor ocular and hand hygiene among the population of developing countries.^{4,5,10,12} Thus meticulous hand hygiene, appropriate PPE and precautions should be practiced to prevent transmission.^{1,3,11} In our study, history of hand eye contact was not elicited from the patients.

Since, slit lamp examination could not be performed on these patients owing to the safety precautions, the presence of conjunctival follicles could not be commented upon. Viral conjunctivitis and keratoconjunctivitis may also be the initial presenting feature without any other systemic manifestations in many SARS-CoV-2 cases.^{3,5,14} However, studies demonstrate that acute viral conjunctivitis may present as late as 13-24 days of onset of the disease.^{5,13}

In a study by Chen L et al it was reported that incidence of dry eye was 20.9%.⁵ A study by Hong N et al concentrating on evaluation of dry using Salisbury Eye Evaluation Questionnaire (SEEQ) and Ocular Surface

Disease Index (OSDI) scores reported a significant increase in the respective scores after the onset of COVID-19 suggesting noteworthy ocular surface degradation.⁶ Contrary to this, in our study, we found the incidence of dry eye disease to be relatively low i.e. 3.33% (2 of 60 patients). Among them, 1 patient solely complained of dryness of eyes and another had symptoms of burning sensation associated with increased watering. These patients did not complain of foreign body sensation, redness of eyes or any blurred vision. This vast disparity may be explained by the geographic variations affecting the condition. An increased incidence of dry eye has also been attributed to increased screen time over the past one year.⁵

Studies on development of orbital cellulitis and cavernous sinus thrombosis in association with COVID-19 are scarce. It has been postulated that COVID-19 causes a decreased mucociliary clearance with a secondary sinus obstruction.^{10,21,22} This immunocompromised state can cause superinfection by bacteria leading to orbital cellulitis which can rapidly progress to orbital apex syndrome.²¹

The thrombotic complications of SARS-CoV-2 are being increasingly recognized and it has been described as a pro-thrombotic condition.^{10,18–20,22} Hypercoagulability associations include pulmonary emboli, acute necrotizing haemorrhagic encephalitis, stroke, limb extremity gangrene, and gastric bleeding as well as DIC in newborns of COVID-19 infected mothers.^{10,22} Superior sagittal sinus is the most commonly involved cerebral vein.²⁰ Kacha A et al. described the first and rare case of cavernous sinus thrombosis (CST) associated with COVID-19 in their case report.²⁰ To our knowledge no other case of CST has been reported.

Our present study uniquely reported 3.33% cases of orbital cellulitis (2 patients), 1.67% of orbital cellulitis with retinal detachment (1 patient) and 1.67% of cavernous sinus thrombosis (1 patient). These patients presented with symptoms of sudden diminution of vision to as low as Perception of Light and swelling around the eyes. Associated signs included severe periorbital oedema, proptosis, mucopurulent discharge, conjunctival chemosis, circumcorneal congestion and Relative Afferent Pupillary Defect (RAPD). Ptosis was noted in one case. Computed Tomography of the orbit was done for these patients and Contrast Enhance Computed Tomography (CECT) of one patient showed thrombosis of superior ophthalmic vein suggestive of cavernous sinus thrombosis. Fungal disease was ruled out in all.

Previous studies demonstrate that patients with ocular symptoms are likely to have higher levels of inflammatory makers such as pro-calcitonin, C-reactive protein (CRP), Lactate Dehydrogenase (LDH) and D-Dimer.^{1,3,9,10,18,20,22,23} In our present study we evaluated the relationship between serum ferritin, CRP and LDH. D-Dimer was only performed in severe cases of COVID

-19 patients and thus sufficient data could not be collected for the same.

There were 18 patients in our study population of 60, who had abnormal values of serum ferritin. Among the patients with abnormal values, 66.67% had no ophthalmic manifestations and 22.22% were associated with conjunctivitis. Incidence of raised serum ferritin with orbital cellulitis and cavernous sinus thrombosis was 5.56% each. These results were statistically insignificant (p value= 0.242). These results differed from a study done by Banchini F and fellows which showed a statistically significant, 52% increase in serum ferritin levels in COVID-19 positive patients.²³ This discrepancy may be because a very small sample size (17 COVID-19 positive patients) was considered as the study population by Banchini F et al. Serum ferritin is an acute phase protein which also correlates the amount of tissue damage.²³ Its role in monitoring the inflammatory process remains ambiguous, thus, more studies need to be performed to establish its role as a marker in COVID-19 patients.

In our study, statistically insignificant results ($p=0.197$) were obtained with raised LDH values. Majority patients with elevated LDH did not develop any ophthalmic manifestations (69.77%) followed by 18.67% of patients with raised serum LDH with conjunctivitis. Contrasting to this, a study by Wu P et al a statistically significant relationship between ocular symptoms of COVID-19 and raised LDH values. However, the sample size considered in this study was of only 38 patients, which have been pointed out as one of the limitation of this study.⁹

In our study group 39 patients were found to have positive CRP values and 3 patients had near positive values. Among these CRP positive, patients with ophthalmic manifestation, majority (23.08%) were with conjunctivitis followed by dry eye disease and orbital cellulitis (5.13% each); and then cavernous sinus thrombosis (2.56%). These values were statistically significant ($p=0.003$). This was similar to the study of Wu P et al, where a statistically significant ($p= 0.04$) relationship was noted between ocular symptoms positive CRP values.⁹

Studies done previously have also aimed at establishing a relationship between COVID-19 associated severe pneumonia and ocular manifestations. Studies found a positive co-relation between the two.^{1,2,9,10} Virus particles have been detected by RT-PCR in the tears and conjunctival secretions of patients with pneumonia and conjunctivitis.¹ Agarwal et al. reported that 6.9% patients with severe pneumonia developed ocular symptoms.¹⁰ Contrary to this, in our study this relationship was found to be statistically insignificant ($p=0.196$). This might be because severe cases of pneumonia will be admitted to Intensive Care Unit (ICU) whereas, our study population consisted of relatively stable patients admitted to general wards of the hospital.

Limitations of the study include small sample size; larger sample size would help in better understanding of the varied manifestations. However, since, this study was performed while India faced the first wave of COVID-19 pandemic and severe cases admitted to ICU were not included; the ophthalmic manifestations associated with proning, ventilation, and use of higher antibiotics; could not be incorporated into the disease profile of the study. Also, conjunctival swabs for RT-PCR evaluation for evidence of virus on ocular surface were not done; which could provide information regarding the transmission of virus through tears. It may also serve as a diagnostic tool in patients that present early with only ophthalmic manifestations. A case control study in larger population would be ideal to understand the disease spectrum.

5. Conclusion

This study showed that SARS-CoV-2 involves the ocular surface with conjunctivitis being the most common presentation. The knowledge of presentation and pathogenesis of the conjunctivitis without systemic manifestations may help in early diagnosis and treatment protocol of COVID-19. This disease may also present as orbital cellulitis and cavernous sinus thrombosis, the incidence of which is lesser known.

The increase of rhino-orbital mucormycosis cases during the second wave has changed the clinical profile and rekindled further interest into understanding the ophthalmic implications of this disease. Thus, an early suspicion of ocular involvement and preliminary ophthalmic evaluation can be potentially life and vision saving in COVID-19 patients.

6. Source of Funding

None.

7. Conflict of Interest

The authors declare that there is no conflict of interest.

References

- Amesty MA, Barrio JLA, Alió JL. COVID-19 Disease and Ophthalmology: An Update. *Ophthalmol Ther.* 2020;9(3):1–12. doi:10.1007/s40123-020-00260-y.
- Sirak S, Katsaras G, Akritidou F, Styllas F, Papamitsou T. Ocular Findings of Patients with Coronavirus Disease 2019. *Am J Otolaryngol Head Neck Surg.* 2020;3.
- Douglas KAA, Douglas VP, Moschos MM. Ocular Manifestations of COVID-19 (SARS-CoV-2): A Critical Review of Current Literature. *In Vivo.* 2020;34(3 suppl):1619–28. doi:10.21873/invivo.11952.
- Loon SC. The severe acute respiratory syndrome coronavirus in tears. *Br J Ophthalmol.* 2004;88(7):861–3. doi:10.1136/bjo.2003.035931.
- Chen L, Deng C, Chen X, Zhang X, Chen B, Yu H, et al. Ocular Manifestations And Clinical Characteristics Of 535 Cases Of COVID-19 In Wuhan, China: A Cross-Sectional Study. *Acta Ophthalmol.* 2020;98(8):951–9.
- Hong N, Yu W, Xia J, Shen Y, Yap M, Han W. Evaluation of ocular symptoms and tropism of SARS-CoV-2 in patients confirmed with COVID-19. *Acta Ophthalmol.* 2020;98(5):1–7. doi:10.1111/aos.14445.
- Lalgudi VG, Shetty R, D'Souza S. What ophthalmologists should know about conjunctivitis in the COVID-19 pandemic? *Indian J Ophthalmol.* 2020;68(5):683–7. doi:10.4103/ijo.ijo_869_20.
- Seah I, Agrawal R. Can the Coronavirus Disease 2019 (COVID-19) Affect the Eyes? A Review of Coronaviruses and Ocular Implications in Humans and Animals. *Ocular Immunol Inflamm.* 2020;28(3):391–5. doi:10.1080/09273948.2020.1738501.
- Wu P, Duan F, Luo C, Liu Q, Qu X, Liang L, et al. Characteristics of Ocular Findings of Patients With Coronavirus Disease 2019 (COVID-19) in Hubei Province, China. *JAMA Ophthalmol.* 2020;138(5):575–8. doi:10.1001/jamaophthalmol.2020.1291.
- Honavar SG, Sen M, Sharma N, Sachdev MS. COVID-19 and Eye: A Review of Ophthalmic Manifestations of COVID-19. *Indian J Ophthalmol.* 2021;69(3):488–509. doi:10.4103/ijo.ijo_297_21.
- Li JP, Lam DSC, Chen Y. Novel Coronavirus disease 2019 (COVID-19): The importance of recognising possible early ocular manifestation and using protective eyewear. *Br J Ophthalmol.* 2020;104:297–8.
- Azzolini C, Donati S, Premi E, Baj A, Siracusa C, Genoni A, et al. SARS-CoV-2 on Ocular Surfaces in a Cohort of Patients With COVID-19 From the Lombardy Region, Italy. *JAMA Ophthalmol.* 2021;2021:1–8. doi:10.1001/jamaophthalmol.2020.5464.
- Chen L, Liu M, Zhang Z, Qiao K, Huang T, Chen M. Ocular manifestations of a hospitalised patient with confirmed 2019 novel coronavirus disease. *Br J Ophthalmol.* 2020;104:748–51.
- Cheema M, Aghazadeh H, Nazarali S, Ting A, Hodges J, McFarlane A, et al. Keratoconjunctivitis as the initial medical presentation of the novel coronavirus disease 2019 (COVID-19). *Can J Ophthalmol.* 2020;55(4):e125–9. doi:10.1016/j.cjco.2020.03.003.
- Dinkin M, Gao V, Kahan J, Bobker S, Simonetto M, Wechsler P, et al. COVID-19 presenting with ophthalmoparesis from cranial nerve palsy. *Neurology.* 2020;95(5):221–3. doi:10.1212/wnl.0000000000009700.
- Navel V, Chiambaretta F, Duthel F. Haemorrhagic conjunctivitis with pseudomembranous related to SARS-CoV-2. *Am J Ophthalmol Case Rep.* 2020;19:100735. doi:10.1016/j.ajoc.2020.100735.
- Wang H, Li X, Li T, Zhang S, Wang L, Wu X. The genetic sequence, origin, and diagnosis of SARS-CoV-2. *Eur J Clin Microbiol Infect Dis.* 2020;24:1–7.
- Litjens JF, Leclerc M, Chochois C, Monsallier JM, Ramakers M, Auvray M, et al. High incidence of venous thromboembolic events in anticoagulated severe COVID-19 patients. *J Thromb Haemost.* 2020;18(7):1743–6. doi:10.1111/jth.14869.
- Nwajei F, Anand P, Abdalkader M, Arasa VCA, Aparicio HJ, Behbahani S, et al. Cerebral Venous Sinus Thromboses in Patients with SARS-CoV-2 Infection: Three Cases and a Review of the Literature. *J Stroke Cerebrovasc Dis.* 2020;29(12). doi:10.1016/j.jstrokecerebrovasdis.2020.105412.
- Khacha A, Bouchal S, Ettabyaoui A, Haloua M, Lamrani YA, Boubbou M, et al. Cavernous sinus thrombosis in a COVID-19 patient: A case report. *Radiol Case Rep.* 2021;16(3):480–2. doi:10.1016/j.radcr.2020.12.013.
- Bagheri M, Jafari A, Jafari S. Orbital apex syndrome in COVID-19 patient, a case report. *Vis J Emerg Med.* 2021;23. doi:10.1016/j.visj.2021.101006.
- Turbin RE, Wawrzusin PJ, Sakla NM, Traba CM, Wong KG, Mirani N, et al. Orbital cellulitis, sinusitis and intracranial abnormalities in two adolescents with COVID-19. *Orbit.* 2020;39(4):305–10. doi:10.1080/01676830.2020.1768560.
- Banchini F, Cattaneo GM, Capelli P. Serum ferritin levels in inflammation: a retrospective comparative analysis between COVID-19 and emergency surgical non-COVID-19 patients. *World J Emerg Surg.* 2021;16(1):1–7. doi:10.1186/s13017-021-00354-3.
- Maurya R. COVID-19 and Ophthalmologists. *Ind J Clin Exp Ophthalmol.* 2020;6(3):312–4.
- Mehta S, Pandey A. Rhino-Orbital Mucormycosis Associated With COVID-19. *Cureus.* 2020;12:1–5. doi:10.7759/cureus.10726.

26. Maini A, Tomar G, Khanna D, Kini Y, Mehta H, Bhagyasree V. Sino-orbital mucormycosis in a COVID-19 patient: A case report. *Int J Surg Case Rep.* 2021;82:105957. doi:10.1016/j.ijscr.2021.105957.
27. Agrawal SK, Maurya RP. Invasive sino-orbito-cerebral Mycosis: An overview. *Ind J Clin Exp Ophthalmol.* 2015;1(3):149–55.
28. Revannavar SM, Supriya PS, Samaga L, Vineeth VK. COVID-19 triggering mucormycosis in a susceptible patient: a new phenomenon in the developing world? *BMJ Case Reports.* 2021;14(4):e241663. doi:10.1136/bcr-2021-241663.

Author biography

Sandhya Ramachandra, Senior Consultant & DNB
Professor

Aastha Garg, Junior Resident

Cite this article: Ramachandra S, Garg A. Ophthalmic manifestations of SARS-CoV-2 (COVID-19). *Indian J Clin Exp Ophthalmol* 2021;7(2):293-301.