

Content available at: <https://www.ipinnovative.com/open-access-journals>

Indian Journal of Pharmacy and Pharmacology

Journal homepage: <https://www.ijpp.org.in/>

Review Article

Mucormycosis: A manifestation in COVID-19 infection

Abhishek Sharma^{1,*}, Gulnaz Bano², Abdul Malik³¹Dept. of Clinical Pharmacy Practice & Quality In Healthcare, Hakeem Abdul Hameed Centenary Hospital & Hamdard Institute of Medical Sciences & Research, Hamdard Nagar, New Delhi, India²Dept. of Pharmacology, School of Pharmaceutical Education and Research, Jamia Hamdard, New Delhi, India³Dept. of Pharmacy Practice, Teerthanker Mahaveer College of Pharmacy, Moradabad, Uttar Pradesh, India

ARTICLE INFO

Article history:

Received 10-07-2021

Accepted 20-08-2021

Available online 04-09-2021

Keywords:

COVID-19 infection

Immunocompromised host

Mucormycosis

Nasal congestion

Thrombosis

ABSTRACT

Patients with COVID-19 may develop higher susceptibility to fungal co-infections. Mucormycosis is a rare and often life-threatening disease caused by vascular invasion by hyphae, leading to thrombosis and necrosis. Mucormycosis has been the cause of morbidity and mortality in transplant, ICU and immunodeficient individuals over a long period of time, but in India, a rapid increase in the number of cases seen in unexpected patients with Covid-19, which is a major concern. Covid-19 patients, already immunocompromised with underlying condition, had been exposed to severe Covid-19 infection and been using steroids, were at greater risk of developing mucormycosis. Out of ten cases reported by Sir Ganga Ram Hospital, Delhi India in December 2020, five succumbed to mucormycosis. Another unique feature reported in mucor patients was age, most were elderly with ages between 45 to 60 years. The mortality rate is currently estimated at 50% in India. Symptoms such as nasal congestion, swelling of the eye or cheeks and dark brown crusts inside the nose should be reported immediately and anti-fungal treatment should be started.

This is an Open Access (OA) journal, and articles are distributed under the terms of the [Creative Commons Attribution-NonCommercial-ShareAlike 4.0 License](https://creativecommons.org/licenses/by-nc-sa/4.0/), which allows others to remix, tweak, and build upon the work non-commercially, as long as appropriate credit is given and the new creations are licensed under the identical terms.

For reprints contact: reprint@ipinnovative.com

1. Introduction

Coronavirus 2019 (COVID-19) is a new disease caused by the novel coronavirus (SARS-CoV-2) which first appeared in China in December 2019 and later on declared a global pandemic.¹ Corona viruses are enveloped, large single-stranded RNA viruses that infect humans, but also various species and its rapid spreadability and high mortality rate have caused severe disruptions.^{2,3} Although pathophysiology of the virus is still being researched, new manifestations of symptoms and complications continue to materialize.¹ The severeness of the infections ranges from asymptomatic infection to respiratory failure and death. It is associated with a variety of opportunistic

bacterial and fungal infections such as mucormycosis which are important challenges increasing the patient's morbidity and mortality.⁴⁻⁷ Mucormycosis refers to a group of saprophytic fungi that are found in decaying vegetation and food containing high sugar content and these organisms are omnipresent in nature.²⁻¹⁶ Mucormycosis, also known as zygomycosis and phycomycosis is a rare and lethal disease caused by a common fungus that is part of the class Zygomycetes and classified as mucorales and entomophthorales. The clinical presentation of mucormycosis differs depending on the location of the disease.^{2-9,17-26} The Entomophthorales are rare causes of subcutaneous and mucocutaneous infections which is known as entomophthoromycosis, which mainly afflict immunosuppressed individuals in developing countries.²⁷ Mucormycosis is characterized as rhinocerebral, pulmonary,

* Corresponding author.

E-mail address: scientist.abhi12@gmail.com (A. Sharma).

cutaneous, gastrointestinal, disseminated or further, which consist of infection of bones, heart, ear, parotid gland, uterus, urinary bladder and lymph nodes.^{6,7,9–16,28,29} Rhino-cerebral mucormycosis occurs most frequently in diabetic patients, while pulmonary mucormycosis is most common in patients with hematological malignancies.¹⁴ It is a rare but serious persistent fungal infection going on usually in immunosuppressed patients, particularly in patient who have uncontrolled diabetes or hematological deficiency, high iron deficiency, severe trauma, long-term use of corticosteroids, drug abuse, childhood malnutrition, malnutrition and other chronic disease.^{2–5,8,18–26} The most common risk factor related with mucormycosis is diabetes mellitus in India.^{12–15} Recently, several cases of mucormycosis in people with COVID-19 have been reported extensively worldwide, mainly from India.⁴ COVID-19 patients, especially those who are severely ill or have depressive disorders, are more likely to suffer from invasive mycoses.³⁰ The disease has a high mortality rate. Imaging methods are not generally diagnostic and cultures are not perfectly consistent. The investigation is entirely based on an examination of patient’s history. Management is often ineffective, leading to progressive infection and mortality.¹⁹

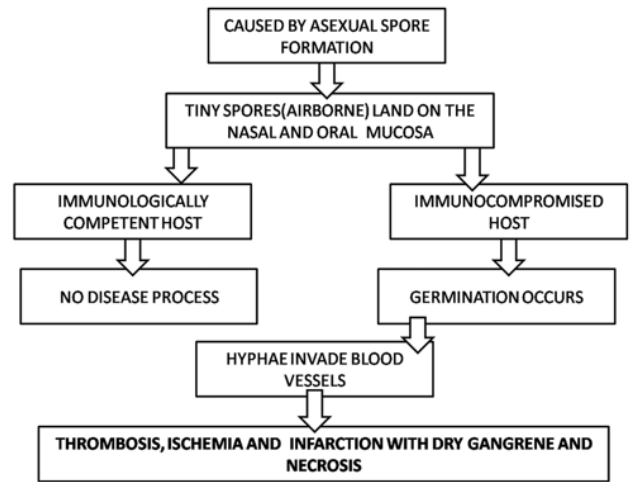


Fig. 2: Pathophysiology of mucormycosis³¹

two ways. First one is Superficial and Visceral and the second one is localized and disseminated. The features of superficial form are seen in external organs such as ear, finger nails and skin. While visceral forms are affected in pulmonary, gastrointestinal and rhino cerebral systems. These spores enters either through cutaneous or respiratory route.¹³ The most commonly reported areas of invasive mucormycosis are paranasal sinuses (39%), lungs (24%), and skin (19%). Table No.1 summarizes the COVID-19 cases with mucormycosis infection. Mucormycosis is only confined in the intestinal tract and is common in only 7% of cases. However, the occurrence of intestinal mucormycosis raises an increased possibility of the emergence of severe fungal strains.^{2–11,21–26}

2. Pathophysiology

The pathophysiology of COVID-19 may also account for an unprecedented collaboration with invasive fungal infection (IFI). First, the highly aggressive feature of the SARS-CoV-2 virus in the lung tissue and the large two-sized lesions that occur between the alveolo-interstitial make IFI possible, especially those with primary pulmonary entry and airway obstruction such as invasive pulmonary aspergillosis (IPA), pneumocystis and mucormycosis. Second, the total number of T lymphocytes, CD4 + T and CD8 + T cells is significantly lower in severe cases of COVID-19 than in moderate cases, associated with very high levels of IL-2R, IL-6, IL-10, TNF-alpha and other inflammatory markers.^{2–16,22–26,28,29,32} Mucormycosis infection is caused by asexual spore formation. The tiny spores come to be airborne and settle on the oral and nasal mucosa of human beings. In majority of immunologically competent hosts, these spores might be confined via a phagocytic response. If this response be unsuccessful, germination will

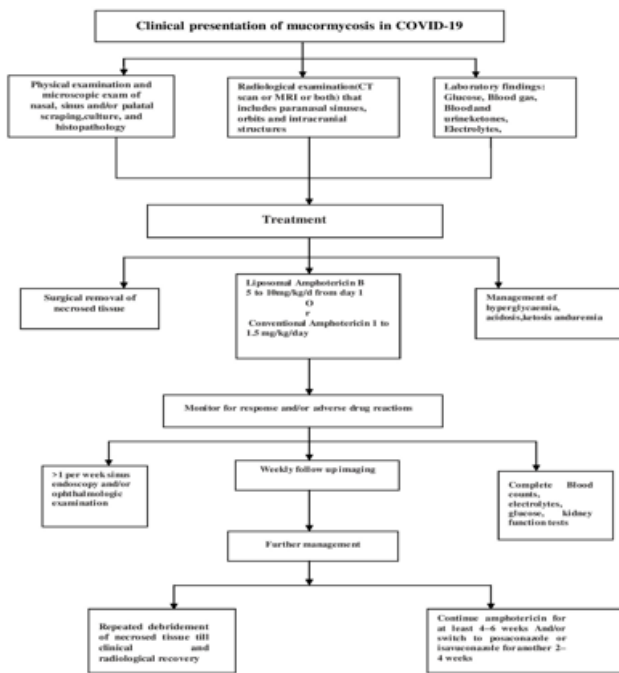


Fig. 1:

1.1. Mucormycosis manifestation in COVID-19 patient

COVID-19 has developed secondary systemic mycoses that have led to serious complications and even death.^{20–23} Mucormycosis infection in humans occurs mainly in

follow and hyphae will increase. As polymorphonuclear leukocytes are much less effective in eliminating hyphae, in immunosuppressed patients, the infection becomes settled in those cases. It further develops as the hyphae start to invade arteries, wherein they spread within the vessel walls and lumens inflicting thrombosis, ischemia, and infarction with dry gangrene of the affected tissues. Hematogenous spread to different organs can take place (lung, brain, etc) and results in sepsis [Figure 1].^{31,33,34}

2.1. Clinical and diagnostic perspectives of COVID-19 associated with mucormycosis

The diagnose of mucormycosis is difficult in clinical and laboratory settings. It is very difficult to isolate and maintain in the laboratory since their poorly septate hyphae can lose the vital cytoplasm at the least manipulation.¹⁶ Mucormycosis is generally diagnosed by direct microscopy or fluorescent brighteners from clinical samples such as sputum, broncho alveolar lavage fluid (BALF), and induced Mucorales hyphae skin lesions or pauci-septate hyphae with a variable diameter of 6–16 μm . To confirm the diagnosis, non-colored noninvasive tissue attacks should be performed on tissue components marked with hematoxylin-eosin (HE), Periodic acid–Schiff (PAS), or Grocottmethenamine silver (GMS) stain. The culture of specimens is strongly suggested for recognition of genus and species, as well AST. It is recommended to be cultured at 30 °C and 37°C separately that usually a white or gray colony will normally be formed, after that morphological recognition of fungi or DNA ordering depend on bar code genes, such as 18S, ITS, 28 s, or rDNA.^{2–26,28,30}

There are two types of investigative tests for the diagnosis of mucormycosis

3. Laboratory Testing

A complete total blood Cells (CBC) should be obtained to diagnose neutropenia. And other tests including blood glucose, bicarbonate, and electrolyte help to detect homeostasis and direct correction of acidosis. Arterial blood gases (ABG) test that can help to determine the level of acidosis and direct corrective treatment. Iron tests have been shown to test the availability of iron mass and have been shown to have high levels of ferritin and low iron binding capacity.²⁶ Other laboratory testing such as mucor stains Potassium hydroxide (KOH) and Calcofluor. Histopathology, fungal culture and Polymerase chain reaction (PCR+) on the basis of molecular finding from biopsied tissue sample are performed and it is also used to confirm the infection and identify the strains involved.^{2–16,28,29,32,35}

4. Radiological Studies

Computed tomography (CT) and magnetic resonance imaging (MRI) should be used for imaging of paranasal sinuses, orbits, brain, and intracranial vessels.^{2–16,24–26,28,29} CT and face imaging should be used as the first diagnosis of rhino cerebral diseases. CT scans can show sinusitis, in addition to orbital and intracranial extension. Magnetic resonance imaging (MRI) of facial and brain sinuses is better than CT scans to assess the extent of tissue attacks and the need for further surgery. Esophagogastroduodenoscopy (EGD) can show areas of tissue necrosis consistent with biopsy. Central CT scan scans or MRI of the CNS can reveal tumors or extend rhino cerebral infection to the brain.²⁶

5. Management

Treatment should be started without delay and consist of antifungal drugs, surgical debridement, and improvement of underlying metabolic abnormalities including hyperglycemia, ketosis, acidosis, and other metabolic abnormalities [Figure 2].

5.1. Medical management

COVID-19 treatment with a combination of specific antifungals may be needed to improve patient survival.²⁰ Treatment for this entity is multifaceted and involves surgical debridement of the affected tissues and antifungal treatment.¹⁹ In a recent study, Amphotericin B and Isavuconazole are two antimicrobial agents approved by the US Food and Drug Administration (FDA) for the primary treatment of mucormycosis. First-line treatment is based on the availability of Amphotericin, which is a liposomal form of Amphotericin B to reduce nephrotoxicity. Other options include Amphotericin B deoxycholate, Isavuconazole, and Posaconazole.²⁶ Intravenous Amphotericin B (lipid formation) is the drug of choice for initial treatment.¹⁷ The dose of liposomal Amphotericin B is 5-10 mg/kg/day and sometimes escalated to 7.5 to 10 mg/kg/day is suggested to achieve good tolerability.^{2–16,27–29,31–37} If the cost of liposomal form of Amphotericin B is a limiting factor then conventional Amphotericin B or Amphotericin deoxycholate can be advised. The efficacy of conventional Amphotericin B/Amphotericin deoxycholate is not lesser to the liposomal form of Amphotericin B, but adverse effect of conventional Amphotericin B is higher than liposomal Amphotericin B. The serum half-life of conventional Amphotericin is 12-24 hours, with a maximum serum concentration of 6 to 8 hours. It is used at a dose of 0.3-1.5 mg / kg /day. It is recommended to start intravenous treatment with a test dose of 1 mg of Amphotericin B.

Other antifungal agent used in the treatment of mucormycosis are Posaconazole (300 mg twice daily upto three days after that 300 mg daily, orally) and Isavuconazole (200 mg twice daily on the first day after that 200 mg

Table 1: Various studies exhibiting the site of infection in mucormycosis.

Author	Site of infection	Inflammatory markers	Inflammatory markers		D-dimer assay		Interleukin		Symptoms
			Value	Normal range	value	Normal range	Value	Normal range	
Mehta S. et al 2020 9	Rhino-Orbital mucormycosis	CRP	29.53 mg/l	<5.0	1547 ng/ml	0-243	IL6-3439 mcg/ml	0-7.0	breathlessness, pyrexia, tachypnea, generalized malaise, conjunctival edema
Monte Junior ESDet al 2020 3	Gastrointestinal mucormycosis	PCT	0.34 nanogram/ml	<0.5	602 ng/ml	0-243	Increase level of IL		fever, nausea, abdominal pain, GI bleeding respiratory dysfunction
Pasero D. et al 2020 4	Pulmonary mucormycosis	CRP- PCT	14.3 mg/dl- 6.91 ng/ml	<5.0- <5.0	1.9 ng/ml	0-243	Increase level of IL		fever, dyspnea, and nausea
Shaghghi S. et al 202010		CRP- ESR	9 mg/l- 57 mm/h	<5.0- 0-15			Increase level of IL		fever, dyspnea, and nausea

CRP: C-reactive protein; ESR: Erythrocyte sedimentation rate; GI: Gastrointestinal; PCT: Procalcitonin

daily). In an open-label study Isavuconazole showed same effectiveness to Amphotericin. Oral formulation can be advised for a long time; up to 6 months. Other antifungal drugs (Fluconazole, Voriconazole, Caspofungin) therapy are not effective in mucormycosis.^{8,25,26}

5.2. Surgical management

Surgical debridement of infected tissue is important and may include partial or complete maxillectomy, mandibulectomy and orbital exenteration. Surgery should be started without delay once the diagnosis has been confirmed.²⁶ Functional endoscopic sinus surgery (FESS) and orbital debulking are generally required surgeries in zygomycosis. Surgery at an early stage is better than delayed for the reason that drugs do not reach the necrotic tissue. Good quality surgical support is crucial for a better result of mucormycosis patients. Follow up endoscopy or surgical examination needs to be repeated on a case-to-case on the basis of treatment response.

The duration of treatment is not well-known and decided on a case-to-case basis. The management with Amphotericin is advised for 4-6 weeks followed by Posaconazole or Isavuconazole for some more weeks as a maintenance therapy.⁸

6. Discussion

Mucormycosis is very rare in healthy persons but several immunocompromised conditions predispose

it. This includes uncontrolled Diabetes Mellitus with or without Diabetes ketoacidosis, hematological and other malignancies, organ transplantation, prolonged neutropenia, immunosuppressive and corticosteroid therapy, hemochromatosis, severe burns, acquired immunodeficiency syndrome (AIDS), malnutrition and open wound following trauma and COVID-19. In this review we have discussed about mucormycosis manifestation in COVID-19 patients. COVID-19 infection can alter the immune system by affecting T lymphocytes, especially CD4 + and CD8 + T cells. Significant depletion of total lymphocytes and especially T cells especially in severe cases of COVID-19 is associated with bad result and may expose patients to a higher risk of developing opportunistic infections such as mucormycosis. Mucormycosis is a fungal disease caused by a group of opportunistic fungi, e.g. mucormycetes. This infection is due to impairment of bronchial alveolar macrophages. In mucormycosis mucrales specific T-cells (CD4 + and CD8 +), which work against mucorales by producing cytokines, such as IL-4, IL-10, IL-17 and IFN- γ , which can directly damage the mucorales hyphae. Mucorales specific T-cell cells are only available in patients affected by invasive mucormycosis and that is a useful diagnostic marker for invasive fungal infection. Excessive exchanges, as well as existing diseases, such as diabetes, pre-existing respiratory disease, use of immunotherapy, the threat of hospital-acquired infections, and mutations in COVID-19 can lead to secondary diseases, which have gradually been

adopted in their analysis of their effects on illness and death. Mucormycosis is defined as an infection and necrosis of host tissue resulting from a vasculature attack by hyphae. Depending on the anatomic site involved, mucormycosis can present as a different types of syndromes, including rhino-orbital-cerebral, pulmonary, cutaneous, and not as much of frequently GI, kidney, and spreaded disease. The prevalence of systemic fungal infections due to opportunistic infections has increased significantly over the past two decades due to the emergence of patients exposed to natural fungi.

7. Conclusion

Patients with COVID-19 are at greater risk of developing fungal disease. COVID-19 is associated with a higher incidence of secondary infections, both bacterial and fungal which may be more likely due to immune effects. In addition, excessive use of steroids / monoclonal antibodies / antibiotics broadly as part of the treatment regimen against COVID-19 could lead to the growth / proliferation of existing fungal infections. Patients with COVID-19 showed an expression of inflammatory cytokines, as well as impaired cell mediated response with diminished CD4 + T and CD8 + T cell counts indicating a tendency to fungal co-infection. Physicians should be attentive of prospect of invasive secondary fungal infections in patients with COVID-19 especially in patients with pre-existing conditions and should allow early diagnosis and treatment to reduce mortality and morbidity. Medication use should be evaluated to achieve the therapeutic effect with the lowest dose and the shortest duration. In order to prevent the occurrence of mucormycosis, rational use of steroids and antibiotics for the shortest duration, glycemic control, and adequate awareness toward ventilators and tubing are necessary.

8. Source of Funding

None.

9. Conflict of Interest

None.

References

- Ehrenreich AW. Mucormycosis with orbital compartment syndrome in a patient with COVID-19. *Am J Emerg Med.* 2021;42(e5):264–8. doi:10.1016/j.ajem.2020.09.032.
- Velavan TP, Meyer CG. The COVID-19 epidemic. *Trop Med Int Health.* 2020;25(3):278–80.
- Yang L, Liu S, Liu J. COVID-19: immunopathogenesis and Immunotherapeutics. *Sig Transduct Target Ther.* 2020;5:128. doi:10.1038/s41392-020-00243-2.
- Singh AK, Singh R, Joshi SR, Misra A. Mucormycosis in COVID-19: A systematic review of cases reported worldwide and in India. *Diabetes Metab Syndr.* 2021;15(4):8137376. doi:10.1016/j.dsx.2021.05.019.
- Jeong W, Keighley C, Wolfe R, Lee WL, Slavin MA, Kong D. The epidemiology and clinical manifestations of mucormycosis: a systematic review and meta-analysis of case reports. *Clin Microbiol Infect.* 2018;25(1):26–34. doi:10.1016/j.cmi.2018.07.011.
- Skiada A, Pavleas I, Apiranthitou MD. Epidemiology and Diagnosis of Mucormycosis: An Update. *J Fungi (Basel).* 2020;6(4):265. doi:10.3390/jof6040265.
- Veisi A, Bagheri A, Eshaghi M, Rikhtehgar MH, Kanavi R, Farjad M. Rhino-orbital mucormycosis during steroid therapy in COVID-19 patients: A case report. *Eur J Ophthalmol.* 2021;p. 11206721211009450. doi:10.1177/11206721211009450.
- Surya N, Kulkarni R, Misra U, Misra UK, Meshram C, Kochar D. Epidemic of Mucormycosis in COVID-19 Pandemic: A Position Paper. *Ann Indian Acad Neurol.* 2021;0(0):0–0. doi:10.4103/aian.AIAN_421_21.
- Mishra N, Mutya V, Thomas A, Rai G, Reddy B, Mohanan AA. A case series of invasive mucormycosis in patients with COVID-19 infection. *Int J Otorhinolaryngol Head Neck Surg.* 2021;7(5):867–70. doi:10.18203/issn.2454-5929.ijohns20211583.
- Galougahi MK, Arastou S, Haseli S. Fulminant mucormycosis complicating coronavirus disease 2019 (COVID-19). *Int Forum Allergy Rhinol.* 2021;11(6):1029–30. doi:10.1002/alr.22785.
- Bouza E, Muñoz P, Guinea J. Mucormycosis: an emerging disease? *Clinical Microbiology and Infection.* 2006;12(7):7–23. doi:10.1111/j.1469-0691.2006.01604.x.
- Revannavar SM, Samaga PSS, Vineeth VK. COVID-19 triggering mucormycosis in a susceptible patient: a new phenomenon in the developing world? *BMJ.* 2021;14(4):8088249. doi:10.1136/bcr-2021-241663.
- Nishanth G, Babu N, Anitha N, Malathi L. Mucormycosis - A Review. *Eur J Mol Clin Med.* 2020;7(3):1786–91.
- Pilmis B, Alanio A, Lortholary O, Lanternier F. Recent advances in the understanding and management of mucormycosis. *F1000Res.* 2018;7(7):6134337. doi:10.12688/f1000research.15081.1.
- Harrill WC, Stewart MG, Lee AG, Cernoch P. Chronic rhinocerebral mucormycosis. *Laryngoscope.* 1996;106(10):1292–9. doi:10.1097/00005537-199610000-00024.
- Chander J, Kaur M, Singla N, Punia R, Singhal SK, Attri AK. Mucormycosis: Battle with the Deadly Enemy over a Five-Year Period in India. *J Fungi (Basel).* 2018;4(2):46. doi:10.3390/jof4020046.
- Junior M, Santos E, Ribeiro M, Luz IB, Baba GO, Hirsch ER. Rare and fatal gastrointestinal mucormycosis (Zygomycosis) in a COVID-19 Patient: A Case Report. *Clin Endosc.* 2020;53(6):746–9. doi:10.5946/ce.2020.180.
- Pasero D, Sanna S, Liperi C, Piredda D, Branca GP, Casadio L, et al. A challenging complication following SARS-CoV-2 infection: a case of pulmonary mucormycosis. *Infection.* 2020;17:1–6. doi:10.1007/s15010-020-01561-x.
- Ballester G, García RG, García CM, Laza LR, Gil FM. Mucormycosis of the head and neck: report of five cases with different presentations. *J Craniomaxillo fac Surg.* 2012;40(7):584–91. doi:10.1016/j.jcms.2011.10.015.
- Calvo GS, Araújo GR, Frases S. Systemic mycoses: a potential alert for complications in COVID-19 patients. *Future Microbiol.* 2020;15:1405–13. doi:10.2217/fmb-2020-0156.
- Mungazi SG, Zambuko B, Muchuweti D, Muguti EG, Mlotshwa S. Fatal haemorrhagic duodenal mucormycosis in a non-immunocompromised host: A case report. *Med Mycol Case Rep.* 2017;17:1–3. doi:10.1016/j.mmcr.2017.05.001.
- Gangneux JP, Bougnoux ME, Dannaoui E, Cornet M, Zahar JR. Invasive fungal diseases during COVID-19: We should be prepared. *J Mycol Med.* 2020;30(2):100971. doi:10.1016/j.mycmed.2020.100971.
- Mehta S, Pandey A. Rhino-Orbital Mucormycosis Associated With COVID-19. *Cureus.* 2020;12(9):e10726. doi:10.7759/cureus.10726.
- Shaghghi S, Daskareh M, Irannejad M, Shaghghi M, Kamel IR. Target-shaped combined halo and reversed-halo sign, an atypical chest CT finding in COVID-19. *Clin Imaging.* 2020;69:72–4. doi:10.1016/j.clinimag.2020.06.038.

25. Greenberg RN, Mullane K, Burik JAV, Raad I, Corcoran G, Anstead G, et al. Posaconazole as salvage therapy for zygomycosis. *Antimicrob Agents Chemother*. 2006;50(1):126–33. doi:10.1128/AAC.50.1.126-133.2006.
26. Sandhu A. Mucormycosis (Zygomycosis) Differential Diagnoses; 2021. Available from: <https://emedicine.medscape.com/article/222551-differential#:~:text=Aspergillosis%2C%20pseudallescheriasis%2C%20fusariosis%2C%20nocardiosis,with%20pseudomonal%20infection%20and%20anthrax..>
27. Spellberg B, Edwards J, Ibrahim A. Novel perspectives on mucormycosis: pathophysiology, presentation, and management. *Clin Microbiol Rev*. 2005;18(3):556–69. doi:10.1128/CMR.18.3.556-569.2005.
28. Baker RD. Mucormycosis; a new disease? *J Am Med Assoc*. 1957;163(10):805–8. doi:10.1001/jama.1957.02970450007003.
29. Prakash H, Chakrabarti A. Global Epidemiology of Mucormycosis. *J Fungi (Basel)*. 2019;5(1):26. doi:10.3390/jof5010026.
30. Song G, Liang G, Liu W. Fungal Co-infections Associated with Global COVID-19 Pandemic: A Clinical and Diagnostic Perspective from China. *Mycopathologia*. 2020;185(4):599–606. doi:10.1007/s11046-020-00462-9.
31. Afroze SN, Korlepara R, Rao GV, Madala J. Mucormycosis in a Diabetic Patient: A Case Report with an Insight into Its Pathophysiology. *Contemp Clin Dent*. 2017;8(4):662–6. doi:10.4103/ccd.ccd_558_17.
32. Potenza L, Vallerini D, Barozzi P, Riva G, Forghieri F, Zanetti E, et al. Mucorales-specific T cells emerge in the course of invasive mucormycosis and may be used as a surrogate diagnostic marker in high-risk patients. *Blood*. 2011;118(20):5416–9. doi:10.1182/blood-2011-07-366526.
33. Wyllie MK. Hyperbaric oxygen therapy for rhinocerebral fungal infection. *J Neurosci Nurs*. 1995;27(3):174–81. doi:10.1097/01376517-199506000-00006.
34. Kumar PK. Mucormycosis. A Black Fungus- Post Covid Complications. *J Regen Biol Med*. 2021;3(4):1–8. doi:10.37191/Maps-ci-2582-385X-3(4)-078..
35. Prakash H, Ghosh AK, Rudramurthy SM, Singh P, Xess I, Savio J, et al. A prospective multicenter study on mucormycosis in India: Epidemiology, diagnosis, and treatment. *Med Mycol*. 2019;57(4):395–402. doi:10.1093/mmy/myy060.
36. Garg D, Muthu V, Sehgal IS, Ramachandran R, Kaur H, Bhalla A. Coronavirus Disease (Covid-19) Associated Mucormycosis (CAM): Case Report and Systematic Review of Literature. *Mycopathologia*. 2021;186(2):289–298.
37. Kontoyiannis DP, Lewis RE. How I treat mucormycosis. *Blood*. 2011;118(5):1216–24. doi:10.1182/blood-2011-03-316430.

Author biography

Abhishek Sharma, Quality Control Officer

Gulnaz Bano, Faculty of Pharmacy Practice

Abdul Malik, Doctor of Pharmacy (Intern)

Cite this article: Sharma A, Bano G, Malik A. Mucormycosis: A manifestation in COVID-19 infection. *Indian J Pharm Pharmacol* 2021;8(3):189-194.