



Case Report

Ocular Prosthesis- after traumatic enucleation of eye

Aditi Verma¹, Sunit Kumar Jurel¹, Pooran Chand¹, Raghuwar Dayal Singh¹,
Ramya S^{1,*}

¹Dept. of Prosthodontics, Faculty of Dental Sciences, King George's Medical University, Lucknow, Uttar Pradesh, India



ARTICLE INFO

Article history:

Received 27-02-2020

Accepted 11-06-2020

Available online 06-08-2020

Keywords:

Ocular prosthesis
fabrication technique
trauma

ABSTRACT

Loss of the facial structures can have a psychological, physical and social impact on those affected people. The aim of the maxillofacial prosthesis is to enhance the patient aesthetics, restore and maintain health of the remaining structures and also provide physical and mental well being. Multidisciplinary approach is required to rehabilitate the ocular defect patients, which may involve psychologist, ophthalmologist and maxillofacial prosthodontics. Fabrication of ocular prosthesis with custom made approach is highly positive, logical, noninvasive, and beneficial approach for ocular trauma patients. Ocular prosthesis helps the patient psychologically as well as esthetically. So, in this case series fabrication technique of ocular prosthesis is described in two cases of traumatic enucleation of eye.

© 2020 Published by Innovative Publication. This is an open access article under the CC BY-NC license (<https://creativecommons.org/licenses/by-nc/4.0/>)

1. Introduction

Absence of an eye or an unfortunate loss may be due to congenital defect or an acquired defect.

Acquired defect could be trauma, tumor, and painful blind eye, and so on,¹ causes aesthetic disfigurement of face. It also significantly affects the individual physical, psychological, emotional, and social well being. Up to 67% of patients with maxillofacial trauma suffers from intraocular injuries.²

Three different surgical modalities for the removal of eye-³⁻⁵ are Evisceration, Enucleation and Exenteration. In evisceration contents of the globe are removed leaving the sclera intact, whereas entire eyeball is removed in enucleation. Exenteration includes the removal of entire orbit including eyelids.

Fabrication of ocular prosthesis is the treatment of such to restore a more normal facial appearance. So in this report step by step fabrication technique of ocular prosthesis is explained.

2. Case Reports

3. Case 1

A 34-year-old female reported to department of Prosthodontics, KGMU Lucknow with the chief complain of unaesthetic appearance due to missing right eye. There was a history of enucleation of right eye due to traumatic injury by pressure cooker explosion. On examination socket was properly healed so fabrication of ocular prosthesis was decided as the treatment plan.

4. Case 2

A 70-year female reported to the Prosthodontics department, KGMU Lucknow with the complain of missing left eye. Enucleation was done due the history of falling injury leading to gradual vision loss of left eye. On examination, it was found that the socket condition was adequate for ocular prosthesis fabrication.

4.1. Clinical Procedure

Careful examination of defected socket was done and treatment plan was made. Procedure explanation and

* Corresponding author.

E-mail address: ramyasrini4u@gmail.com (Ramya S).



Fig. 1: Pre prosthetic view (case-1)



Fig. 2: Pre prosthetic view (case-2)

photographic consent was taken before starting.

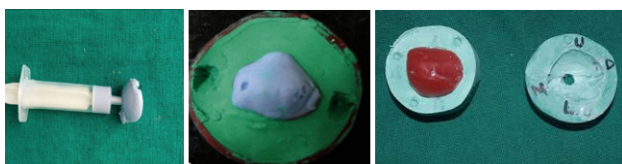
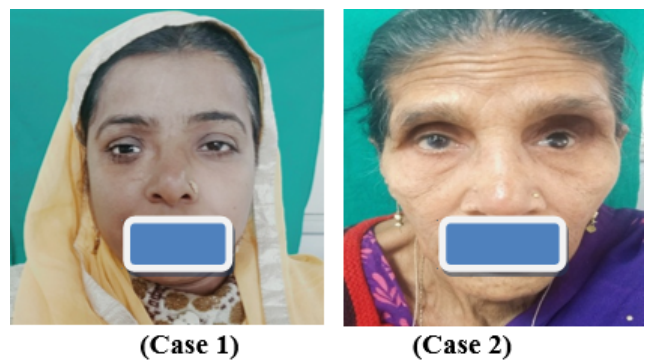

Fig. 3:

1. The procedure was started by selecting the prefabricated perforated stock tray (conformer). Injection syringe was used for holding conformer for taking impression.
2. For taking the impression patient should be upright with the head tilted backward at 45°. This position allows palpebrae and surrounding tissue in natural position relative to the force of gravity.
3. Petroleum jelly was applied on the eyebrows for easy removal of the impression.
4. A thin mix of ophthalmic alginate (Zhermack, Zhermack SpA-Via Bovazecchino, Italy) was made and injected in the syringe which was attached to the tray and then placed into position. For proper tissue recording patient was asked to move her/his normal eye in all direction which helps in adaptation of alginate.
5. Once the impression was examined for accuracy, cast was poured in two parts. Liquified modeling wax was then poured into the cast for fabrication of wax pattern.
6. Wax Pattern was placed in the patient's eye socket and checked for proper fit and contour, this procedure was repeated till we get the proper contours and then iris positioning was done by visual judgement.⁶
7. Investment, flasking and de-waxing was done in adjusted and modified stock eye-wax pattern. We have used red silk fibers to mimic veins in the dough of the determined acrylic shade (SC 10, Pyrax, Roorkee, India) followed by routine curing, finishing and polishing.
8. Once disinfection is done, the properly finished and polished prosthesis was inserted in the socket and minor adjustments were made at the time of delivery as per the patient's comfort and esthetics.
9. Instructions for placement, removal and cleaning of the prosthesis were explained to the patient's and recalled for follow-up.



(Case 1)

(Case 2)

Fig. 4: Post prosthetic view

5. Discussion

Pre fabricated prosthesis is also available but they carry potential disadvantages of poor esthetics, poor fit, and poor eye movements.⁷

Whereas, the custom-made prosthesis gives better contouring, better color matching and coordinated movements with the contralateral eye.

Trauma of eye socket can be due to several reasons that can lead to change in facial symmetry also it leaves psychological impact on patient and can affect the social life. This report explains fabrication method of custom ocular prosthesis in traumatic enucleated cases.

The close adaptation of custom-made ocular prosthesis to the tissue bed provides maximum comfort and restores full physiologic function to the accessory organs of the eye. The insertion and settling of the custom-made ocular prosthesis is comfortable for the patient as it is made according to the contours of the tissue without any forceful application of pressure on to the socket.

Limitations of this technique are it is time consuming method. The color stability of heat cure acrylic resin on long term basis is also questionable.

6. Conclusion

The rehabilitation of patients with enucleation is challenging because of the combination of deformities. So, in this case series we have given Ocular prosthesis in two traumatic enucleation condition which besides improving patient's aesthetics also restore health of the remaining structures and provide physical and mental well being.

7. Source of Funding

None.

8. Conflict of Interest

None.

References

1. Evisceration, Raflo GT. Duane's Clinical Ophthalmology. vol. 5. Philadelphia: Lippincott-Raven; 1995. p. 1–25.
2. Holt JE, Holt GR. Ocular injuries sustained during blunt facial trauma. *Ophthalmology*. 1990;p. 14–22.
3. Parr GR, Goldman BM, Rahn AO. Surgical considerations in the prosthetic treatment of ocular and orbital defects. *J Prosthet Dent*. 1983;49(3):379–85.
4. Bartlett SO, Moore DJ. Ocular prosthesis: A physiologic system. *J Prosthet Dent* . 1973;29(4):450–9.
5. Murphey PJ, Schlossberg L. Eye Replacement by Acrylic Maxillofacial Prosthesis. *Naval Med Bull* . 1944;43:1085.
6. Benson P. Fitting and Fabrication of custom resin artificial eye. *JPD*. 1977;38:532–539.
7. Cain JR. Custom ocular prosthetics. *J Prosthet Dent* . 1982;48(6):690–4.

Author biography

Aditi Verma Junior Resident

Sunit Kumar Jurel Professor

Pooran Chand Professor and Head

Raghuwar Dayal Singh Professor

Ramya S Resident

Cite this article: Verma A, Jurel SK, Chand P, Singh RD, Ramya S . **Ocular Prosthesis- after traumatic enucleation of eye.** *Int Dent J Students Res* 2020;8(2):84-86.