



## Original Research Article

## Evaluation of mandibular indices in panoramic radiography

Hina Handa<sup>1,\*</sup>, Ajita Singh<sup>1</sup><sup>1</sup>Dept. of Oral Medicine & Radiology, People Dental Academy, Bhopal, Madhya Pradesh, India

## ARTICLE INFO

## Article history:

Received 25-05-2020

Accepted 01-06-2020

Available online 06-08-2020

## Keywords:

Mandibular Cortical Index (MCI)  
Mandibular Cortical Width (MCW)  
Panoramic

## ABSTRACT

Aim of the study was to evaluate mandibular indices on a panoramic radiograph.

A number of mandibular cortical indices, including the mandibular cortical index (MCI), mandibular cortical width (MCW) and panoramic mandibular index (PMI), AI (Antegonial index) was evaluated on Panoramic radiograph. Correlation between the indices were also done in our study and we found that PMI with MI and MI with AI were highly significant and showed similar results whereas MCI was non significant with the other indices.

© 2020 Published by Innovative Publication. This is an open access article under the CC BY-NC license (<https://creativecommons.org/licenses/by-nc/4.0/>)

## 1. Introduction

Osteoporosis is defined as “a disease characterized by low bone-mass and microarchitectural deterioration of bone tissue, leading to enhanced bone fragility and a consequent increase in fracture risk. The risk factors for the development of osteoporosis include ageing, menopause, insufficient consumption of foods containing calcium, familial education and decreased physical activity.<sup>1</sup>

Human bones decrease in density and increase in porosity beginning in approximately the third decade of life. It is well known that osteoporosis results in reduced jaw bone mass, as well as alterations of the mandibular structure, especially of the inferior border.<sup>2</sup> There have been reports linking osteoporosis to alterations of the trabeculae displayed on dental radiographs. These findings suggest that dental radiographs may have a useful role in screening patients for osteoporosis. Because radiographic assessment of bone mineral density and bone height is of great value in planning further dental treatment, panoramic or periapical radiographs are routinely made before treatment planning.<sup>3</sup>

Single- or dual-photon absorptiometry, quantitative computed tomography (QCT), single- or dual-energy X-ray absorptiometry (DXA) and quantitative ultrasound are

among the techniques developed to identify individuals with skeletal osteoporosis. Dual-energy x-ray absorptiometry (DXA) is considered to be the reference-standard examination for BMD assessment and the best predictor of fracture risk.<sup>4</sup> DXA is used extensively around the world as it has a high reliability in identifying individuals with low BMD and delivers a low radiation dose.<sup>4</sup>

A number of mandibular cortical indices, including the mandibular cortical index (MCI), mandibular cortical width (MCW) and panoramic mandibular index (PMI), AI (Antegonial index) have been developed to assess and quantify the quality of mandibular bone mass and to observe signs of resorption on panoramic radiographs for identification of osteopenia.<sup>5</sup>

The reliability of the radiomorphometric studies have previously been established by several studies in comparison to DXA.<sup>6</sup> However we are of the opinion that no single morphometric index can solely determine osteoporotic/osteopenic changes consistently.

Compare values of 6 indices and find correlations if any, between the indices to enable more accurate prediction of the osteoporotic changes.

\* Corresponding author.

E-mail address: [hinahanda06@gmail.com](mailto:hinahanda06@gmail.com) (H. Handa).

## 2. Materials and Methods

A cross-sectional study was performed with subjects being patients attending OPD at **People's Dental Academy** and were evaluated with the means of panoramic radiography which were advised as a part of the required dental treatment purpose between January 2010 to May 2011 who met the following inclusion criteria

Patients older than 40 years of age

Patients of both sexes

Patients with no significant medical history

The radiographs that showed the whole mandible, including condyles and hyoid bone without errors in patient preparation, positioning, exposure or development were included in the study

### 2.1. Exclusion criteria

Patients on medication for other systemic diseases.

Patients on drugs such as estrogen, oral bisphosphonates and systemic glucocorticoids that could possibly affect bone metabolism Patients with a mandibular pathology including fracture of mandible and evidence of odontogenic or non-odontogenic pathologies.

### 2.2. Methodology

Digital panoramic radiographs of 75 adult patients who met the following inclusion criteria were obtained by OPG Machine-Planmeca Proline XC with all radiographs being made by a single radiographer with standard exposure parameters.

Vertical orientation line of the machine was aligned with the patient's sagittal plane, with the horizontal line (Frankfort plane) parallel to the floor. Patients >40 yrs of age were further divided into the following age groups. Group I - 40-50, Group II - 50-60, Group III - 60-70, Group IV - 70 TO 80 years. Out Of 75 patients there were 45 males and 31 females. 41 patients were dentate and 26 partially edentulous with more than 1 tooth missing, 8 were completely edentulous.

Each radiographic image was given an identification number in order to allow a blind review by two observers. All radiographs were measured with the inbuilt measurement tool available in the software of the panoramic machine. There was a period of 1 month between readings. Another observer also measured the same radiographs to verify interobserver reliability. To quantify intraobserver agreements, panoramic radiographs were randomly selected from the sample and analyzed by a third observer. The following radio morphometric indices were measured bilaterally on each panoramic radiograph.

### 2.3. Mental index (MI)

It is the measurement of the cortical width at the mental foramen region. A line parallel to the long axis of the mandible and tangential to the inferior border of the mandible was drawn. A line perpendicular to this tangent intersecting the inferior border of the mental foramen was constructed, along which mandibular cortical width was measured with a caliper.<sup>6</sup>

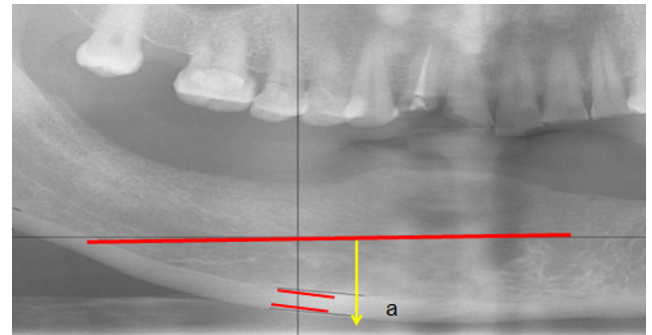


Fig. 1: Mental index

### 2.4. Mandibular cortical index (MCI)

The appearance of the inferior cortex of the mandible was classified as: C1: the endosteal margin of the cortex was even and sharp; C2: the endosteal margin presented semilunar defects (lacunar resorption) or appeared to form endosteal cortical residues; or C3: the cortical layer formed heavy endosteal cortical residues and was clearly porous.<sup>7</sup>

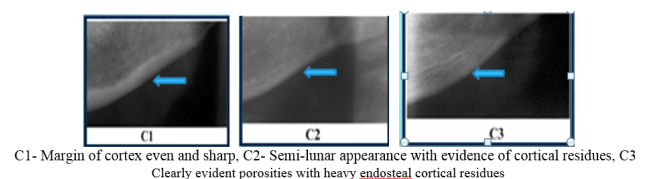


Fig. 2: Mandibular Cortical index

### 2.5. Panoramic Mandibular Index (PMI)

The inferior PMI is the ratio of the thickness of the mandibular cortex to the distance between the inferior margin of the mental foramen and the inferior mandibular cortex

### 2.6. Antegonial index (AI)

It is the measurement of the cortical width in the region anterior to the gonion at a point identified by extending a “best fit” line along the anterior border from the ascending ramus down to the lower border of the mandible.<sup>8</sup>

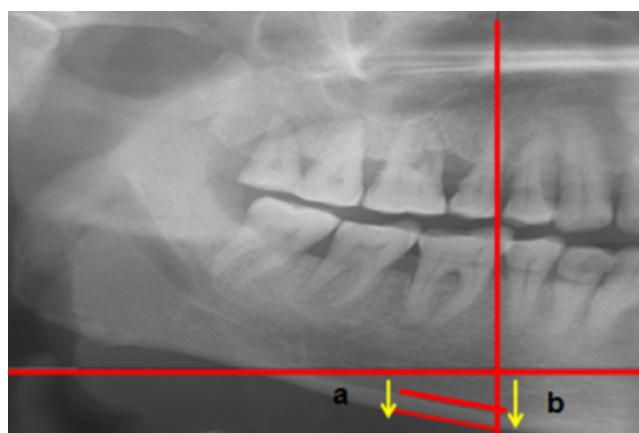


Fig. 3: anoramic mandibular index

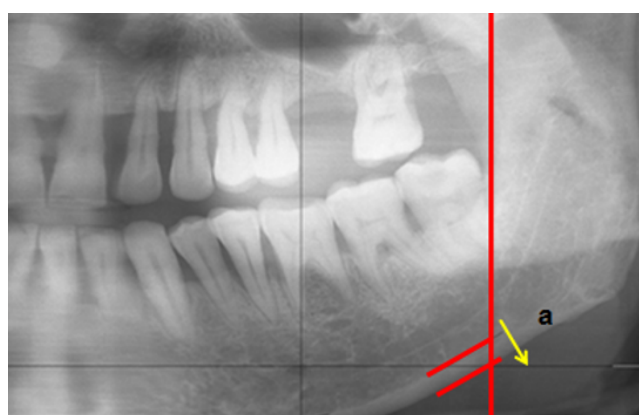


Fig. 4: Antegonial index

Devlin H et al. in their study gave normal ranges of various mandibular indices and these values were set as standard for grading the patients into the following groups.

1. Normal
2. Osteoporotic

Table 1: Delvin H et al. Depicting normal range of indices value

Mandibular indices	Normal Range
Antegonial index	≥ 3.2 mm
Panoramic mandibular index	≥ 0.3
Mental index	≥ 3.1 mm
Mandibular cortical width	≥ 3 mm

### 3. Results

Comparison of mean value of indices among age group was done and it was found that

The value for age group was significant for antegonial index and mental index and was insignificant for panoramic index.

Table 2: Indices depicting age group between the various indices.

Antegonial index	Sig = .027
Mental index	Sig=.044
Panoramic index	Sig= .196

Comparison of mean values of indices among male and female groups

Table 3: Indices comparing gender difference between the groups

Mental index	Sig=.297 Non significant
Panoramic index	Sig= 0.980 Non significant
Antegonial index	Sig=.067 Non significant

No statistically significant difference in the mean value of all the indices between male and female. Comparison of mean values of indices among dentate, partially edentulous and edentulous groups

Table 4: Comparing indices value among dentate, edentulous and partially edentulous group

Antegonial index	Sig=.016 significant
Mental index	Sig=.05 significant
Panoramic index	Sig=.022 is significant

In the group of comparison between the following indices(PMI,MI,AI,MCI) the results are highly significant for all the three indices.

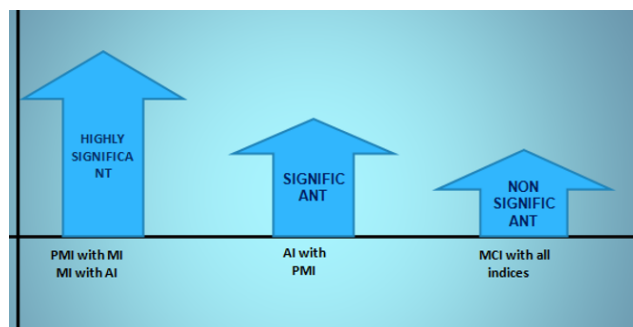


Fig. 5: Comparison of indices with normal and osteoporotic group

The following diagrams depicts the relation of normal group and the osteoporotic group with the following indices

#### 3.1. Mandibular Cortical Index

### 4. Discussion

Several panoramic radiographic measurements, also known as panoramic radio morphometric indices, have been developed to assess cortical shape and width, either qualitatively or quantitatively.<sup>7</sup>

In our study it was found that with increasing age (60-70 and 70-80 years) there was decrease in the value of

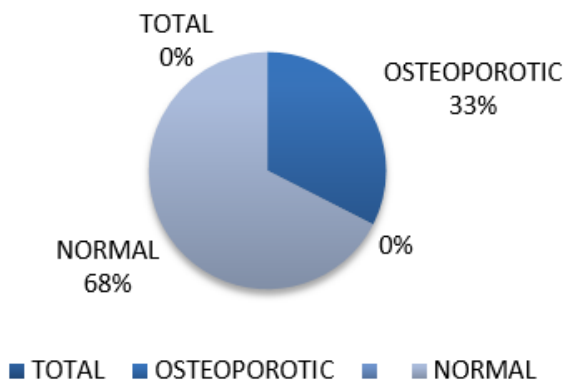


Fig. 6: Antegonial Index (Normal value:  $\geq 3.2\text{mm}$ )

■ OSTEOPOROTIC ■ NORMAL

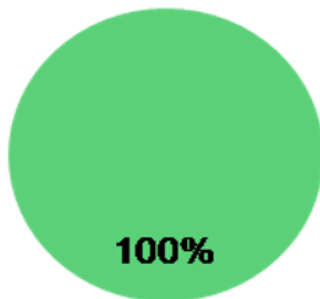


Fig. 7: Mental Index (Normal value:  $\geq 3.1\text{mm}$ )

Normal

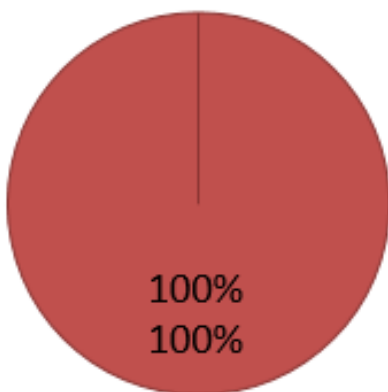


Fig. 8: Panoramic mandibular index (Normal value:  $\geq 0.3$ )

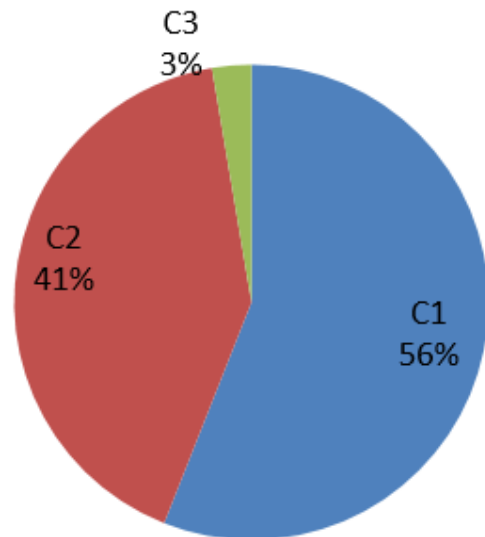


Fig. 9: Mandibular Cortical Index -C3-56%

PMI, AI and MI and was highly significant for MI and AI. Comparison of mean values of indices among male and female groups and it was statistically significant for Antegonial index only whereas PMI and MI showed no difference between gender groups.

Similarly Dutra et al in his study also compared the AI and MI values on 312 panoramic radiographs in terms of sex and age, and reported that there was a notable decrease in antegonial bone thickness among elderly females and that resorption was lower among elderly males.<sup>9</sup>

In our study comparison of mean values of indices among dentate, partially edentulous and edentulous groups was also done in which it was found that the value was significant for all the indices and was found that edentulous individuals have lower indices value as compared to dentate individual.

Study by Ledgerton<sup>8</sup> et al showed a significant relationship between dental status and

the MCW, PMI, and MCI indices. In another study by Uysal<sup>10</sup> et al MCI was found to be significantly affected by the status of dentition. Our study also had findings similar to Knezovic-Zlataric et al<sup>11</sup> found no difference in the distribution of women and men between MCI categories C2 and C3. He also reported that the age-related distribution of MCI showed an age-related increase in the numbers of individuals with C3 cortex appearance.<sup>11</sup>

Benson et al<sup>5</sup> in his study evaluated the MI according to age, race and sex, and observed that mandibular cortical bone thickness decreased with age and the amount of resorption was higher among women. Similarly in our study it was found that on comparing MI and PMI with age race and sex it was found that with increasing age their occurs diff in bone thickness and with gender predilection no such discrepancy is noted. Amount of resorption was more with

dentate individual as compared to edentulous patients.

Correlation between the indices were also done in our study and we found that PMI with MI and MI with AI were highly significant and showed similar results whereas MCI was non significant with the other indices.

## 5. Source of Funding

None.

## 6. Conflict of Interest

None.

## References

1. Lee BD, White SC, White NC. Age and trabecular features of alveolar bone associated with osteoporosis. *Oral Surg Oral Med Oral Pathol Oral Radiol Oral Endod*. 2005;100:92–8.
2. Horner K, Devlin H. Clinical bone densitometric study of mandibular atrophy using dental panoramic tomography. *J Dent*. 1992;20(1):33–7.
3. ShROUT MK, Hildebolt CF, Potter BJ, Brunson TKB, Pilgram TK, Dotson M, et al. Comparison of Morphological Measurements Extracted From Digitized Dental Radiographs With Lumbar and Femoral Bone Mineral Density Measurements in Postmenopausal Women. *J Periodontol*. 2000;71(3):335–40.
4. Dagistan S, Bilge OM. Comparison of antegonial index, mental index, panoramic mandibular index and mandibular cortical index values in the panoramic radiographs of normal males and male patients with osteoporosis. *Dentomaxillofac Radiol*. 2010;39(5):290–4.
5. Benson BW, Prihoda TJ, Glass BJ. Variations in adult cortical bone mass as measured by a panoramic mandibular index. *Oral Surg, Oral Med, Oral Pathol*. 1991;71:349–56.
6. André Ferreira Leite Correlations between seven panoramic radiomorphometric indices and bone mineral density in postmenopausal women. *Med Oral Pathol Oral Radiol Endod*. 2010;109:449–56.
7. Klemetti E, Kolmakov S, Kröger H. Pantomography in assessment of the osteoporosis risk group. *Eur J Oral Sci*. 1994;102(1):68–72.
8. Ledgerton D, Horner K, Devlin H, Worthington H. Radiomorphometric indices of the mandible in a British female population. *Dentomaxillofac Radiol*. 1999;28(3):173–81.
9. Arifin AZ, Asano A, Taguchi A, Nakamoto T, Ohtsuka M, Tsuda M, et al. Computer-aided system for measuring the mandibular cortical width on dental panoramic radiographs in identifying postmenopausal women with low bone mineral density. *Osteoporos Int*. 2006;17(5):753–9.
10. Uysal S, Rankaya BLC, Hatipou MG. Do gender and torus mandibularis affect mandibular cortical index? A cross-sectional study. *Head Face Med*. 2007;3:37.
11. Zlatarić DK, Celebić A, Lazić B, Bačić I, Komar D, Stipetić-Ovcaricek J, et al. Influence of age and gender on radiomorphometric indices of the mandible in removable denture wearers. *Coll Antropol*. 2002;26:259–66.

## Author biography

**Hina Handa** Reader

**Ajita Singh** Senior Lecturer

**Cite this article:** Handa H, Singh A. Evaluation of mandibular indices in panoramic radiography. *Int Dent J Students Res* 2020;8(2):60–64.