

# Natural Rehabilitation of Fractured Anterior Tooth Using Reattachment, a Single Visit Endo- Esthetic Approach- A Case Report.

Vinay Bal Singh Thakur<sup>1</sup>, Kanika Gupta<sup>2</sup>, Ishant Sood<sup>2</sup>, Pallavi Mishra<sup>3</sup>, Haritima Kashi<sup>4</sup>, Kritika Gupta<sup>2</sup>

<sup>1</sup>Senior Resident, HDC, Sundernagar.

<sup>2</sup>Post Graduate, HDC, Sundernagar.

<sup>3</sup>BDS, HDC, Sundernagar.

<sup>4</sup>MDS, HDC, Sundernagar.

Received: December 2016

Accepted: December 2016

**Copyright:** © the author(s), publisher. Annals of International Medical and Dental Research (AIMDR) is an Official Publication of "Society for Health Care & Research Development". It is an open-access article distributed under the terms of the Creative Commons Attribution Non-Commercial License, which permits unrestricted non-commercial use, distribution, and reproduction in any medium, provided the original work is properly cited.

## ABSTRACT

Anterior teeth crown fracture of a growing child requires immediate attention, not only because of damage to the dentition but also due to unsightly smile and facial appearance affected by trauma to the child. Thus esthetic management of anterior tooth fracture has been one of the most important aspects of dentistry and when it has to be done using the tooth's own structure, it sounds psychologically more acceptable. And with the development of resin-based materials that offer high bond strength values, it has made possible to undoubtedly go for reattachment technique with ease.

For further simplification, single visit rotary endodontics using ProTaper Universal system is recommended as it is designed to offer better features like flexibility and less chairside time than hand instrumentation. Presented here is one such case in which a combination of single visit rotary endodontics and adhesive reattachment using flowable composites has been carried out to reframe the broken tooth and comply with the patient's concern. The treatment was found to be successful both functionally and aesthetically at the 18-month follow-up.

**Keywords:** Crown fracture, aesthetic management, adhesive reattachment, single visit rotary endodontics.

## INTRODUCTION

Traumatic dental injuries (TDIs) occur frequently in children and young adults, comprising 5% of all injuries.<sup>[1]</sup> Crown fracture present almost 92% of all traumatic injuries of the permanent teeth. The anterior incisors are most often affected (80% central incisors and 16 % lateral incisors) because of the anterior position of the maxilla and tooth protrusion.<sup>[2]</sup> Most dental injuries to primary teeth occur between 2 and 3 years due to lack of experience and motor coordination when child begins to walk and tries to run. Injuries to permanent teeth occur mostly at 8 to 12 years of age due to frequent involvement of teenagers in contact sports, automobile accidents, outdoors activities and falls.<sup>[3]</sup>

### Name & Address of Corresponding Author

Dr. Vinay bal singh thakur  
Himachal dental college,  
Sundernagar,  
Distt mandi, Himachal pradesh. pin code: 175002.

Several factors influence the management of coronal tooth fractures, including extent of fracture

(biological width violation, endodontic involvement, alveolar bone fracture), pattern of fracture, root development, presence/absence of fractured tooth fragment and its condition for use, occlusion, time passed since trauma and materials used for reattachment, esthetics and finances.<sup>[3,4]</sup> A trauma with accompanying fracture of anterior teeth is a tragic experience for the young patient, not only because of damage to the dentition but also because of psychological effect of the trauma to the child and his parents.<sup>[5]</sup>

Various treatment modalities have been practiced in past to restore the fractured anterior teeth including composites, laminates, esthetic crown, or the reattachment of fractured fragment. Among which reattachment of fractured tooth fragment is considered one of the most conservative, biologic and esthetic approach (in terms of shape, contour, surface texture, occlusal alignment and color) provided fracture tooth fragment is retained. Chosack and Eidelman were the pioneer of such procedure in dentistry who used a cast post and conventional cement to reattach an anterior crown segment on a 12-year-old boy.<sup>[3]</sup> Tennery (1988) was the first to report the reattachment of a fractured fragment using acid-etch technique.<sup>[6]</sup> Adhesive

reattachment requires minimum healthy tooth reduction and has a predictable esthetic result. It is usually faster than a complete composite restoration, and triggers a strong emotional effect because the patient feels relief by keeping one's own natural tooth.<sup>[7]</sup>

The development of resin-based materials that offer high bond strength values has made it possible to reattach the fragments by employing the modern dentin bonding agents or adhesive luting systems without imposing an additional retentive preparation of the tooth or fragment. Some researchers have investigated the reattachment using bonding agents alone, or bonding agents with flowable resins, dual cured, self-cured or light-cured luting cements.<sup>[8]</sup>

One of the best approach for managing coronal tooth fractures, especially when there is no or minimal violation of the biological width, is the reattachment of the dental fragment when it is available.<sup>[9]</sup>

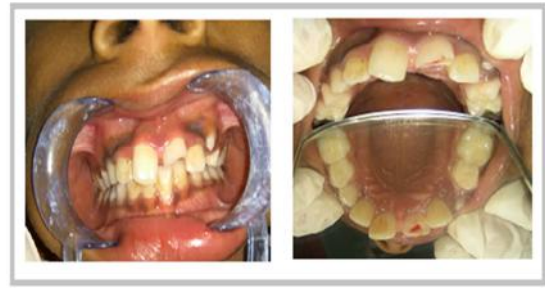### CASE REPORT

A 10 year old male presented to the department of Pedodontics and Preventive Dentistry, Himachal Dental College, Sundernagar with the chief complaint of broken upper front teeth and pain in same region. The patient gave significant history of trauma 3 days back while playing and was able to retain the tooth fragment that was stored in milk. The medical history of the child was found to be non-relevant. Extraoral examination revealed no soft tissue injury and a little swelling was observed on upper lip. On intra-oral clinical examination, fractured upper left central incisor with pulpal exposure site was seen and the tooth was tender. The diagnosis was made on the basis of Classification by World Health Organization in its application of International Diseases of Dentistry and Stomatology (1994) as complicated crown fracture (N 502.52) involving enamel and dentin, and exposing the pulp [Figure 1]. Transient midline diastema was also noticed that required no obvious treatment. Parents were concerned for their child's esthetics, so they enquired if the reattachment of the broken tooth fragment was possible. As per the need of the hour and patients demand to naturally rebuild the tooth as soon as possible, a very conservative approach of reattachment of the retained tooth was carried out following single visit rotary endodontics [Figure 2].

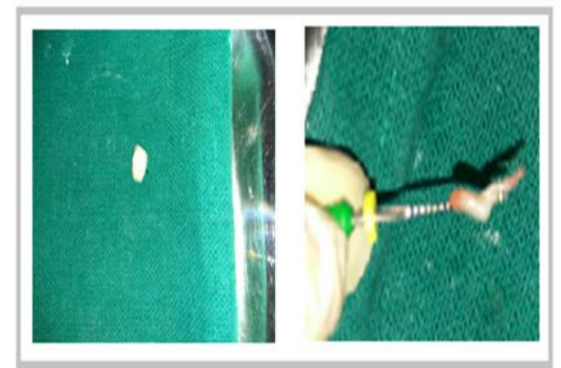
#### Procedure

An immediate endodontic intervention followed by bonding of the fractured segment using the acid etch technique was planned. Single-visit rotary endodontics was performed for the fractured central incisor. Following the delivery of local anesthesia (2% lidocaine) and isolation with rubber dam, coronal access through the palatal enamel with a round diamond bur was prepared and root canal was explored with a 25-mm long 0.02 tapered K file size

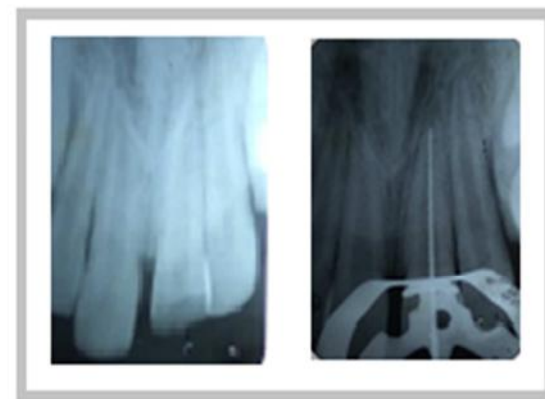
# 15 (Dentsply/Maillefer, Ballaigues, Switzerland) based on the pre-operative radiographs [Figure 3].



**Figure 1: A: Preoperative clinical photograph, B: Complicated crown fracture involving enamel, dentin and exposing pulp.**



**Figure 2: A: Retained broken tooth fragment B: Pulp extirpation.**

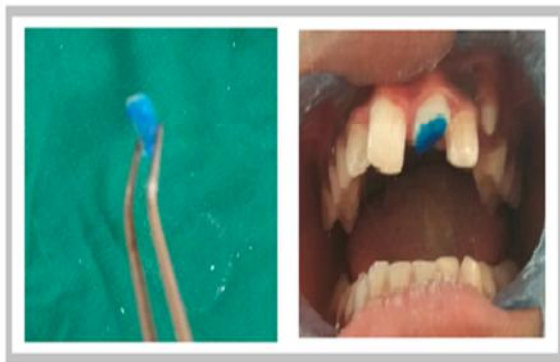

**Figure 3: A: Preoperative radiograph, B: Working length radiograph.**

The loose depth of the 15 file was measured and this length was transferred to the ProTaper Universal system (Maillefer Corp., Ballaigues, Switzerland) S1 and S2 files. After working length determination, biomechanical preparation was carried out using crown down technique by firstly shaping the coronal two-thirds utilizing S1, then S2 attached to an electric handpiece (XSmart- Maillefer Corp., Ballaigues, Switzerland) set at 300 rpm and 3 N/cm torque. Copious irrigation of the root canal was intermittently done with sodium hypochlorite and

normal saline. Following the use of each Shaping file, irrigation, recapitulation with a 15 file to break up debris, and move it into solution, then re-irrigate. Without pressure, and in one or more passes, S1, then S2, was used in this manner until the depth of the 15 hand file was reached. The root canals were instrumented up to size F2 file.

After that, the canals were dried and filled with size F2 gutta-percha cones (Dentsply Ind. e Com. Ltda., Petrópolis, Brazil) and AH Plus sealer cement [Figure 5A]. Now, the pulp chamber was partially filled with restorative Glass Ionomer Cement. Then, the tooth fragment and the remaining tooth structure were prepared for bonding. An enamel bevel was prepared all around the remaining tooth structure as well as the fractured margin of the segment and the fragment was reapproximated to check its fit. An additional internal dentinal groove was also prepared within the dentine of the fractured fragment part. Acid etching of the access cavity and the approximating surfaces of the two segments were carried out for 20 s with 37% phosphoric acid.



**Figure 4: Etching two broken tooth fragments with 37% phosphoric acid.**

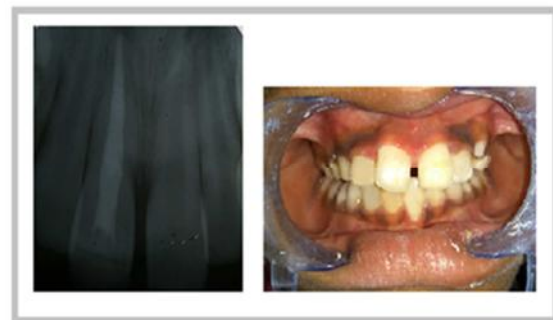Bonding agent (Gluma) was subsequently applied and light cured for 10 s. Then, flowable composite (3M ESPE Filtek™ Z350) was applied into the dentinal groove and on the approximating surfaces of the fragment and the remaining tooth. Both the fragments were reapproximated and light cured for 40 s each from the buccal and lingual aspects of the tooth. Flowable composite was applied over the bevel all around the tooth and was light cured appropriately. Finishing and polishing of the tooth was done using super snap mini kit (shofu) and rubber cup with pumice paste [Figure 5B]. The patient came for recall visits at 3, 6, 12 and 18 months and the tooth was found to be intact and functional inside the oral cavity in all the four visits.

## DISCUSSION

Reattachment of the fragment to its original position is considered an excellent approach for the management of a coronal fracture. The application

of dental adhesives capable of reattaching a fragment to the remaining tooth structure appears to offer a number of advantages compared with the conventional methods for restoring fractured teeth.<sup>[10]</sup> Trauma to anterior teeth is a relatively common occurrence, but it has been found that there is a positive emotional and social response from the patient to the preservation of natural tooth structure.<sup>[11]</sup>

With the advent of rotary endodontics, ProTaper files are commonly in use because when compared to other file systems, it has changing percentage tapers over the length of its cutting blades that serves to significantly improve flexibility, cutting efficiency, and safety. It's convex, triangular cross-section enhances the cutting action while decreasing the rotational friction between the blade of the file and dentin. The ProTaper Shaping files are allowed to be used like a brush, to laterally and selectively cut dentin on the outstroke and passively follow the glide path to optimize safety and efficiency.<sup>[12]</sup> Flexible files rotating in a curved canal require unimpeded space, and widening this space from the crown down seems the logical solution.



**Figure 5: A: Post operative radiograph, B: Post operative clinical photograph.**

In the present case, as the fractured fragment was intact, use of natural tooth substance clearly preserved occlusal contacts and eliminated problems of differential wear of restorative material, unmatched shades and difficulty of contour and texture reproduction associated with other restorative techniques.<sup>[13]</sup> Transient midline diastema was also noticed that required no definitive treatment since the ugly duckling stage is self-correcting, once the permanent canines are completely erupted. Essential advantages of the reattached teeth are that all the alternative methods as direct adhesive resin reconstruction, veneers and crowns can be performed in case of failure.<sup>[2]</sup> Successful reattachment is highly dependent upon the rapid retrieval of the fragment, which should be preserved in physiologic solution (saline or milk) in order to avoid any change in colour due to dehydration.<sup>[14]</sup> The longer the fragment remains dehydrated the poor tooth's strength will be. 2 In this case, the fractured fragment was stored in milk until

reattachment was done, and no discoloration was observed during the post treatment follow up examinations.<sup>[13]</sup> Since the patient visited the clinic after 72 hours of trauma, vital pulp therapies like pulp capping or pulpotomy cannot be performed as the inflammation due to bacterial contamination is supposed to spread through the radicular pulp and so it needs to be extirpated completely by root canal therapy.

The quality of fit (fragment's adaptation to the remaining structure) between the segments is clinically important factor for the longevity of the reattached crown. Cavaller et al reported that reattachment of the crown fragment appeared to have a better long term prognosis than composite resin restoration.<sup>[15]</sup> Modifications to both tooth and fragment prior to bonding have been proposed, with an estimated recovery of fracture resistance up to 97%. Theoretically, these techniques (dentin groove, bevel, chamfer, or overcontour) remove fractured enamel prisms and retain prisms that are in a favourable position for effective etching.<sup>[7]</sup> An additional long-term study of 50 incisal fragment reattachments reported an 80% success rate at 5 years when incisal fragments of approximately one-half the length of maxillary central incisors were replaced using acid-etching, internal V-shaped notches, bonding agents, and a visible-light cured composite. Andreasen and Andreasen stated that the reattachment procedure may importantly serve as a transitional treatment alternative for pre-teens or teenage patients to postpone definitive treatment until an age where gingival margin contours are relatively stable.<sup>[16]</sup>

According to Basuttill and Fung, when the child's age shows immature development of the fractured tooth's gingival margins, the application of more conservative methods for reconstruction, such as reattachment, are desirable.<sup>[2]</sup> In cases where the patient is undergoing fixed orthodontic treatment or is likely to undergo fixed orthodontic treatment in the near future, the reattachment technique allows performing such treatment and seems to be advantageous and reliable as reported by Simonsen.<sup>[9]</sup> This treatment requires less chair time and minimum patient compliance. No complications were experienced during 18 months follow-up. Longer follow up periods are required to monitor the efficacy of the technique.

And because single visit rotary endodontics using ProTaper Universal system is designed to offer better features like flexibility, efficiency, safety, simplicity and is faster than hand instrumentation so in this case, endodontic therapy (using protaper universal system) was followed by reattachment of the fractured fragment using flowable composite.

## CONCLUSION

The natural fragment reattachment procedure may represent a conservative, cost-effective, aesthetic and a viable restorative first treatment option especially when younger patients present with coronal fractures of the anterior teeth and intact incisal edge segments. Moreover, to complete the procedure more effectively and in lesser period of time, rotary endodontics using Protaper Universal system proved remarkably helpful.

## REFERENCES

1. Dental trauma guidelines. International Association of Dental Traumatology 2012
2. Belcheva A. Reattachment of fractured permanent incisors in schoolchildren: review 2008; 14(2)
3. Saha R. Reattachment of Fractured Anterior Tooth: A Case Report. *Int J Dent Med Res* 2015;1(6):113-115
4. Macedo GV. Reattachment of Anterior Teeth Fragments: A Conservative Approach. *J Esthet Restor Dent* 2008; 20:5-20
5. Hegde RJ. Tooth fragment reattachment - an esthetic alternative : Report of a case. *Indian Soc Pedo Prey Dent* September 2003; 21(3):117-119
6. Bele AD, Jain D, Gautam A. Reattachment of Fractured Tooth Fragment in Maxillary Anterior Teeth: An Esthetic Approach. *J Oral Health Comm Dent* 2014;8(3):184-187
7. Lise DP et al. Tooth Fragment Reattachment: The Natural Restoration Operative Dentistry 2012; 37(6): 584-590
8. Davari AR, Sadeghi M. Influence of Different Bonding Agents and Composite Resins on Fracture Resistance of Reattached Incisal Tooth Fragment. *J Dent Shiraz Univ Med Sci.* March 2014; 15(1): 6-14
9. Goenka P, Sarawgi A, Dutta S. A conservative approach toward restoration of fractured anterior tooth. *Contemporary Clinical Dentistry* April 2012; Vol 1
10. Martos J. Crown fragment reattachment in anterior-fractured tooth: A five-year follow-up. *European Journal of General Dentistry* May-August 2012; 1(2)
11. Nujella BP, Kumari S. Reattachment of complicated tooth fracture: An alternative approach. *Contemporary Clinical Dentistry.* Apr-Jun 2012; 3(2)
12. Ruddle CJ. The ProTaper technique: Shaping the future of endodontics. *Endodontics International* Feb 2009
13. Agrawal A. Reattachment of Anterior Teeth Fragments with Two Different Treatment Techniques: Report of Two Cases *International journal of dental clinics* 2011; 3(1):107-108
14. Qureshi A et al. Reattachment of coronal fragment using fiber reinforced post. *IJMDS* January 2015
15. Pathak RV, Mute W, Sheno P. Immediate Reattachment of fractured tooth fragment using prefabricated post and composite - A case report *endodontology*
16. Murchison D F, Burke F J T & Worthington R B. Restorative Dentistry: Incisal edge reattachment: indications for use and clinical technique. *British Dental Journal* 1999; 186: 614 - 619.

**How to cite this article:** Thakur VBS, Gupta K, Sood I, Mishra P, Kashl H, Gupta K. Natural Rehabilitation of Fractured Anterior Tooth Using Reattachment, a Single Visit Endo- Esthetic Approach- A Case Report. *Ann. Int. Med. Den. Res.* 2017; 3(1):DE13-DE16.

**Source of Support:** Nil, **Conflict of Interest:** None declared