



## Original Research Article

## Management of comminuted intertrochanteric fractures with TFN -A (Trochanteric Femoral Nailing - Advanced) in elderly patients – A prospective study

Arunodhaya Siddartha S<sup>1</sup>, Pramod B M<sup>1</sup>, Tushar Pimpale<sup>1</sup>, Mayur Chandrashekar<sup>1,\*</sup>, Mruthyunjaya<sup>1</sup>

<sup>1</sup>Dept. of Orthopedics, JSS Medical College & Hospital, Mysuru, Karnataka, India



## ARTICLE INFO

## Article history:

Received 28-02-2021

Accepted 01-06-2021

Available online 12-06-2021

## Keywords:

Intertrochanteric fractures  
Trochanteric femoral nail- advanced (TFN-A)  
Dynamic hip screw  
KYLE's criteria

## ABSTRACT

**Background:** A study was undertaken to evaluate the surgical management of intertrochanteric fractures with Trochanteric Femoral Nailing – Advanced design as a fixation device, and to determine the rate of union, complications, operative risks and functional outcome of intertrochanteric fractures in elderly patients.

**Materials and Methods:** The fractures were classified according to BOYD and GRIFFIN classification system. 40 patients of intertrochanteric fractures fulfilling the inclusion and exclusion criteria, were managed surgically using Trochanteric Femoral Nail – Advanced. The results were analyzed according to age, type of fracture, operative details and functional outcome using KYLE's criteria.

**Results:** Totally 40 patients with intertrochanteric fractures were operated with TFN-A and were included in the study. The mean age of the patients was around 74.97 years with minimum age being 54 years and the maximum being 92 years. The mean duration of operation was recorded to be 59.69 mins. Complications in this study were seen in 4 patients (10%). Complication was surgical site infection 2 patients (5%), helical blade back out 1 patient (2%), greater trochanteric fracture 1 patient (2%).

**Conclusion:** Trochanteric Femoral nailing-advanced is a versatile implant for all comminuted intertrochanteric fractures, especially in elderly and osteoporotic patients in terms of operating time, surgical exposure, blood loss, and complication rates.

© This is an open access article distributed under the terms of the Creative Commons Attribution License (<https://creativecommons.org/licenses/by/4.0/>) which permits unrestricted use, distribution, and reproduction in any medium, provided the original author and source are credited.

## 1. Introduction

With ageing, intertrochanteric fractures are very common. These fractures occur as a result of osteoporosis and cause a significant impact on the activities of daily living of the patient.<sup>1</sup> Intertrochanteric fractures constitute a major chunk of the orthopaedics surgical procedures and are considered to be a major reason for mortality. Literature states as high as 5% mortality at the end of 1 month and 15% at the end of 6 months after the surgery.<sup>1,2</sup> Hence, in these patients avoiding bed ridden complication by accelerating fracture union and supported mobilization becomes our main aim.

The surgical treatment of intertrochanteric fractures remains a matter of debate. The biomechanical advantages of intramedullary (IM) implants make Gamma nail (GN) and proximal femur nail (PFN) an attractive option, especially in unstable fractures.<sup>3</sup> Initial reports have suggested that IM nails may have an advantage over side plate devices in unstable fractures but have not demonstrated a clear superiority and have a reported complication rate of around 20%.<sup>4</sup> The incidence of neck screw cut out has reduced considerably with improvements in the surgical technique but still remains the most common mode of fixation failure with IM implants.<sup>5,6</sup>

Trochanteric femur nail Advanced (TFN-A) is a new internal fixation system that was recently developed and is

\* Corresponding author.

E-mail address: [mayurc02@gmail.com](mailto:mayurc02@gmail.com) (M. Chandrashekar).

now applied widely in various intertrochanteric fractures.<sup>5</sup> It is particularly suitable for old patients with osteoporotic and complex fractures because it involves minimal exposure and reduced perioperative blood loss and gives us a biological fixation. The major development in this process is the helical blade, which is supposed to compress the surrounding cancellous bone in the femoral neck and stabilize the head and neck fragment during insertion of the blade. The TFN-A has a small distal shaft diameter, resulting in a lower concentration of stress in the tip. The complication rate is quoted as being from 15% to 20%, with the most common mode of failure being screw or blade cut-out.<sup>7</sup> In biomechanical studies, the spiral blade of the trochanteric femoral nail Advanced has shown a superior cut-out resistance, which may translate into fewer cut-outs in the clinical setting.<sup>8</sup>

## 2. Objective

To assess the functional and radiological outcome of comminuted intertrochanteric fractures treated with TFN-A using Kyle's criteria.

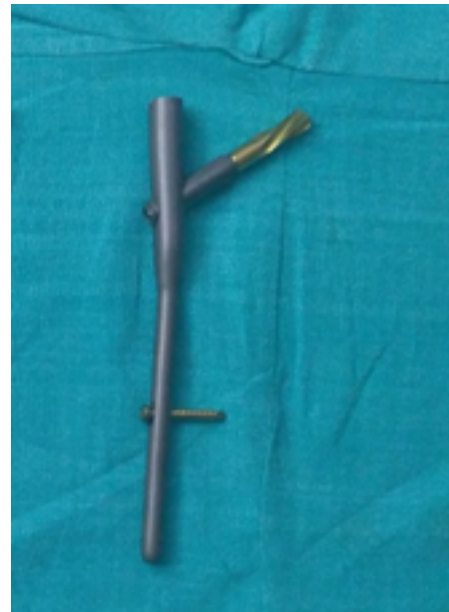## 3. Materials and Methods

With a level IV evidence, a prospective study was carried out from September 2016 and April 2018 in department of Orthopaedics, JSS Medical College & Hospital, Mysuru. A total of 40 patients with comminuted intertrochanteric fractures with TFN -A (Trochanteric Femoral Nailing - Advanced) in elderly patients and were followed up at the immediate post op period and at the end of 1<sup>st</sup>, 2<sup>nd</sup>, 3<sup>rd</sup>, and 6 months and evaluated for functional outcome using Kyle's criteria.

Patients with age equal to or more than 50 years and patients with type II, III and IV Boyd and Griffin classification were included in the study. Patients with age less than 50 years, patients with type I Boyd and Griffin classification and patients who are unfit and not willing for surgery were excluded from the study.

TFN-A device is a stainless steel/titanium reconstruction nail. All the patients had implantation of 200 mm / 170 mm nail length measuring 9/10/11 mm in diameter and having a blade-nail angle of 130°. The proximal nail angle in the coronal plane is 6° to match human anatomy. An aiming device is used to achieve distal locking by inserting a screw through a hole which can be used as static locking or dynamic locking depending on the fracture reduction. The cephalic end of the device is a helical blade whose shape precludes rotation once locking is achieved but allows back-out to obtain compression of the fracture site.

All patients were initiated with active and passive exercises within 48 hours of surgery. All the patients were advised to completely bear weight after 10 – 12 weeks of post operative period. All patients were followed up at the



**Fig. 1:** Assembly of trochanteric femoral nailing - advanced

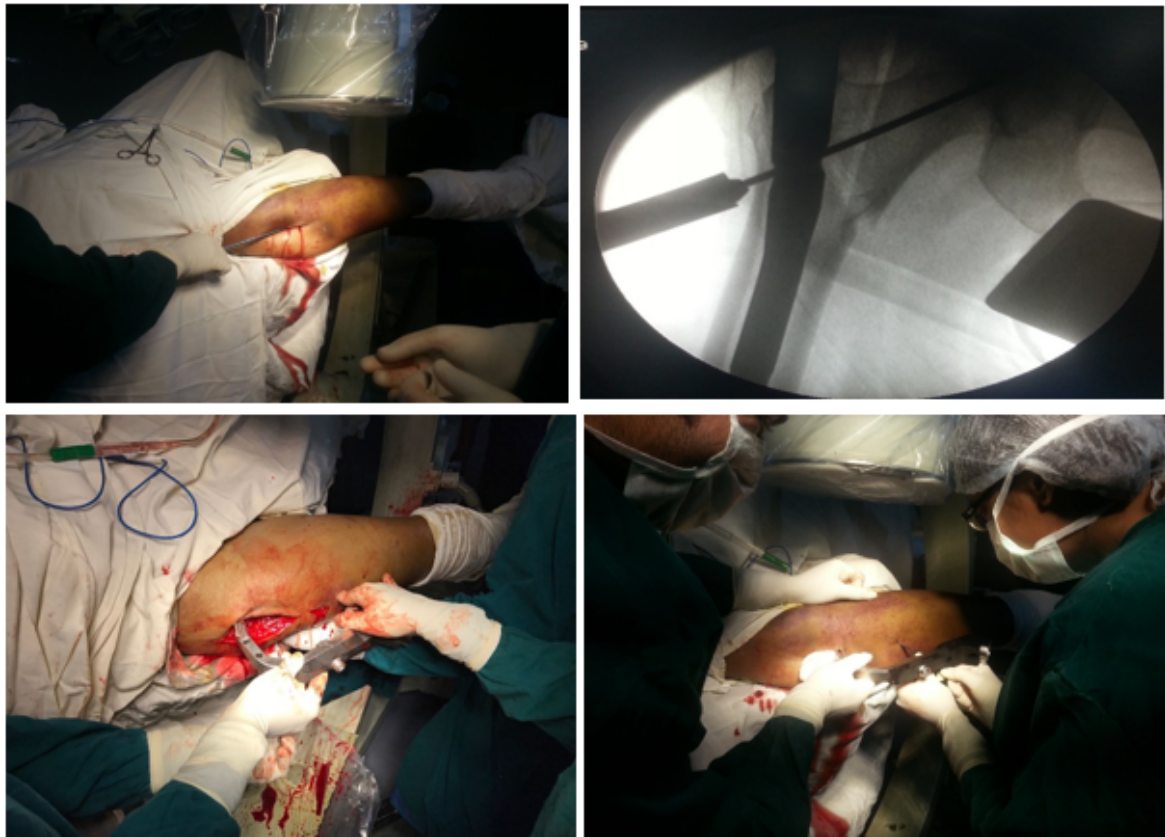
immediate post op period the end of 1<sup>st</sup>, 2<sup>nd</sup>, 3<sup>rd</sup>, and 6 months and evaluated for functional outcome using Kyle's criteria.

## 4. Results

A total of 40 patients of comminuted intertrochanteric fractures underwent surgical management with TFN-A as per our study protocol. The descriptive statistics were reported as mean (SD) for continuous variables, frequencies (percentage) for categorical variables. Data were statistically evaluated with IBM SPSS Statistics for Windows, Version 24.0, IBM Corp, Chicago, IL.

A total of 27 (67.50%) males and 13 (32.50%) females were enrolled in the study. All the patients belong to age between 50 to 90 years of age. The mean age of the patients were around  $74.97 \pm 2.93$  years with minimum age being 54 years and the maximum being 92 years. The maximum number of patients were between 70 – 80 years of age. The most common mode of injury was self fall (n=22, 55.00%), followed by road traffic accident (n=13, 32.5%) and the least was fall at work place (n=5, 12.5%).

According to Boyd and Griffin classification, the pattern of fractures were type 2 in 14 patients (35.00%), type 3 in 19 patients (47.50%) and type 4 in 7 patients (17.50%). Among 40 patients, 31 patients (77.50%) had closed reduction and 9 patients (22.50%) had open reduction and fixed with TFN-A. The mean duration of operation was recorded to be 59.69 min, which included the time from incision to suturing back the skin. We noted that the experience of the surgeon with the instrumentation, played a single major role in the reduction of the duration of the surgery. The mean



**Fig. 2:** Intra-operative images of TFN-A for comminuted intertrochanteric fracture

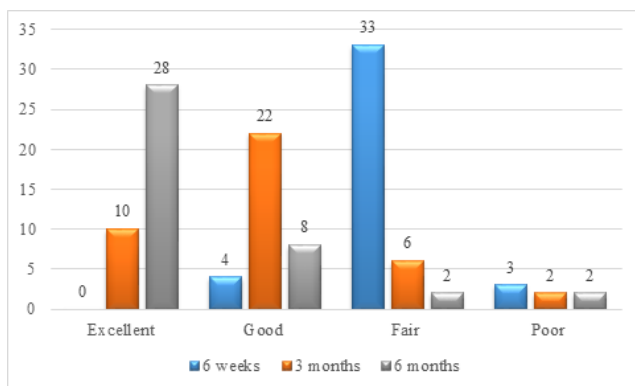
radiological union of unstable intertrochanteric fractures were  $12.98 \pm 3.09$  weeks.

At the of 6<sup>th</sup> month follow up, according to Kyle’s criteria, we observed excellent results in 28 patients (70.00%), good in 8 patients (20.00%), fair in 2 patients (5.00%) and poor in 2 patients (5.00%).

infection 2 patients (5.00%), helical blade back out 1 patient (2.50%), greater trochanteric fracture 1 patient (2.50%). Two patients with early surgical-site infection required continuation of IV antibiotics for 7 days and sutures were removed after 15 days. One patient required re-surgery because of the helical blade back out due to repeated falls by the patient right from the 4<sup>th</sup> postoperative day. After 26 days of operation, the patient reported with severe pain at the lateral side of the thigh due to helical blade back out. After which helical blade and implant removal was done. After this procedure, the patient experienced no further pain. The patient was discharged from hospital after suture removal and the functional outcome of the patient was noted as poor.

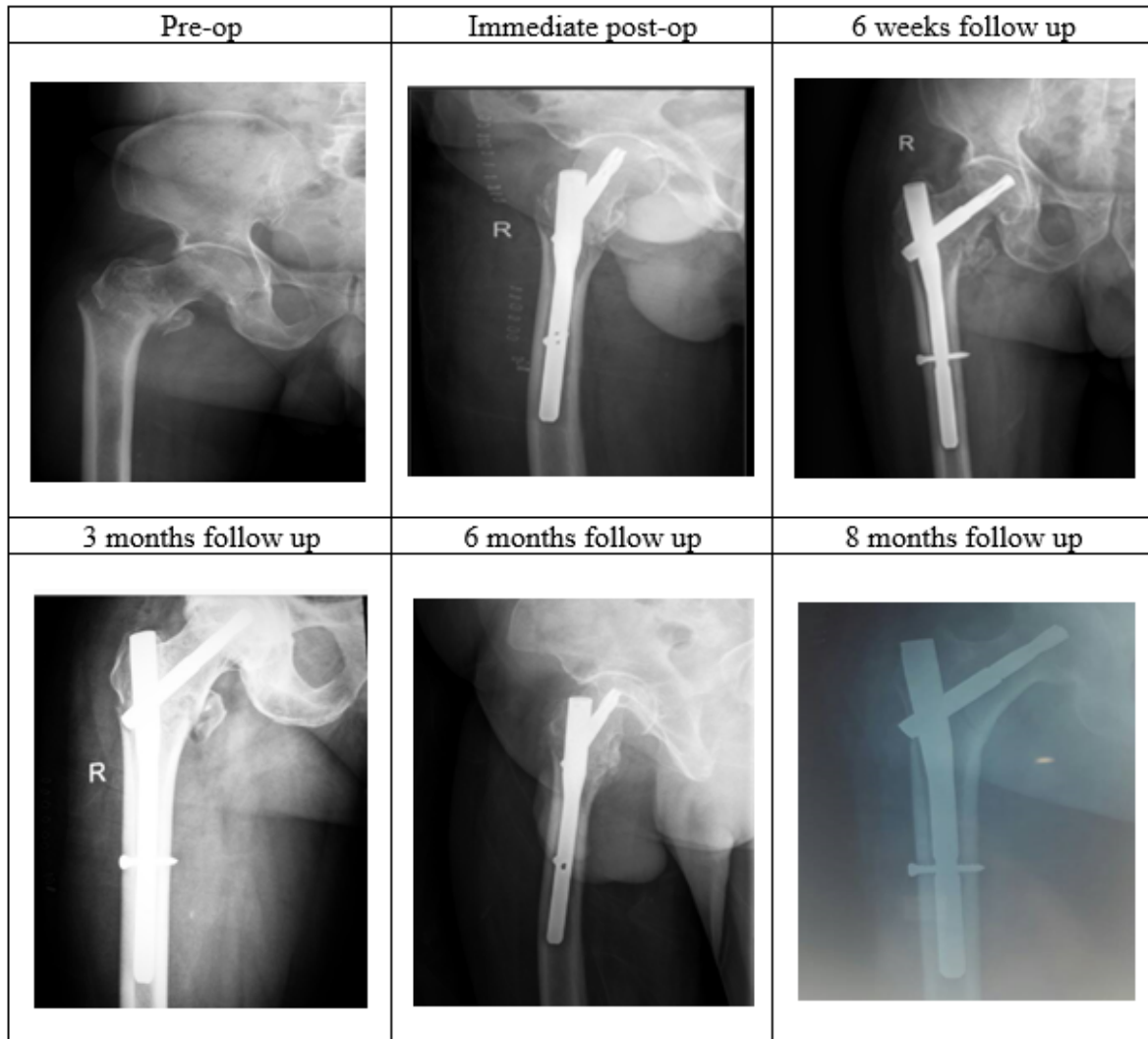
**5. Discussion**

Intertrochanteric fractures are very common in elderly patients, and the outcome may be extremely poor if there is prolonged immobilization. The objective of this study was to ascertain whether the TFN-A is an effective intramedullary device in elderly patients. In TFN-A, the design of the helical blade allows for improved purchase in the femoral head, accomplished through radial compaction of the cancellous bone around the flanges of the blade during insertion.<sup>2,9</sup> The retention and compaction of the



**Graph 1:** Functional outcome using Kyle’s scoring at 3 follow-ups

The complications in this study were seen in 4 patients out of 40 patients (10%). Complications were surgical site



**Fig. 3:** Radiographs of type II intertrochanteric fracture fixed with TFN-A

cancellous bone of the femoral head with the helical blade is advantageous compared to the bone loss that occurs with the drilling and insertion of the standard hip screw.<sup>2,10</sup> TFN-A has a single helical blade compared to PFN and hence requires a smaller incision and decreased soft tissue handling. Thus, with a lower degree of invasiveness in terms of operative procedure, maybe a better implant for intertrochanteric fractures, especially in elderly patients.

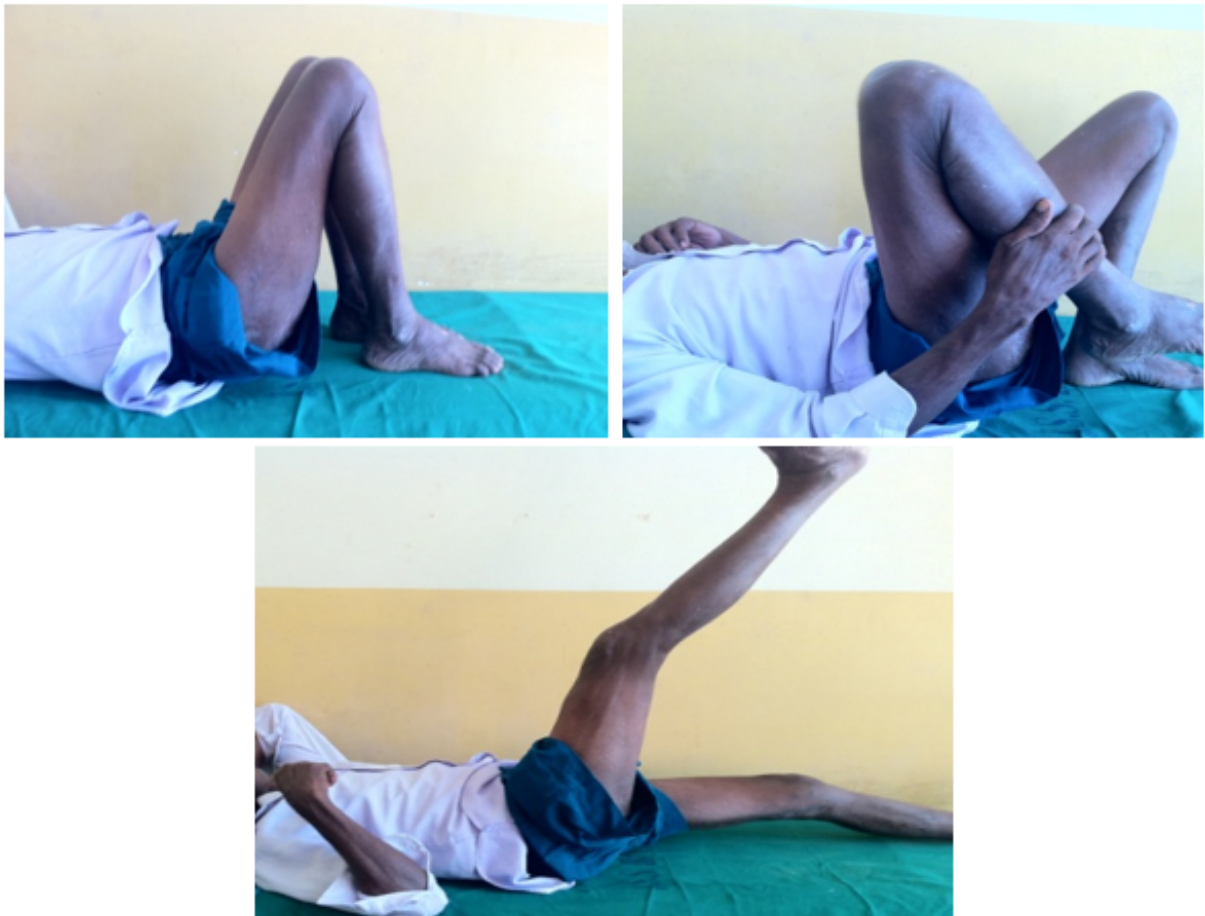In the study conducted by Sommers et al.<sup>11</sup> and Ito et al.,<sup>12</sup> the authors clearly concluded that increasing the bone-implant interface surface with the spiral blade device improved the stability of fracture fixation in osteoporotic specimens, providing a significant advantage over the smaller contact interface provided by the threads of a conventional locking bolt.

TFN-A has 6° valgus angulation at the proximal end, so as to match the anatomy of the greater trochanter. This

modification greatly reduces the intraoperative complication like diaphyseal fractures. No patient in our study had diaphyseal fracture, however diaphyseal fractures were noted in the similar studies conducted by Landivoisin et al.<sup>3</sup> (2.6%), Domingo LJ et al.<sup>13</sup> (5.6%), Herrera et al.<sup>14</sup> (9.6%) and Kakkar et al.<sup>15</sup> (10.2%).

The average operating time noted was 59.69 min which was comparable to de Landevoisin et al.<sup>3</sup> of 30-90 min. The decreased operative period (average 59.69 mins) and lower degree of invasiveness directly correlated in our study to the decreased amount of operative blood loss and no change in haematocrit post operatively. Gavaskar et al.<sup>4</sup> and Leu et al.<sup>6</sup> reported minimal blood loss in patients undergoing surgery with TFN-A.

The average time required for the union in our study was  $12.98 \pm 3.09$  weeks, which was slightly less than Vimal Kumar et al.<sup>5</sup> (16.71 weeks) and lesser than



**Fig. 4:** Range of movements of intertrochanteric fracture fixed with TFN-A

Gadgone et al.<sup>16</sup> (21 weeks) where PFN was used to treat intertrochanteric fractures.

The overall complication rate of the procedure in the literature was documented to be 11-19%, which is fortunately slightly higher than our study of 10%.<sup>4</sup> The single most important complication in our study was superficial surgical site infection (5.00%) which is comparable to studies from Andrez et al.<sup>17</sup> (5.70%). In our study, one patient (2.50%) had helical blade back which was comparable with studies of Tagamaki et al.<sup>2</sup> (2%) and Landevoisin et al.<sup>3</sup> (3.7%). The reoperation rate in our study was (2.5%), which was lesser than the study conducted by Iori Takigami et al.<sup>2</sup> (4.7%) and Gavaskar et al.<sup>4</sup> (5.7%).

An improvement in the learning curve and familiarity with the instrumentation can play a significant role in improving outcome and reducing complications with IM osteosynthesis using the TFN-A.<sup>4</sup> The limitation of this study was the lack of a control group, less sample size.

## 6. Conclusion

Choosing an ideal implant for the comminuted intertrochanteric fracture becomes the most important

factor for the early union of the fracture and speedy recovery of the patient. We conclude that the trochanteric femoral nail - advanced (TFN-A) is a versatile implant for comminuted intertrochanteric fractures, especially in elderly and osteoporotic patients. The significant reduction in operating time, minimal surgical exposure, reduced blood loss, and a significant reduction in the complication rates makes this implant the best choice in today's orthopaedic practice.

## 7. Source of Funding

None.

## 8. Conflicts of Interest

Nil.

## References

1. Shen L, Zhang Y, Shen Y, Cui Z. Antirotation proximal femoral nail versus dynamic hip screw for intertrochanteric fractures: a meta-analysis of randomized controlled studies. *Orthop Traumatol Surg Res.* 2013;99(4):377–83. doi:10.1016/j.otsr.2012.12.019.


2. Takigami I, Matsumoto K, Ohara A, Yamanaka K, Naganawa T, Ohashi M, et al. Treatment of trochanteric fractures with the PFNA (proximal femoral nail antirotation) nail system - report of early results. *Bull NYU Hosp Jt Dis.* 2008;66(4):276–9.
3. Landevoisin E, Bertani A, Candoni P, Charpail C, Demortiere E. Proximal femoral nail antirotation (PFN-ATM) fixation of extracapsular proximal femoral fractures in the elderly: retrospective study in 102 patients. *Orthop Traumatol Surg Res.* 2012;98(3):288–95.
4. Gavaskar AS, Subramanian MK, Tummala NC. Results of proximal femur nail antirotation for low velocity trochanteric fractures in elderly. *Indian J Orthop.* 2012;46(5):556–60. doi:10.4103/0019-5413.101036.
5. Kumar VKS, Arunkamal C, Devendra A, Ramesh P, Dheenadayalan J, Rajasekaran S. Comparison of radiological outcome of unstable Intertrochanteric femur fractures in elderly patients treated with Indian and Foreign Cephalomedullary nails. *Int J Orthop Sci.* 2018;4(1e):296–302. doi:10.22271/ortho.2018.v4.i1e.42.
6. Liu JJ, Shan LC, Deng BY, Wang JG, Zhu W, Cai ZD. Reason and treatment of failure of proximal femoral nail antirotation internal fixation for femoral intertrochanteric fractures of senile patients. *Genet Mol Res.* 2014;13(3):5949–56.
7. Xu YZ, Geng DC, Mao HQ, Zhu XS, Yang HL. A comparison of the proximal femoral nail antirotation device and dynamic hip screw in the treatment of unstable pertrochanteric fracture. *Int Med Res.* 2010;38:1266–75. doi:10.1177/147323001003800408.
8. Konde SS, Borkar SS, Shinde R, Marathe A, Kamath P. Dynamic Hip Screw and Proximal Femoral Nail as a Mode of Surgical Treatment in Intertrochanteric Fractures of Femur in Elderly Patients. *Int J Contemp Med Res.* 2018;5(4):77–83. doi:10.21276/ijcmr.2018.5.4.30.
9. Parmer V, Kumar S, Aster A, Harper WH. Review of methods to quantify lag screw placement in hip fracture fixation. *Acta Orthop Belg.* 2005;71:260–263.
10. Strauss E, Frank J, Lee J, Kummer FJ, Tejwani N. Helical blade versus sliding hip screw for treatment of unstable intertrochanteric hip fractures: A biomechanical evaluation. *Injury.* 2006;37(10):984–9. doi:10.1016/j.injury.2006.06.008.
11. Sommers MB, Roth C, Hall H, Kam BCC, Ehmke LW, Krieg JC, et al. A Laboratory Model to Evaluate Cutout Resistance of Implants for Pertrochanteric Fracture Fixation. *J Orthop Trauma.* 2004;18(6):361–8. doi:10.1097/00005131-200407000-00006.
12. Ito K, Hungerbühler R, Wahl D, Grass R. Improved Intramedullary Nail Interlocking in Osteoporotic Bone. *J Orthop Trauma.* 2001;15(3):192–6. doi:10.1097/00005131-200103000-00008.
13. Domingo L, Cecilia D, Herrera A, Resines C. Trochanteric fractures treated with a proximal femoral nail. *Int Orthop.* 2001;25(5):298–301. doi:10.1007/s002640100275.
14. Herrera A, Domingo L, Calvo A, Martinez A, Cuenca J. A comparative study of trochanteric fractures treated with the Gamma nail or the proximal femoral nail. *Int Orthop.* 2002;26(6):365–9. doi:10.1007/s00264-002-0389-6.
15. Kakkar R, Kumar S, Singh AK. Cephalomedullary nailing for proximal femoral fractures. *Int Orthop.* 2005;29(1):21–4. doi:10.1007/s00264-004-0624-4.
16. Gadegone WM, Salphale YS. Short Proximal Femoral Nail Fixation for Trochanteric Fractures. *J Orthop Surg.* 2010;18(1):39–44. doi:10.1177/230949901001800109.
17. Nikoloski AN, Osbrough AL, Yates PJ. Should the tip-apex distance (TAD) rule be modified for the proximal femoral nail antirotation (PFNA)? A retrospective study. *J Orthop Surg Res.* 2013;8(1):35. doi:10.1186/1749-799x-8-35.

### Author biography

**Arunodhaya Siddartha S**, Associate Professor

**Pramod B M**, Assistant Professor

**Tushar Pimpale**, Senior Resident

**Mayur Chandrashekar**, Senior Resident  <https://orcid.org/0000-0002-5369-7732>

**Mruthyunjaya**, Professor

**Cite this article:** Siddartha S A, Pramod B M, Pimpale T, Chandrashekar M, Mruthyunjaya. Management of comminuted intertrochanteric fractures with TFN -A (Trochanteric Femoral Nailing - Advanced) in elderly patients – A prospective study. *Indian J Orthop Surg* 2021;7(2):164-169.