



Original Research Article

Functional outcome of arthroscopic anterior cruciate ligament reconstruction with autologous hamstring graft

Sudhakar T¹, Ramesh Raja C^{1,*}, Jambukeswaran Jambukeswaran PST¹, Ugeneshwaran M¹, Madhan Jeyaraman ²

¹Dept. of Orthopaedic Surgery, Government Medical College & ESI Hospital, Coimbatore, Tamil Nadu, India

²Dept. of Orthopaedic Surgery, School of Medical Sciences and Research, Sharda University, Greater Noida, Uttar Pradesh, India



ARTICLE INFO

Article history:

Received 26-03-2021

Accepted 28-05-2021

Available online 12-06-2021

Keywords:

Anterior cruciate ligament

Hamstring

Endobutton

Arthroscopy

ABSTRACT

Introduction: The ligamentous injuries of the knee are increasing owing to the increasing participation in the sports activities. Anterior cruciate ligament is the most commonly injured ligament in the knee joint. A number of procedures have been recounted for reconstruction of a broken ACL ranging from open to arthroscopic technique. In this study, we have used hamstring autograft for ACL reconstruction and fixed it with endobutton on the femoral end and with interference screw at the tibial end and in addition to this, cancellous screws or suture wheel was used if required.

Materials and Methods: A total of 15 cases of complete ACL tear were taken for the study. All patients underwent arthroscopic ACL reconstruction with hamstring graft. All operated patients took Lysholm knee scoring questionnaire and were reviewed at 6 weeks, 3 months, 6 months and 1 year for assessment.

Results: At the end of 1 year by Lysholm knee scoring, a total of 27% cases reported excellent results, 53% were good, 13% were fair and 7% obtained poor results. The functional restoration to pre-injury level was seen in 67% of patients.

Conclusion: We conclude that the usage of hamstring graft for reconstruction of a torn ACL gives an excellent to good outcome, keeping in mind proper patient selection and an immense role of the physiotherapy.

© This is an open access article distributed under the terms of the Creative Commons Attribution License (<https://creativecommons.org/licenses/by/4.0/>) which permits unrestricted use, distribution, and reproduction in any medium, provided the original author and source are credited.

1. Introduction

One of the most commonly injured joint is knee joint and out of all the ligaments in and around knee, ACL is one ligament, which is commonly injured and requires surgical intervention too.¹ The ligamentous injuries of the knee are increasing owing to the increasing participation in the sports activities and the other reason being the road traffic accidents. ACL along with other structures of the knee, helps in knee stabilisation and aids in functional congruity.^{2,3} An intact ACL prevents the posterior translation of femur on tibia as well as aids in managing valgus and rotational forces on knee joint.⁴ The

capacity of ACL to heal after it is torn is very poor and is an important clinical problem. So, reconstruction of the ACL in patients with ACL tear becomes must to get a functionally stable knee joint.

In the past, many studies have shown good outcomes after an ACL reconstruction using autografts and allografts as well.^{5,6} A number of procedures have been recounted for reconstruction of a broken ACL ranging from open to arthroscopic technique.⁷ For a long time the most common graft in use was Bone patellar tendon bone (BPTB) graft for ACL reconstruction. But complications such as inefficient extensor mechanism of the knee, loss of motion, patellar fractures and continuous knee pain over anterior aspect forced surgeons to come out with other sources of graft retrieval for use in ACL reconstruction. A good alternative

* Corresponding author.

E-mail address: dr.rameshrajapeacockplus.com (R. Raja C).

is use of hamstring graft which prevents the jeopardising of extensor apparatus as was seen in BPTB graft.

Use of hamstring tendon grafts have given excellent results in ACL deficient patients undergoing reconstruction with a proper patient selection.⁸ The hamstring tendon graft is nourished by the surrounding synovial fluid and is a probable reason that the cells of a quadrupled hamstring graft survive better than the BPTB graft and gives better results as compared to latter.

In a meta-analysis done by Biau, et al., in 2007 to obtain subjective statistics to determine if BPTB or hamstring graft grant a better functional knee joint as decided by final overall IKDC scoring and restoration of daily and sports activity to pre injury level. In the results obtained, functional outcome had no significant differences when both BPTB graft and hamstring graft were compared.⁹

In contrary to the above meta-analysis, there are many documentations showing decreased morbidity in patients undergoing reconstruction with hamstring graft. In this study, we have used hamstring autograft for ACL reconstruction and fixed it with endobutton on the femoral end and with interference screw at the tibial end and in addition to this, cancellous screws or suture wheel was used if required.

2. Materials and Methods

Ethical clearance was obtained from the institutional committee. In this prospective study which took place from August 2016 to July 2018 and the number of cases of ACL rupture included in our study were 15. Thorough examination was done to assess the knee instability and consent was taken for reconstruction with hamstring graft. All routine blood and radiological investigations were done. All patients underwent arthroscopic ACL reconstruction with hamstring graft.

Patients included in study were those with ACL rupture and a normal contralateral joint, aged more than 18, both males and females were included. Patients who needed revision ACL surgery or ACL injury with other intra-articular pathologies such as fractures, multi-ligament injury or OA knee were excluded. All operated patients took Lysholm knee scoring questionnaire and were reviewed at 6 weeks, 3 months, 6 months and 1 year for assessment.

3. Results

The evaluation of the data obtained was done by using IBM SPSS Statistics for Windows, Version 24.0, IBM Corp, Chicago, IL.

The functional restoration to pre-injury level was seen in 67% of patients.

Table 1:

Mean age	33.4 years (22-53)
Side involved	Right (53%)
Age Group	26-30 years (53%), 21-25 (27%)
Sex	Male (80%)
Cause	RTA (40%), Sports Activity (29%)
Pain as presenting complain	80% of patients
History of Locking	60% of patients
Findings During Surgery:	
Medial Meniscal tear	53% of cases
Lateral Meniscal tear	20% of cases
Isolated Tear of ACL	20%

Table 2:

Outcome	Score	% of Patients
Excellent	Above 95	27%
Good	84-95	53%
Fair	65-83	13%
Poor	Less than 65	7%

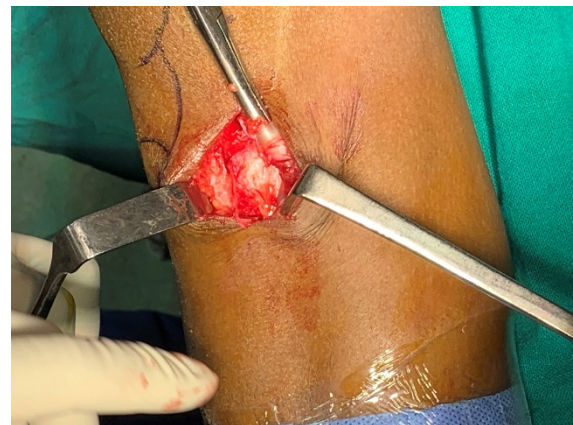

Fig. 1: Autologous hamstring graft harvesting




Fig. 2: Hamstring graft tensioning

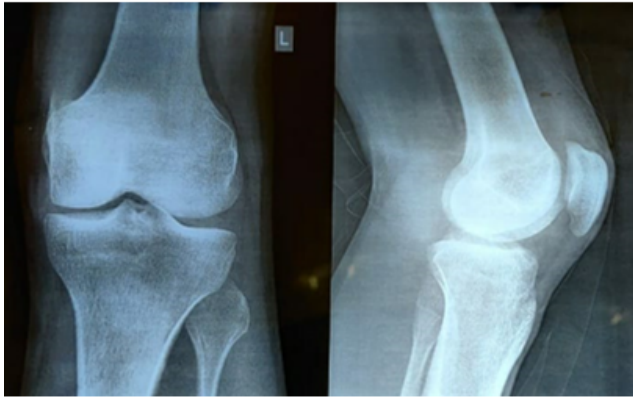


Fig. 3: Pre-op X ray left knee– AP and lateral view

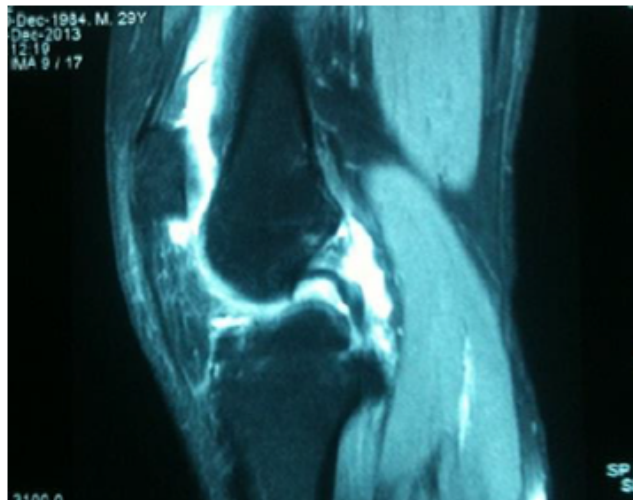


Fig. 4: Pre-op MRI showing complete ACL tear

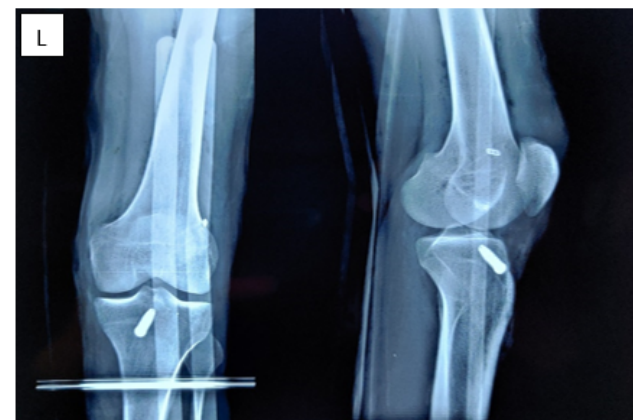


Fig. 5: Post-op X-ray showing reconstructed ACL with endobutton and interference screw

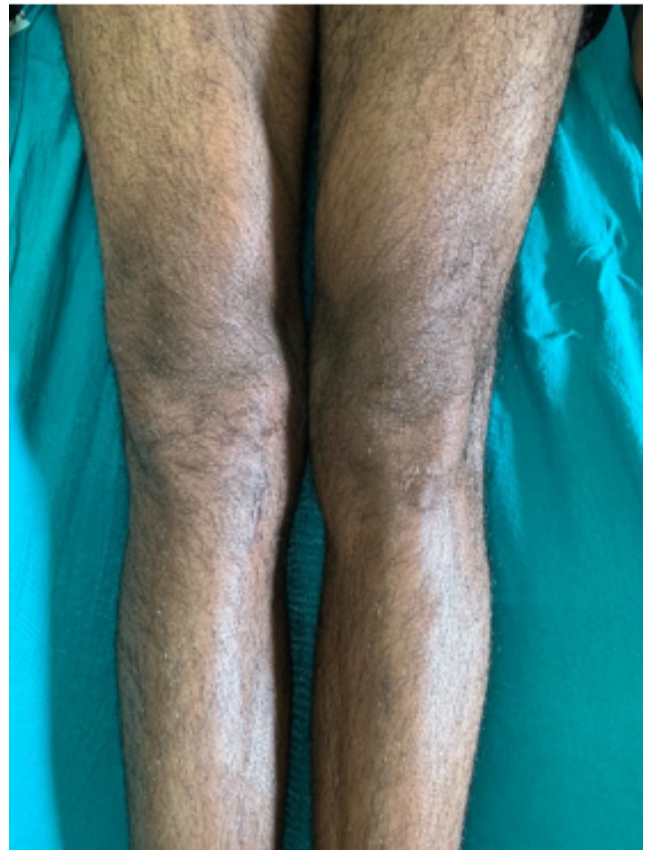

Fig. 6: Post-op complete extension of left knee

4. Discussion

In patients with where ACL injury is ignored and not treated timely, knee disability is worrisome which in turn can bring upon joint, pernicious consequences if the injury persists. With the advancements in surgical methods and improved outcomes, the expectations of patients to return to their pre-injury levels has put up a lot of burden. In providing and fulfilling such expectations, graft choice also plays a major role, out of which, the use of hamstring grafts is gaining popularity especially the quadrupled hamstring graft. 4 string hamstring graft has been proven to have better graft strength and stiffness as compared to patellar tendon graft.

The morbidity of the donor site is also less when compared to BPTB graft and additionally decreasing the risk of patellar fracture too. For a successful outcome using hamstring autograft, a good and stable initial fixation is needed which has been achieved with the usage of endobuttons which has a good pull-out strength.

In our study all the 15 patients underwent ACL reconstruction using hamstring autograft during the study period. The graft was fixed with endobutton on the femoral side while interference screw was used in the tibial tunnel for fixation with additional strengthening material if

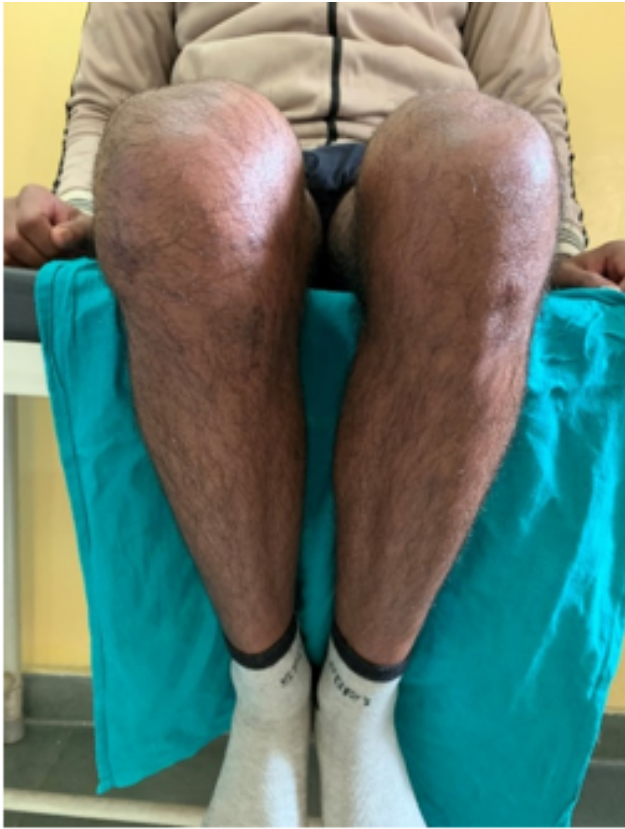

Fig. 7: Post-op 100° flexion of left knee

necessary such as suture discs for a better hold.

12 males and 3 females were part of the study with majority having injury to right knee. In a study by Brown et al., it was seen that in spite of the female sex being more prone for getting injured, due to limited exposure to circumstances in context to the mode and cause of injury, the incidence is more in males. It was also deduced that the side of limb involved had no influence in functional outcome.¹⁰

In the knee scoring scale by Lysholm, 27% of the patients had excellent outcome, 53% good, 13% fair and 7% poor. In a similar study by Bourke et al. where 143 patients were included in the study, good or excellent Lysholm score at the end of one year follow-up was seen in 94% of participants in the study.¹¹ In this study 67% of the study participants returned to pre-injury level while 33% did not return to pre-injury level.

In a recent study, very good outcomes for ACL reconstruction were observed with the use of hamstring graft, given the surgery being timed well, an appropriate thickness of the graft used and an excellent protocol for post-op physiotherapy. A drastic increase in IDKC score was also seen.¹² The timing of surgery and protocol for rehabilitation greatly influence the end results.

Kautzner et al. compared the functional outcome of ACL reconstruction using hamstring graft versus patellar tendon graft and found significant betterment of the patient's

functional status and knee stability after ACL reconstruction using either one of the grafts. In this study both the grafts had comparable results.¹³

A prospective randomized comparison between the use of BPTB graft and hamstring graft, it was seen that patient had very less discomfort in knee walking test when the latter was used and had an excellent functional outcome too.¹⁴ A study by Williams et al. achieved a significant improvement in the mean scoring post operatively at the end of 2 years. The score improved from a preoperative value of 55 to 92 post-operatively which had a significant p value.¹⁵ Another retrospective study reported an excellent outcome of around 96% in patients who underwent arthroscopic reconstruction of ACL using 4-stranded hamstring graft.¹⁶ Gulick et al. did a study on 57 patients and achieved a good result; around 85% of the patients returned to a functional level comparable to as was before the injury.¹⁷

5. Conclusion

From the above results and discussion we conclude that the usage of hamstring graft for reconstruction of a torn ACL gives an excellent to good outcome, keeping in mind proper patient selection and an immense role of the physiotherapy. A good patient selection and an excellent and adhering physiotherapy protocol along with the usage of quadrupled hamstring graft can help in return to full occupational and recreational activities for most of the patients within few months after surgery.

6. Source of Funding

None.

7. Conflict of Interest

The authors declare that there is no conflict of interest.

References

1. Paschos NK, Howell SM. Anterior cruciate ligament reconstruction: principles of treatment. *EFORT Open Rev.* 2016;1(11):398–408. doi:10.1302/2058-5241.1.160032.
2. Pardiwala DN, Rao NN, Anand K, Raut A. Knee dislocations in sports injuries. *Indian J Orthop.* 2017;51(5):552–62. doi:10.4103/ortho.ijortho_229_17.
3. Swenson TM. Physical diagnosis of the multiple-ligament-injured knee. *Clin Sports Med.* 2000;19(3):415–23. doi:10.1016/s0278-5919(05)70215-5.
4. Mader K, Pennig D, Dargel J, Gotter M, Koebke J, Schmidt-Wiethoff R. Biomechanics of the anterior cruciate ligament and implications for surgical reconstruction. *Strat Trauma Limb Reconstr.* 2007;2:1–12. doi:10.1007/s11751-007-0016-6.
5. Macaulay AA, Perfetti DC, Levine WN. Anterior Cruciate Ligament Graft Choices. *Sports Health.* 2012;4(1):63–8. doi:10.1177/1941738111409890.
6. Widner M, Dunleavy M, Lynch S. Outcomes Following ACL Reconstruction Based on Graft Type: Are all Grafts Equivalent? *Curr Rev Musculoskelet Med.* 2019;12(4):460–5. doi:10.1007/s12178-019-09588-w.

7. Samitier G, Marcano AI, Alentorn-Geli E, Cugat R, Farmer KW, Moser MW. Failure of Anterior Cruciate Ligament Reconstruction. *Arch Bone Jt Surg*. 2015;3(4):220–40.
8. Hadi H, Bagherifar A, Tayebi F. Anterior Cruciate Ligament Reconstruction with Hamstring Tendons Has no Deleterious Effect on Hip Extension Strength. *Arch Bone Jt Surg*. 2019;7(3):278–83.
9. Biau DJ, Tournoux C, Katsahian S, Schranz P, Nizard R. ACL reconstruction: a meta-analysis of functional scores. *Clin Orthop*. 2007;458:180–7.
10. Brown TN, Palmieri-Smith RM, McLean SG. Sex and limb differences in hip and knee kinematics and kinetics during anticipated and unanticipated jump landings: implications for anterior cruciate ligament injury. *Br J Sports Med*. 2009;43(13):1049–56. doi:10.1136/bjism.2008.055954.
11. Bourke HE, Gordon DJ, Salmon LJ, Waller A, Linklater J, Pinczewski LA. The outcome at 15 years of endoscopic anterior cruciate ligament reconstruction using hamstring tendon autograft for 'isolated' anterior cruciate ligament rupture. *J Bone Joint Surg Br*. 2012;94-B(5):630–7. doi:10.1302/0301-620x.94b5.28675.
12. Chodavarapu LM, Hussain AKS, Kumar KKK, Patnala C, Yadoji H. Analysis of functional outcome of anterior cruciate ligament reconstruction using quadruple hamstring graft. *Int J Res Orthop*. 2017;3(4):877–82. doi:10.18203/issn.2455-4510.intjresorthop20172872.
13. Kautzner J, Kos P, Hanus M, Trc T, Havlas V. A comparison of ACL reconstruction using patellar tendon versus hamstring autograft in female patients: a prospective randomised study. *Int Orthop*. 2015;39(1):125–30. doi:10.1007/s00264-014-2495-7.
14. Laxdal G, Kartus J, Hansson L, Heidvall M, Ejerhed L, Karlsson J. A prospective randomized comparison of bone-patellar tendon-bone and hamstring grafts for anterior cruciate ligament reconstruction. *Arthroscopy*. 2005;21(1):34–42. doi:10.1016/j.arthro.2004.09.014.
15. Williams RJ, Hyman J, Petrigliano F, Rozentel T, Wickiewicz TL. Anterior Cruciate Ligament Reconstruction with a Four-Strand Hamstring Tendon Autograft. *J Bone Joint Surg*. 2004;86(2):225–32. doi:10.2106/00004623-200402000-00003.
16. Frank RM, Hamamoto JT, Bernardoni E, Cvetanovich G, Bach BR, Verma NN. ACL Reconstruction Basics: Quadruple (4-Strand) Hamstring Autograft Harvest. *Arthrosc Tech*. 2017;6(4):e1309–13. doi:10.1016/j.eats.2017.05.024.
17. Gulick DT, Yoder HN. Anterior Cruciate Ligament Reconstruction: Clinical Outcomes of Patella Tendon and Hamstring Tendon Grafts. *J Sports Sci Med*. 2002;1(3):63–71.


Author biography

Sudhakar T, Assistant Professor

Ramesh Raja C, Assistant Professor

Jambukeswaran Jambukeswaran PST, Assistant Professor

Ugeneshwaran M, Assistant Professor

Madhan Jeyaraman, Senior Resident  <https://orcid.org/0000-0002-9045-9493>

Cite this article: Sudhakar T, Raja C R, Jambukeswaran PST J, Ugeneshwaran M, Jeyaraman M. Functional outcome of arthroscopic anterior cruciate ligament reconstruction with autologous hamstring graft. *Indian J Orthop Surg* 2021;7(2):113-117.