



Case Report

Filariasis presenting as isolated asymptomatic unilateral inguinal lymphadenopathy

Benny PB^{1,*}, Muhsin VK²

¹Dept. of General Surgery, Azeezia Institute of Medical Sciences and Research, Kollam, Kerala, India

²Dept. of Surgery, Azeezia Institute of Medical Sciences and Research, Kollam, Kerala, India



ARTICLE INFO

Article history:

Received 15-11-2020

Accepted 16-12-2020

Available online 01-02-2021

Keywords:

Filarial lymphadenopathy

Lymphatic filariasis

Eosinophilia

Diethylcarbamazine

ABSTRACT

Filariasis continues to be one of the endemic problems worldwide with 40% of the cases in India. We report a case of lymphatic filariasis in a 3-year-old girl who presented with a non-tender swelling over left inguinal region. Blood sample showed eosinophilia while the excision biopsy was diagnostic of filarial worm. Patient responded well with oral diethylcarbamazine. High index of suspicion of filariasis is indicated when dealing with a swelling of unknown cause even if it is not from an endemic area.

© This is an open access article distributed under the terms of the Creative Commons Attribution License (<https://creativecommons.org/licenses/by/4.0/>) which permits unrestricted use, distribution, and reproduction in any medium, provided the original author and source are credited.

1. What's Known

Filariasis as a rare cause of isolated lymph node enlargement has been described. Diagnosis was established by excision biopsy following imaging studies.

2. What's New

Filariasis presenting as isolated asymptomatic unilateral inguinal lymph node enlargement and unilateral hydrosalpinx is rare. Diagnosis via ultrasound imaging, routine blood analysis, excision biopsy and subsequent treatment with diethylcarbamazine resulting in full resolution has not been reported before.

3. Introduction

Filariasis is a vector borne disease especially prevalent in tropical and subtropical regions and caused by slender thread-like filarial worms from the superfamily of Filarioidea, which has an affinity towards skin and subcutaneous tissue or lymphatic system. While

the nematode-like *Onchocerca volvulus* and *Loa loa* cause filariasis of the skin, *Wuchereria bancrofti*, *Brugia malayi* and *Brugia timori* cause lymphatic filariasis in the descending order. *Wuchereria bancrofti* filariasis produces a wide range of clinical manifestations depending upon the phase and duration. The chronic phase is usually characterized by presence of lymphadenopathy in lower limbs, retroperitoneal tissues, lymphedema, hydrocele and elephantiasis. *Microfilaria* are usually absent in early and late phase of the disease. Circulating filarial antigen testing is more sensitive and can detect the presence of the nematode, even in early stages.

4. Case Report

A 3-year-old girl was seen at our outpatient clinic with a 1-week history of enlarged painless left inguinal lymphadenopathy. The mass had never been erythematous, and she had never displayed any signs of a systemic infection, including fever or chills. She had never travelled outside the Kollam district. On examination, a single 1.5 × 1.5 cm, mobile, non-tender left inguinal mass with firm consistency was palpated. The rest of the

* Corresponding author.

E-mail address: drpunchakonam@gmail.com (Benny PB).

physical examination was unremarkable. Blood routines showed eosinophilia and peripheral smear report came as normocytic normochromic picture.

USG Abdomen and pelvis along with inguinal region revealed left inguinal swelling corresponds to an enlarged lymph node and right sided hydrosalpinx.

She underwent an excisional biopsy of the left inguinal lymph node, which she tolerated without any complications.

Histopathologic examination revealed cut section of filarial worm surrounded by eosinophilic abscess and marked fibrosis.

She was treated with complete course of Diethylcarbamazine and did a follow up USG of abdomen, which showed complete resolution of right sided hydrosalpinx.

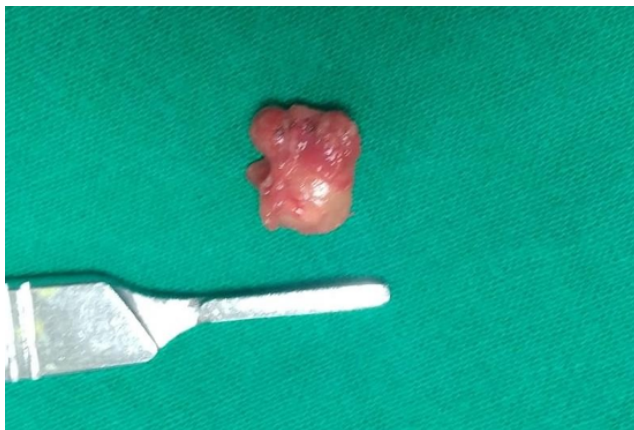

Fig. 1: Excised lymph node

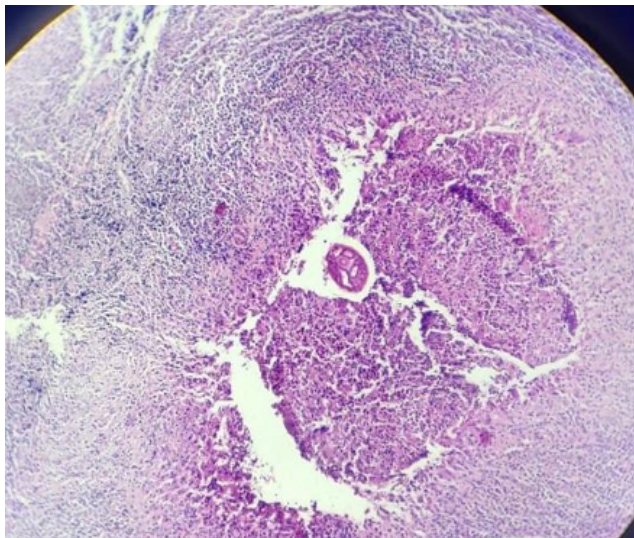


Fig. 2: Histopathology showing cut section of filarial worm surrounded by eosinophilic abscess and marked fibrosis

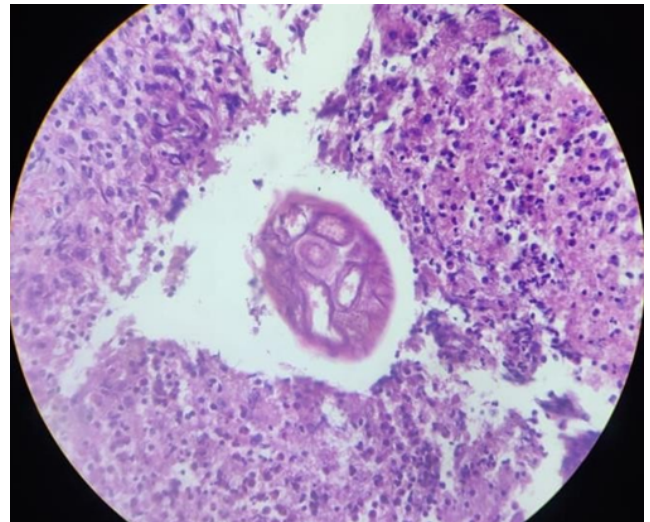


Fig. 3: High power view showing cross section of Filarial worm

5. Discussion

Filariae of animals can infect humans and typically produce cryptic infections. These “zoonotic” infections can occur anywhere even non-endemic regions. Infections may be symptomatic or not, and the parasites are found in surgical tissue biopsy specimens or rarely are removed intact from superficial sites such as conjunctiva. Worms have been found in subcutaneous tissues, the heart and lungs, lymphatics, the eye, and the central nervous system.³ Many kinds of filariae have been isolated from humans, including species of *Dirofilaria*, *Brugia*, *Onchocerca*, *Dipetalonema*, *Loaia* and *Meningonema*.¹

Acute lymphadenitis, asymptomatic subcutaneous swelling, acute lymphangitis, lymph node swellings, funiculoepididymoorchitis, nodules in breast, chronic lymphedema, hydrocele, thyroid or salivary gland, tropical pulmonary eosinophilia and chyluria are the various clinical pictures of lymphatic filariasis.² Lymphatic filariasis occurs in nearly 25-30% of all total cases of filariasis while lymph node involvement is found in about 0.047% cases.^{2,3}

Imaging modalities like ultrasonography and magnetic resonance may demonstrate regular twirling motion of echogenic particles of either adult filarial worms or microfilaria in lymphatics (filarial dance sign).⁴

Immunochromatographic and deoxyribonucleic acid probes can demonstrate even species of worm also. This is sensitive and specific method. Fine Needle Aspiration Cytology (FNAC) provides a simple, inexpensive and rapid way to diagnose microfilariae and adult worms. However, finding of microfilaria in FNAC is an uncommon phenomenon.⁵

Superficial sites like lymph nodes, breast lumps, scrotal swellings, thyroid swellings, and soft tissue swellings have very low chances of microfilaria detection.^{1,4,6–10} Only

0.078% of detection rate of microfilaria is noted in all samples of lymph node swellings.^{2,11}

Treatment is done by diethylcarbamazine, 6 mg/kg/day for a period of 12 days in divided doses.⁸ A single annual dose of oral Albendazole 400 mg and diethylcarbamazine 6 mg/ kg of body weight is recommended for prevention of filariasis in endemic countries.⁵

Vaccines are not effective. Vector control is the key in prevention of transmission.

6. Conclusion

Lymphatic filariasis, albeit rare, should be considered as a differential diagnosis in lymph node swellings. Ultrasound imaging and Fine-needle aspiration cytology may serve as a useful screening tool in differentiating neoplastic and inflammatory lesions. Excision biopsy is confirmatory. Medical therapy with DEC can produce good results in the filarial lymphadenopathy.

7. Conflict of Interest

None declared

8. Source of Funding

None.

References

- Orihel TC, Eberhard ML. Zoonotic Filariasis. *Clin Microbiol Rev.* 1998;11(2):366–81. doi:10.1128/cmr.11.2.366.
- Gupta P, Bharadwaj M, Durga CK. Isolated Epitrochlear Filarial Lymphadenopathy: Cytomorphological Diagnosis of an Unusual Presentation. *Turk Patoloji Derg.* 2020;36(1):87–9. doi:10.5146/tjpath.2018.01423..
- Sivakumar S. Role of fine needle aspiration cytology in detection of microfilariae: report of 2 cases. *Acta Cytol.* 2007;51(5):803–6. doi:10.1159/000325846. PMID: 17910352..
- Dietrich CF, Chaubal N, Hoerauf A, Kling K, Piontek MS, Steffgen L, et al. Review of Dancing Parasites in Lymphatic Filariasis. *Ultrasound Int Open.* 2019;05(02):E65–E74. doi:10.1055/a-0918-3678.
- Raveendran R. Lymph Node Enlargement in Neck Filariasis as a Rare Cause: A Case Report. *Iran J Med Sci.* 2017;42(5):493–6.
- Isolated Epitrochlear Filarial Lymphadenopathy: Cytomorphological Diagnosis of an Unusual Presentation. *Turk Patoloji Derg.* 2018;36(1):87–9. doi:10.5146/tjpath.2018.01423.
- Kimberlin D, Brady M, Jackson M, Long S. American Academy of Pediatrics. Lymphatic Filariasis. In: 2018 Report of the Committee on Infectious Diseases. American Academy of Pediatrics; 2018. p. 523–5.
- Simmonds JC, Mansour MK, Dagher WI. Cervical Lymphatic Filariasis in a Pediatric Patient: Case Report and Database Analysis of Lymphatic Filariasis in the United States. *Am J Trop Med Hygiene.* 2018;99(1):104–11. doi:10.4269/ajtmh.17-0786.
- Oguntola AS, Oguntola AM, Bajowa OO, Sabageh D. Incidental detection of microfilariae in a lymph node aspirate: A case report. *Niger Med J.* 2014;55(5):438–40. doi:10.4103/0300-1652.140392.
- Kandalam PTS, Parampath AN, Farghaly HI, Salah SA, Kayakkool MK, Mathew JV, et al. An unusual presentation of filariasis in a nonendemic country. *Qatar Med J.* 2015;2015(2):17. doi:10.5339/qmj.2015.17.
- Pandey P, Dixit A, Chandra S, Tanwar A. Cytological diagnosis of bancroftian filariasis presented as a subcutaneous swelling in the cubital fossa: an unusual presentation. *Oxford Med Case Rep.* 2015;2015(4):251–3. doi:10.1093/omcr/omv027.

Author biography

Benny PB, Assistant Professor

Muhsin VK, Junior Resident

Cite this article: Benny PB, Muhsin VK. Filariasis presenting as isolated asymptomatic unilateral inguinal lymphadenopathy. *IP J Surg Allied Sci* 2020;2(4):123-125.