



Case Report

Tracheocutaneous fistula closure by two hinged turnover flap and a fasciocutaneous pivot flap

Manish Gupta^{1,*}, Anshul Singh¹

¹Dept. of ENT, Maharishi Markandeshwar (Deemed to be University), Ambala, Haryana, India



ARTICLE INFO

Article history:

Received 15-12-2020

Accepted 28-12-2020

Available online 18-01-2021

Keywords:

Tracheocutaneous fistula

Tracheostomy

Surgery

Hinge flap

ABSTRACT

Introduction: Tracheocutaneous fistula is a known complication in patient who are tracheostomised for long duration.

Case Presentation: A 18-year-old girl presented in our department who was tracheostomised 2 years back, to secure airway, following a road traffic accident and tracheal injury. She underwent multiple surgeries to maintain upper airway, which were successful, but developed a tracheocutaneous fistula due to prolonged tracheostomy. Surgical closure of the fistula was done using a two hinged turnover flap and a fasciocutaneous pivot flap. The patient was discharged on 6th day of the surgery with no complication and no recurrence.

Conclusion: Our technique explains one of the many procedures used to close a tracheocutaneous fistula, mentioned in literature. It is minimally invasive and is associated with minimal chance of tracheal stenosis and recurrence.

© This is an open access article distributed under the terms of the Creative Commons Attribution License (<https://creativecommons.org/licenses/by/4.0/>) which permits unrestricted use, distribution, and reproduction in any medium, provided the original author and source are credited.

1. Introduction

Tracheocutaneous fistula is a known complication in patients who are tracheostomised, for a long period. Apart from having all the associated comorbidities of tracheostomy, it is also cosmetically and socially unappealing. Primary closure, carries a high risk of complication like wound breakdown, surgical emphysema and pneumothorax.^{1,2} We hereby describe one of the many surgical techniques for closure of persistent tracheocutaneous fistula, in two layers by using bilateral hinged turnover flap and a fasciocutaneous pivot flap over it.

2. Case Report

An 18-year-old girl presented in our department, with a history of being tracheostomised 2 years back for tracheal injury, following a road traffic accident. She gave history of

multiple open and endoscopic procedures, being performed, at a different centre, for airway stenosis. The procedures achieved the patent airway, but the patient developed a tracheocutaneous fistula due to prolonged tracheostomy. On examination patient was mentally sound and obeyed all the commands. Physical examination revealed 2cm X 1 cm tracheocutaneous fistula, with well epithelized margins (Figure 1 A & B). Preoperative computed tomography confirmed the size of fistula to be 2cm X 1cm. Preoperative fiberoptic laryngoscopy showed there was no airway compromise superior, inferior or at the site of fistula.

The fistula was closed under general anaesthesia, using two hinged turnover flap and a fasciocutaneous pivot flap. The vertically aligned bilateral spindle shaped incision were made around the fistula (Figure 2A) and two full thickness skin hinge flaps were elevated on both right and left sides of the fistula. The hinge flaps were sutured with 3-0 vicryl after turning them inside (Figure 2B). Fasciocutaneous pivot flap was then elevated (Figure 3A) and rotated from the left side and sutured after transposition over the hinged flaps (Figure 3B). Finally, skin was closed using silk sutures

* Corresponding author.

E-mail address: manishgupta1217@gmail.com (M. Gupta).

(Figure 4). Patient was extubated and postoperative period was uneventful with no surgical emphysema indicating a good seal.

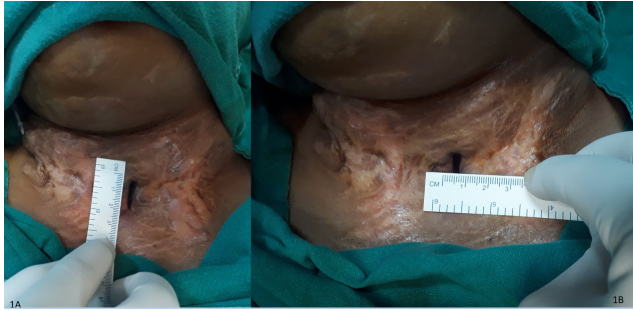


Fig. 1: Preoperative clinical pictures showing vertical length of fistula segment to be 2cm (1A) and showing horizontal width of fistula segment to be 1cm (1B).

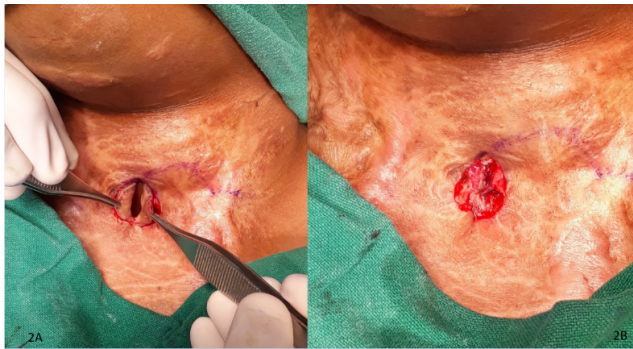


Fig. 2: Intraoperative clinical picture showing vertical spindle incision, raising full thickness skin flap (2A) and inverting the hinged flap with suture (2B).

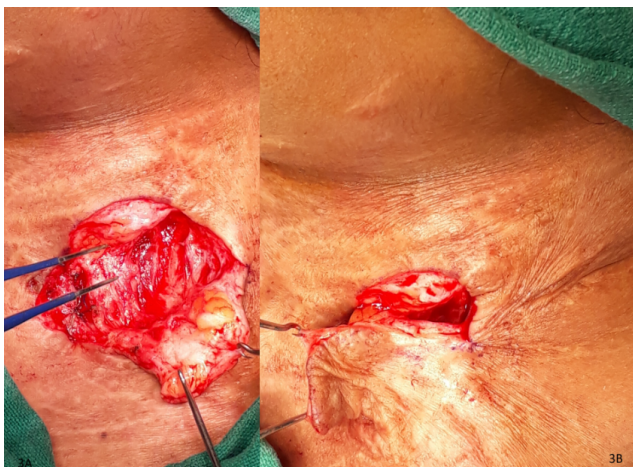

Fig. 3: Intraoperative clinical picture showing fasciocutaneous pivot flap being raised (3A) and flap rotated and transposed to suture (3B).

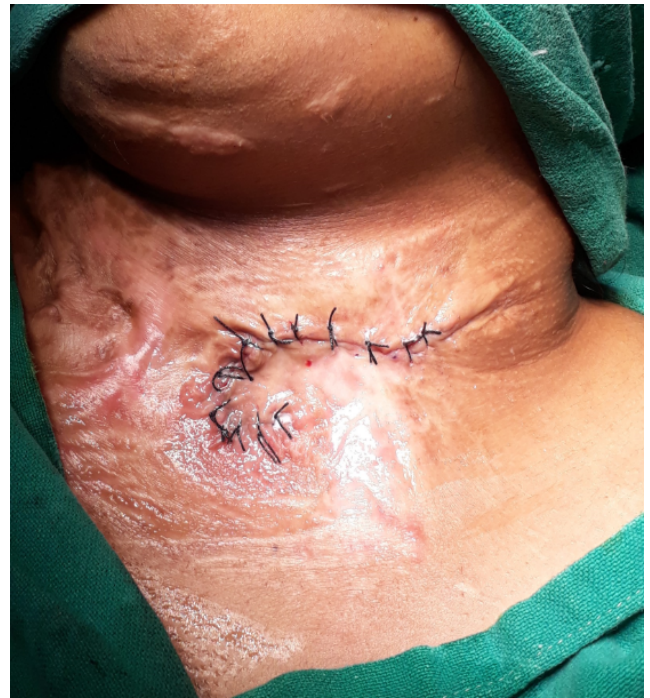

Fig. 4: Final picture after suturing flaps in position.

3. Discussion

Persistent tracheocutaneous fistula is common following prolonged cannulation or multiple tracheostomies. It is noted that, fifty percent of patients cannulated for more than a year with tracheostomy develop persistent tracheocutaneous fistulas. This happens, because with prolonged cannulation epithelium grows inwards within stoma and forms persistent non healing stoma.

Many techniques have been described in literature for closure of tracheocutaneous flap.¹⁻⁹ These procedures include multiple layered primary closure (most common type), bipedicle delayed flap closure, closure by using conchal cartilage for trachea closure and use of myocutaneous flaps, hinged turnover flaps with an advancement flap, with an additional V-Y technique.^{2,5-9}

All the above-mentioned procedure has there on limitations. Primary closure in layers is associated with complication like tracheocele, pneumopericardium, pneumothorax.¹⁰⁻¹² Using hinge flaps allows tracheal lumen to be lined with skin but using it alone has potential disadvantage of flaps giving away by a sudden strong blast of air leading to recurrence.

Using an advancement flap like fasciocutaneous flap has an added advantage of being robust and also suturing lines of fistula and flap are not in parallel avoiding recurrence of fistula.

4. Conclusion

Our technique deals with one of the many procedures used to close a tracheocutaneous fistula. It is minimally invasive and is associated with minimal chance of tracheal stenosis and recurrence.

5. Conflict of Interest

The authors declare no potential conflict of interests.

6. Source of Funding

No funding was utilized for the conduction of the study.

References

- Jacobs JR. Bipedicle delayed flap closure of persistent radiated tracheocutaneous fistulas. *J Surg Oncol*. 1995;59(3):196–8. doi:10.1002/jso.2930590312.
- Lee UJ, Goh EK, Wang SG, Hwang SM. Closure of large tracheocutaneous fistula using turn-over hinge flap and V-Y advancement flap. *J Laryngol Otol*. 2002;116(8):627–9.
- Schroeder JW, Greene RM, Holinger LD. Primary closure of persistent tracheocutaneous fistula in pediatric patients. *J Pediatric Surg*. 2008;43(10):1786–90. doi:10.1016/j.jpedsurg.2008.01.010.
- Riedel F, Goessler UR, Grupp S, Bran G, Hörmann K, Verse T, et al. Management of radiation-induced tracheocutaneous tissue defects by transplantation of an ear cartilage graft and deltopectoral flap. *Auris Nasus Larynx*. 2006;33(1):79–84. doi:10.1016/j.anl.2005.07.014.
- Berenholz LP, Vail S, Berlet A. Management of Tracheocutaneous Fistula. *Arch Otolaryngol - Head Neck Surg*. 1992;118(8):869–71. doi:10.1001/archotol.1992.01880080091020.
- Kamiyoshihara M, Nagashima T, Takeyoshi I. A novel technique for closing a tracheocutaneous fistula using a hinged skin flap. *Surg Today*. 2011;41(8):1166–8. doi:10.1007/s00595-010-4393-y.
- Eliashar R, Sichel JY, Eliachar I. A new surgical technique for primary closure of long-term tracheostomy. *Otolaryngol–Head Neck Surg*. 2005;132:115–8. doi:10.1016/j.otohns.2004.08.009.
- Rennekampff HO, Tenenhaus M. Turnover Flap Closure of Recalcitrant Tracheostomy Fistula: A Simplified Approach. *Plast Reconstr Surg*. 2007;119(2):551–5. doi:10.1097/01.prs.0000246378.43769.6d.
- Nakamura K, Yamaguchi H, Horiguchi S, Hiramatsu H, Tsukahara K, Hirose H, et al. Surgical Techniques for Closure of Tracheostoma. *Nihon Kikan Shokudoka Gakkai Kaiho*. 2001;52(4):331–5. doi:10.2468/jbes.52.331.
- Briganti V. Giant tracheocele following primary tracheostomy closure in a 3 year old child. *Interact Cardiovasc Thorac Surg*. 2004;3(2):411–2. doi:10.1016/j.icvts.2004.02.015.
- Koloutsos G, Barbetakis N, Kirodimos E, Samanidis G, Paliouras D, Vahsevianos K, et al. Pneumopericardium following tracheostomy closure. *Tuberk Toraks*. 2009;57(2):205–7.
- Wiel E, Fayoux P, Vilette B. Complications of surgical closure of tracheo-cutaneous fistula in pediatric patients — two case reports. *Int J Pediatr Otorhinolaryngol*. 2000;52(1):97–9. doi:10.1016/s0165-5876(99)00289-x.

Author biography

Manish Gupta, Professor and Head

Anshul Singh, Senior Resident

Cite this article: Gupta M, Singh A. Tracheocutaneous fistula closure by two hinged turnover flap and a fasciocutaneous pivot flap. *IP J Otorhinolaryngol Allied Sci* 2020;3(4):142-144.