



## Case Report

# Primary tuberculosis of the parotid gland- A case report

Harjitpal Singh<sup>1,\*</sup>, Ravinder Kaur<sup>2</sup>, Bindu Sood<sup>3</sup>, Tilak Bagra<sup>3</sup>

<sup>1</sup>Dept. of ENT, Dr. Radhakrishnan Govt Medical College, Hamirpur, Himachal Pradesh, India

<sup>2</sup>Dept. of Biochemistry, Dr Radhakrishnan Govt Medical College, Hamirpur, Himachal Pradesh, India

<sup>3</sup>Civil Hospital, Palampur, Himachal Pradesh, India



### ARTICLE INFO

#### Article history:

Received 15-12-2020

Accepted 25-12-2020

Available online 18-01-2021

#### Keywords:

Parotid gland

Tuberculosis

FNAC

### ABSTRACT

Tuberculosis of the parotid gland is uncommon in ENT practice. If not associated with sinus/abscess formation, it becomes difficult to differentiate it from neoplasm of the gland. In cases where it involves only the gland (Primary Tuberculosis), then the diagnosis mainly depends on high index of suspicion of the treating physician. Radiological support, FNAC or HPE are the other helping modes to arrive on a diagnosis. FNAC is a simple process with less morbidity for the patient. We treated a patient successfully with medical treatment after FNAC.

© This is an open access article distributed under the terms of the Creative Commons Attribution License (<https://creativecommons.org/licenses/by/4.0/>) which permits unrestricted use, distribution, and reproduction in any medium, provided the original author and source are credited.

## 1. Introduction

Tuberculosis is very common in developing countries, particularly from South East Asia such as India. Pulmonary tuberculosis is more common and is characterized by granulomatous inflammation with or without caseous necrosis. Extrapulmonary forms of the disease account for approximately 20% of overall active tuberculosis and can affect any organ of the body. Tuberculosis involving parotid gland is rare, even in countries, where the disease is rampant<sup>1</sup> such as India. De Pauli in 1893 was the first person to report tubercular involvement of parotid glands. The common presentation of tuberculosis involving parotid gland is as a slow-growing localized mass, indistinguishable from a neoplasm. Imaging studies only may not be of much help. For tissue diagnosis, excisional biopsy/superficial parotidectomy used to be the main stay. But now a days Fine-needle aspiration cytology (FNAC) is often the preliminary step in the workup of a patient with a parotid mass, and thus unnecessary surgery can be avoided in cases of inflammatory lesions.<sup>2</sup> We present a case of primary tuberculosis of the parotid gland in a 13 years old

female child that was diagnosed on cytology and managed medically.

## 2. Case Report

A 13 years old female child presented in the ENT OPD, with a mass in the left parotid region for one year. Physical examination revealed a non-tender, diffuse mass occupying the left parotid gland. Ultrasonography revealed a well-defined, cystic lesion with hyperechoic foci, few showing calcification, located in the superficial lobe of the left parotid gland. An FNAC of the lesion was done, which was suggestive of granulomatous lesion with multinucleated giant cells, epithelioid cell granulomas in lymphoid cell background. Chest radiography was unremarkable. Blood investigations were normal. A diagnosis of tuberculous parotid abscess was considered on Cytological basis. The patient was treated with ATT regime of rifampicin, isoniazid, pyrazinamide and ethambutol for 2 months initially and then of isoniazid and rifampicin for next 4 months. Swelling reduced with medical treatment and subsequently patient was declared recovered on completion of six months treatment.

\* Corresponding author.

E-mail address: [drharjitpal@gmail.com](mailto:drharjitpal@gmail.com) (H. Singh).

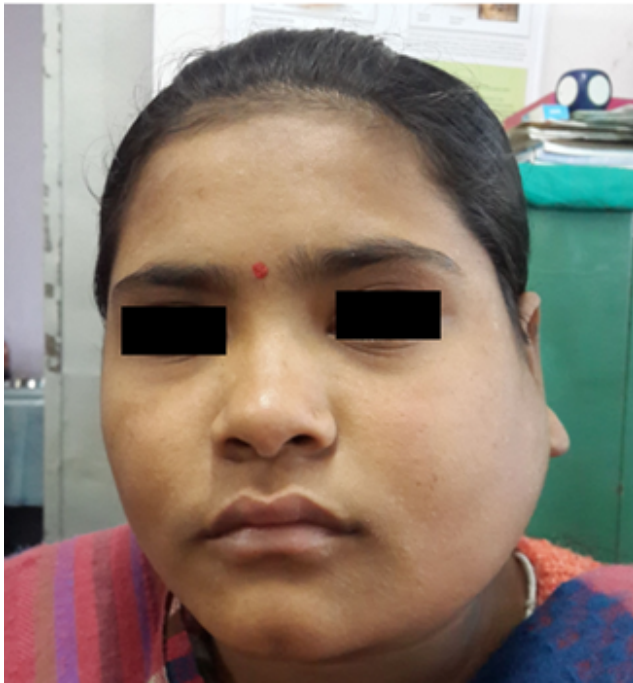

Fig. 1:

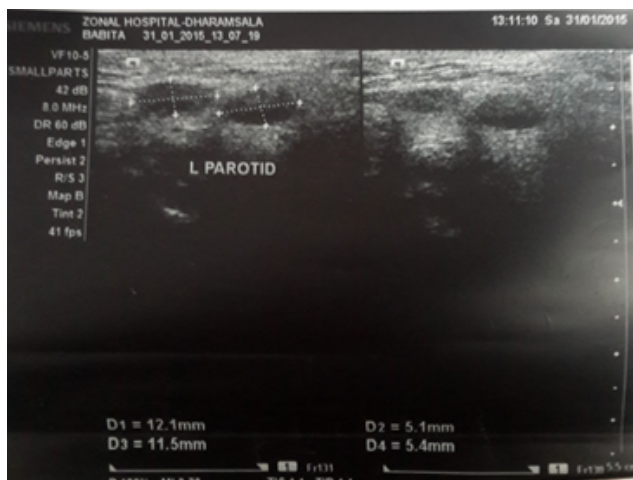


Fig. 2:

### 3. Discussion

The incidence of tuberculosis is increasing worldwide, particularly among the people of developing countries. In spite of being a common infection, primary tuberculosis of major salivary glands and particularly of the parotids is rarely seen. In a series of 323 patients with tuberculosis related with ENT sites, F. Ricciardiello et al did not observe any TB cases of the parotid gland.<sup>3</sup> Parotid tuberculosis constitutes 2.5%–10% of salivary gland tuberculosis.<sup>4</sup> Unilateral involvement of parotid gland is common<sup>2</sup> Lee IK et al in their series of 49 cases found only one case of

bilateral involvement of parotid glands.

Two pathological forms of tuberculous involvement of the parotid glands have been proposed; the common localized form is due to involvement of intraglandular/periglandular lymph nodes, whereas the second one which is less common, is due to involvement of parenchyma. This is diffuse form and may be secondary to the nodal infection.<sup>5</sup>

There are two clinical forms of tuberculous parotitis; first is acute tuberculous sialadenitis, which presents with diffuse glandular enlargement. The second type is chronic tuberculous parotitis, which manifests itself as an asymptomatic localized lesion within the parotid gland.<sup>4</sup> This type slowly grows in size for many years. In our case, the presentation was that of chronic tuberculous parotitis.

The less incidence of tuberculosis in salivary glands is believed to be due to continuous flow of saliva which prevents the lodging and growth of bacilli there. Thiocyanate ions and various proteolytic enzymes present in the secretions resist the growth of tubercular bacilli.

The route by which Mycobacterium reaches the parotid gland is still not very clear. A focus of mycobacterial infection in the oral cavity or the sputum from other parts of the body liberates bacilli in the oral cavity and the bacilli ascends into the parotid gland via its duct or pass to its associated lymph nodes via lymphatic drainage. The other pathway of spread involves hematogenous or lymphatic spread from a distant primary lung focus.<sup>6,7</sup> In this case, USG revealed enlargement of intraglandular lymph nodes of left parotid, raising possibility of lymphatic spread due to first pathway as there was no involvement of other part of body.

Fine needle aspiration cytology (FNAC) is advocated as a simple and reliable technique for the diagnosis of tuberculosis in the body including parotid gland.<sup>1,2</sup> In parotid gland lesions FNAC has shown sensitivity in the range of 81–100% and specificity in the range of 94–100%.<sup>6</sup> Hence FNAC should be performed first in the evaluation of a parotid mass along with other radiological or blood investigations. Other benefit of doing FNAC is that it is also possible to culture the aspirate in case of the report being non conclusive. Similarly AFB staining of the aspirate may be tried if needed.

Ustuner TE<sup>8</sup> et al has postulated that pulmonary focus was usually present when the parotid gland is affected. They concluded that blood and lymphatic spread was the most probable routes of spread. In the present case, there was neither a prior history of tuberculosis nor was any primary focus. Hence our case fits into the category of primary tuberculosis of the parotid gland, a rare entity. Fine needle aspiration cytology was helpful in the diagnosis and early presumptive ATT resulted in eventless healing. Similar to our case, Holmes et al,<sup>9</sup> also held that the primary disease of parotid glands was rather rare due to the inhibiting effect

saliva has over the mycobacterium.

#### 4. Conclusion

Even in the absence of tuberculosis history of the patient, tuberculous infection of the parotid gland may present as a solitary mass. So before proceeding to any surgical management of slow growing parotid mass, tuberculosis involvement must be ruled out,<sup>10</sup> by simple procedure like FNAC. In our case since the FNAC was conclusive, surgery was avoided. The patient was put on ATT for 6 months and she recovered fully.

#### 5. Conflict of Interest

The authors declare no potential conflict of interests.

#### 6. Source of Funding

No funding was utilized for the conduction of the study.

#### References

1. Aygenc E, Albayrak L, Ensari S. Tuberculous parotitis. *Inf Dis Clin Prac* . 2002;11:555–7.
2. Lee IK, Liu JW. Tuberculous parotitis: case report and literature review. *Ann Otol Rhinol Laryngol*. 2005;114(7):547–51.
3. Ricciardiello F, Martufi S, Cardone M, Cavaliere M, D'errico P, Iengo M, et al. Otorhinolaryngology-related tuberculosis. *Acta Otorhinolaryngol Ital* . 2006;26:38–42.
4. Hamdan AL, Hadi U, Shabb N. Tuberculous Parotitis: A Forgotten Entity. *Otolaryngol–Head Neck Surg*. 2002;126(5):581–2. doi:10.1067/mhn.2001.123923.
5. Handa U, Kumar S, Punia RS, Mohan H, Abrol R, Saini V, et al. Tuberculous parotitis: a series of five cases diagnosed on fine needle aspiration cytology. *J Laryngol Otol*. 2001;115(03):235–7. doi:10.1258/0022215011907073.
6. Iseri M, Aydiner O, Celik L, Peker O. Tuberculosis of the parotid gland. *J Laryngol Otol*. 2005;119:311–3.
7. Sethi A, Sareen D, Sabherwal A, Malhotra V. Primary parotid tuberculosis: varied clinical presentations. *Oral Dis*. 2006;12(2):213–5. doi:10.1111/j.1601-0825.2005.01182.x.
8. Ustuner TE, Sensoz O, Kocer U. Primary tuberculosis of the parotid gland. *Plast Reconstr Surg*. 1991;88:884–5.
9. Holmes S, Gleeson MJ, Cawson RA. Mycobacterial disease of the parotid gland. *Oral Surg Oral Med Oral Pathol Oral Radiol Endod* . 2000;90:292–8. doi:10.1067/moe.2000.107973.
10. Birkent H, Karahatay S, Akcam T, Durmaz A, Ongoru O. Primary parotid tuberculosis mimicking parotid neoplasm: a case report. *J Med Case Rep*. 2008;2(1). doi:10.1186/1752-1947-2-62.

#### Author biography

**Harjitpal Singh**, Assistant Professor

**Ravinder Kaur**, Assistant Professor

**Bindu Sood**, ENT Specialist

**Tilak Bagra**, Radiologist

**Cite this article:** Singh H, Kaur R, Sood B, Bagra T. Primary tuberculosis of the parotid gland- A case report. *IP J Otorhinolaryngol Allied Sci* 2020;3(4):136-138.