



## Original Research Article

## Assessment of adenoid hypertrophy with clinical grading versus radiology and endoscopy- A cross-sectional study

A.S.L Jyothirmal<sup>1</sup>, Sadhana O<sup>2,\*</sup>, T Satish Chandra<sup>2</sup>, P.S.N Murthy<sup>2</sup>

<sup>1</sup>Dept. of ENT, Kurnool Medical College, Kurnool, Andhra Pradesh, India

<sup>2</sup>Dept. of ENT, Dr. Pinnamaneni Siddhartha Institute of Medical Sciences & Research Foundation, Chinna Avutapalle, Andhra Pradesh, India



## ARTICLE INFO

## Article history:

Received 17-10-2020

Accepted 15-12-2020

Available online 18-01-2021

## Keywords:

Adenoid hypertrophy

Clinical grading

Endoscopy

Radiology

## ABSTRACT

**Background :** Chronic adenoid hypertrophy is the most common presentation seeking medical advice in pediatric age group. Evaluation of adenoid enlargement is usually done clinically, but its reliability in young children is questionable. Although various diagnostic procedures have been proposed to diagnose adenoid hypertrophy, there is poor concordance on the ideal method by clinicians. The purpose of this study is to corroborate a clinical grading that could guide the clinicians in accurate diagnosis of adenoid hypertrophy and to warrant the cases needing adenoidectomy and to calibrate this clinical grading with endoscopic and x-ray findings.

**Materials and Methods:** A cross-sectional study was conducted in a tertiary health care among 60 children aged between 3-14 years who presented with signs and symptoms of chronic adenoid hypertrophy are evaluated with clinical grading, endoscopy, lateral neck x-ray, and findings were documented. The proposed clinical grading comprised of nasal and paranasal symptoms, ear complaints, craniofacial abnormalities, and sleep disturbances.

**Results:** The statistical analysis was done with Pearson's Chi square test and the correlation between endoscopic and clinical grading is highly significant ( $p=0.0006$ ), and there is also a strong correlation between radiological and endoscopic grading ( $p=0.0003$ ), the correlation between clinical grading and radiological finding ( $p=0.04$ ) was significant.

**Conclusion :** Clinical grading was found to be a reliable parameter for assessment of the severity of adenoid hypertrophy. Though x-ray is a convenient procedure for diagnosing adenoid hypertrophy, it was found to be less accurate in assessing the clinical implications when compared to endoscopy.

© This is an open access article distributed under the terms of the Creative Commons Attribution License (<https://creativecommons.org/licenses/by/4.0/>) which permits unrestricted use, distribution, and reproduction in any medium, provided the original author and source are credited.

### 1. Introduction

Adenoid hypertrophy is the most common health concern among children. Adenoid is located at the junction of roof and posterior wall of nasopharynx and it is the site of contact of antigens with immune active cells and inhaled microorganisms.<sup>1,2</sup> Obstructive symptoms in children are due to rapid growth of adenoid tissue when compared to bony nasopharynx.<sup>3</sup> The nasopharyngeal tonsils are noticeable at 6 months to one year of life, show physiological

enlargement up to the age of 6- 8 years of life, and then tend to atrophy at puberty. The symptoms of adenoid hypertrophy tend to occur more among young children, because of the increased frequency of upper respiratory tract infections and the small volume of the nasopharynx.<sup>4</sup>

Enlarged and infected adenoids may cause nasal (adenoiditis, rhinosinusitis), Aural (recurrent otitis and otitis media with effusion), and obstructive sleep apnea. Other problems include excessive daytime sleepiness, failure to thrive, poor academic performance, psychological problems, and cognitive disabilities.<sup>5</sup> Currently, several diagnostic modalities are being performed aiding clinical

\* Corresponding author.

E-mail address: [sadhana.osuri@gmail.com](mailto:sadhana.osuri@gmail.com) (Sadhana O).

assessment (posterior rhinoscopy, radiography, diagnostic nasal endoscopy, acoustic rhinomanometry) for assessing adenoid hypertrophy.

**2. Materials and Methods**

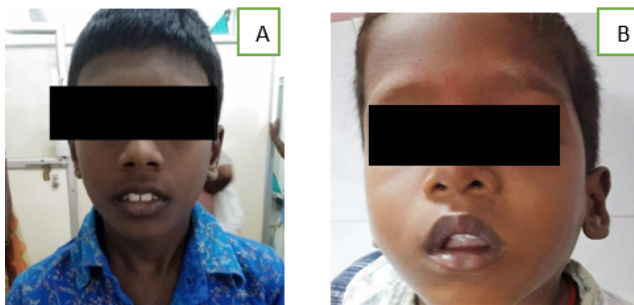This cross-sectional study was conducted in the department of Otorhinolaryngology in a tertiary health care for a period of 2 years from September 2016 to October 2018. A convenience sample of 60 children who presented with symptoms suggestive of chronic adenoid hypertrophy during the study period are evaluated clinically by enquiring a set of questionnaire and then investigated by doing diagnostic nasal endoscopy and lateral neck x-ray. Institutional ethics committee approval was obtained. All new cases within the age group of 3-14 years, of both genders who presented to the out-patient department with clinical and radiological findings of chronic adenoid hypertrophy are included. The parents of children who actively gave consent are included in the study. Children with congenital anomalies like Downs syndrome, upper respiratory tract infections, septal deviations, allergic rhinitis and other nasal conditions are excluded from the study.

**2.1. Clinical grading**

In our study, we partially modified clinical grading from previous studies<sup>6-8</sup> and proposed a clinical grading based on symptomatology- as shown in Table 1.

Each of the mentioned symptoms is given a score of 1-4 based on its severity:

Each of these values was then added together to give a total symptom score out of 16; The symptomatology score for each patient was rated into four grades, as follows: Grade I: 1-4 (mild); Grade II:5-8(moderate); Grade III:9-12(moderately severe), Grade IV:13-16(severe) -Figure 1 A,B



**Fig. 1:** A,B:Depicting adenoid facies

**2.2. Radiological evaluation of adenoid hypertrophy**

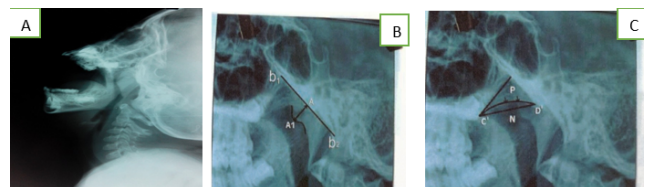
The degree of nasopharyngeal airway obstruction was assessed using an Adenoid- Nasopharyngeal ratio (ANR)

**Table 1:**

Symptom and score Nasal and paranasal Severity	
1	Mouth breathing/snoring is absent
2	Mouth breathing/snoring present on few occasions
3	Mouth breathing/ snoring present whenever asleep
4	Mouth breathing /snoring always present.
Otological	
1	Absent
2	Occasional serous otitis media / Acute Suppurative otitis media
3	Persistent Serous otitis media/ <3 episodes/ year of Acute Suppurative otitis media
4	Unilateral or bilateral chronic Suppurative otitis media of tubotympanic type/atelectasis with impending cholesteatoma
Craniofacial abnormalities	
1	Absent
2	Elongated dull looking face
3	Irregular/ crowded dentition, high arched palate, hitched upper lip
4	All features of adenoid facies
Sleep disturbances	
1	Absent
2	Present occasionally during upper respiratory tract infections
3	Present everyday with <= 3 episodes /night daily
4	>3 episodes/ night daily.

which was obtained from x-ray nasopharynx lateral view with the child in an erect position with head fixed and positioned in Frankfort horizontal plane as in Figure 2. The adenoid size(A) is obtained by drawing a perpendicular line from the anterior margin of the basiocciput to the maximum convexity of the adenoid. The nasopharynx size(N) was obtained by drawing a line between the posterosuperior edge of the hard palate and the anteroinferior edge of sphenobasioccipital synchondrosis.<sup>9</sup> - as shown in Figure 2B,C.

By using the reference points and lines, adenoid size and nasopharyngeal size were measured separately and adenoid-nasopharyngeal ratio was calculated by the arithmetic method and the result has been documented in percentage. The ANR is categorized as grade I (0- 25%), grade II (25-50%), grade III (50-75%), grade IV (75-100%).



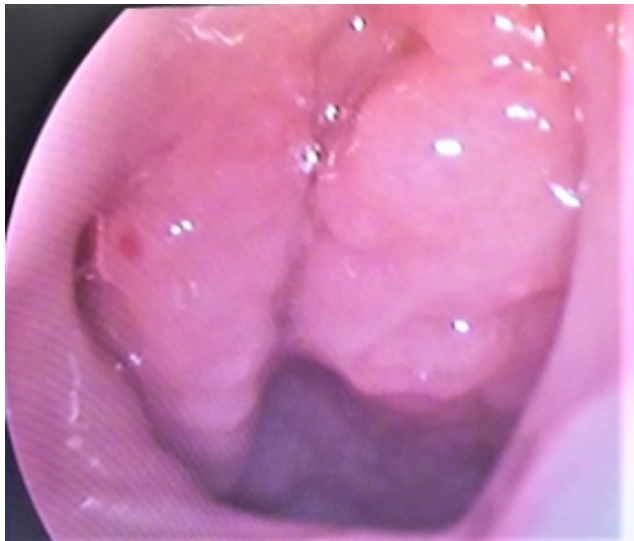**Fig. 2:** A-C:x-ray lateral view nasopharnx lateral view showing adenoid mass

Plain radiograph of lateral view nasopharynx showing calculation of ANR. b1 b2: line drawn along basiocciput anterior margin; N: nasopharynx size is distance between C1D1 (line between posterosuperior edge of hard palate and anteroinferior edge of sphenobasioccipital synchondrosis; A: adenoid size ( line drawn from maximum convexity of the adenoid (A1) to line perpendicular to its intersection with b1 b2). When synchondrosis is not visualized, D1 can be determined as the site of crossing floor of bony nasopharynx and posteroinferior margin of lateral pterygoid plates( P).

### 2.3. Endoscopic evaluation of adenoid tissue

All children underwent a transnasal rigid endoscopy after topical anesthesia application. In some children who were not willing for endoscopy under topical anesthesia they were examined under general anesthesia just before surgery. The following classification was used for grading i.e. Clements and Mc Murray.<sup>10</sup>

Grade I: adenoid tissue filling 1/3rd. of the vertical height of choana. Grade II: adenoid tissue filling up to 2/3<sup>rd</sup> of the vertical height of choana. Grade III: from 2/3rd to nearly all but not completely filling the choana. Grade IV: complete choanal obstruction as shown in Figure 3.



**Fig. 3:** Endoscopic view of adenoid

## 3. Results

Majority of patients are aged between 6-8 years (38%), with male predominance (58%). Mouth breathing and snoring was the commonest presentation (98%). On analysing the patients based on clinical symptomatology, majority presented with grade III (60%) and 1.7% presented with grade I-as shown in Table 2 .

On analyzing lateral neck x rays, 51% of the cases presented with grade III and 6.7% of the children presented

**Table 2:** Distribution of cases according to clinical grading

Clinical grade	Number of cases	Percentage
Grade I	1	1.7
Grade II	12	20.0
Grade III	36	60.0
Grade IV	11	18.3
Total	60	100.0

with grade I-as shown in Table 3.

**Table 3:** Distribution of cases according to x-ray grading

X-ray	Number of Cases	Percentage
Grade I	4	6.7
GRADE II	18	30.0
Grade III	31	51.7
Grade IV	7	11.7
Total	60	100.0

On analyzing children endoscopically, 55% of cases presented with grade III, and only 3% presented with grade I-as shown in Table 4.

**Table 4:** Distribution of cases according to endoscopic grading

Endoscopic Grading	Number of Cases	Percentage
Grade I	2	3.3
Grade II	9	15.0
Grade III	33	55.0
Grade IV	16	26.7
Total	60	100.0

### 3.1. Association between clinical and x-ray findings

The mean ANR of 60 cases is 57%. 3-5 years exhibited grade III (72%) ANR. The correlation was found to be significant between clinical grading and the x-ray grading (P=0.04). All the cases with mild (grade I) obstruction in clinical grading showed grade I hypertrophy on x-ray, and 63% of patients who had severe obstruction (grade IV) in clinical grading presented with grade III hypertrophy on x-ray – summarised in Table 5.

### 3.2. Association between clinical and endoscopic findings

The correlation between clinical and endoscopic grading is highly significant (p= 0.0006). It was observed that 90% of the cases who presented with grade IV (severe) obstruction in clinical grading demonstrated grade IV hypertrophy on endoscopy and 72 % of cases with grade III (moderately severe) clinical grading showed grade III hypertrophy on endoscopy -summarised in Table 6.

**Table 5:** Clinical and X-ray grading

Clinical grading	X-ray grading				Total
	Grade I	Grade II	Grade III	Grade IV	
Grade I	1	0	0	0	1
Grade II	2	9	1	0	12
Grade III	1	9	23	3	36
Grade IV	0	0	7	4	11
Total	4	18	31	7	60
Pearson Chi-Square – Value - 0.04					

**Table 6:** Clinical and endoscopy

Clinical Grading	Endoscopic Grading				Total
	Grade I	Grade II	Grade III	Grade IV	
Grade I	1	0	0	0	1
Grade II	1	5	6	0	12
Grade III	0	4	26	6	36
Grade IV	0	0	1	10	11
Total	2	9	33	16	60
Pearson Chi-Square – value - 0.0006					

**Table 7:** Endoscopy and X-ray

X-Ray Grading	Endoscopic Grading				Total
	Grade I	Grade II	Grade III	Grade IV	
Grade I	1	3	0	0	4
Grade II	1	5	12	0	18
Grade III	0	1	21	9	31
Grade IV	0	0	0	7	7
Total	2	9	33	16	60
Pearson Chi-Square – Value - 0.0003					

**3.3. Association between endoscopic and x-ray findings**

There is a strong significant correlation between x-ray and endoscopic grading (p=0.0003). All the cases (100%) with grade IV adenoid hypertrophy on x-ray have presented with grade IV hypertrophy on endoscopy. 75% of cases with grade I on x-ray presented with grade II on endoscopy- summarised in Table 7.

**4. Discussion**

Chronic adenoid hypertrophy is the most common presentation seeking medical advice in the pediatric age group. Symptomatic children exhibit nose and paranasal sinus symptoms, otological, sleep disturbances, and craniofacial anomalies. Although various diagnostic procedures have been proposed to diagnose the adenoid hypertrophy, there is poor concordance on the ideal method by the clinicians. Poor Cooperation from the child, radiation exposure, invasive nature, and expensiveness of diagnostic tests propels the clinicians to have a reliable method in the accurate diagnosis of severity of adenoidal obstruction.

Several studies have been done previously to evaluate the association between the clinical symptomatology and severity of adenoid hypertrophy. Inclusion of vague

symptomatology like chronic mouth breathing, nasal discharge, cough and improper selection criteria, and lack of proper grading might have led to unfavourable results in the previous studies.<sup>11,12</sup> The clinical grading which has been proposed in the current study differs from previous studies, as it included both subjective and objective aspects in the proforma and also evaluated the usual symptoms and distinct signs (Craniofacial abnormalities) experienced by symptomatic patients.

In most of the cases, there was a correlation between clinical and lateral neck x-ray grading, but in few cases clinical grading was higher than x-ray grading because of significant clinical symptomatology, and as lateral extension of adenoid can't be assessed on x-ray. In a few cases, x-ray grading was higher than clinical grading; as x-ray might be taken during the early onset of adenoid hypertrophy and in acute inflammatory conditions. Another study by Foster T Orji et al which compared clinical and x-ray findings also showed similar results.<sup>6</sup>

A highly significant correlation between endoscopy and clinical grading is mostly noticed in moderately severe to severe (grade IV & grade III) adenoid hypertrophy, which was similar to a study done by Sharifk-Kashani Sh et al where the clinical score associated well with endoscopic

findings.<sup>13</sup>

The current study found that there is a strong correlation between lateral neck x-ray and endoscopic grading which was better in cases with grade IV, reasonably good in cases with grade III, which was similar to the study by Lourenco et al where the mouth breathing children who showed small adenoid on X-ray mostly had moderate size adenoid when examined by endoscopy.<sup>2</sup> The patients with moderate size adenoid on X-ray were mostly considered large by endoscopy, and those with large adenoids on x-ray were large on endoscopic examination. Our results showed endoscopic grading was slightly greater than x-ray grading, which is similar to the study done by Ehab Taha Yaseen.<sup>14</sup>

The study done by Alex Mlynarek et al showed that the percentage of airway obstruction as assessed by lateral neck x-ray highly correlated with the findings on fiber-optic rhinoscopy.<sup>8</sup> Their research showed that video rhinoscopy is more accurate than lateral neck radiography in determining the adenoid size and predicting the severity of the disease.

In the current study, the difference between lateral neck x-ray and endoscopic grading is because of the dynamic nature of the endoscope through which postnasal space is directly visualized; whereas on x-ray, postural change in patients position during x-ray and breathing pattern alongside uncooperativeness affects the appearance of soft tissue in the radiograph. Enlargement of adenoid in lateral extension is an essential factor that is missed on a plain lateral x-ray of the postnasal space. Wright et al in their study stressed the importance of endoscope in the assessment of adenoid enlargement in the lateral direction which was missed routinely on X-ray of the postnasal space.<sup>15</sup>

When all the three methods i.e. clinical, lateral neck radiograph and endoscopic grading were compared for evaluation of chronic adenoid hypertrophy, the current study observed that both lateral neck radiograph and endoscopic grading correlated with clinical grading but endoscopic grading appears to be more accurate in assessing the adenoid size and endoscopic grading is more nearer to clinical grading than x-ray grading. So according to the current study, clinical grading plays a more significant role than any other diagnostic modality. Endoscopic grading is more accurate in assessing adenoid hypertrophy when compared to a lateral neck x-ray.

## 5. Conclusion

In the assessment of degree of adenoid hypertrophy, clinical grading was found to be a reliable parameter in children. The endoscopic method has the advantage of assessing the three-dimensional size of the adenoid. Though lateral neck radiograph is a convenient method for detecting adenoid hypertrophy, it was found to be less accurate in assessing the clinical implications, when compared to endoscopy. Patients with lower symptomatology scores can be taken up for

follow up especially where diagnostic tests are unavailable and if clinical grading increases, then further management is advocated with the help of diagnostic modalities preferably endoscopy rather than x-ray owing to its limitations.

## 6. Conflict of Interest

The authors declare no potential conflict of interests.

## 7. Source of Funding

No funding was utilized for the conduction of the study.

## References

- Peter J. The adenoid and adenoidectomy. In: George GB, Ray C, John H, Martin JB, Nicholas SJ, editors. 7th Edn.. vol. 1. London; Arnold: Hodder; 2008. p. 1095–101.
- Lourenco EA, Lopes KC, Pontes A, Oliveira MH, Umemuro A, Vargas A, et al. Comparison between radiological and laryngoscopic assessment of adenoid tissue volume in mouth breathing children. *Rev Bras Otorhinolaringol.* 2005;71:23–8.
- Jaw, Ts, Sheu RS, Liugc, Lin WC. Development of adenoids: A study by measurement with MR images. *Kaohsiung J.* 1995;15:12–8.
- Gorur K, Doven O, Unal M, Akkus N, Ozcan C. Preoperative and postoperative cardiac and clinical findings of patients with adenotonsillar hypertrophy. *Int J Pediatric Otorhinolaryngol.* 2001;59:41–6.
- Muzumdar H, Arens R. Diagnostic Issues in Pediatric Obstructive Sleep Apnea. *Proce Am Thoracic Soc.* 2008;5(2):263–73. doi:10.1513/pats.200707-113mg.
- Orji FT, Ezeanolue BC. Evaluation of adenoidal obstruction in children: clinical symptoms compared with roentgenographic assessment. *J Laryngol Otol.* 2008;122(11):1201–5. doi:10.1017/s0022215108001916.
- Yogita. Clinical and Roentgenographic Evaluation of Adenoidal Hypertrophy in Children and its Endoscopic Assessment. *National Journal of Medical and Dental Research;*2015(3):162–165.
- Mlynarek A, Tewfik MA, Hagr A, Manoukian JJ, Schloss MD, Tewfik TL, et al. Lateral Neck Radiography versus Direct Video Rhinoscopy in Assessing Adenoid Size. *J Otolaryngol.* 2004;33(06):360–5. doi:10.2310/7070.2004.03074.
- Fujioka M, Young LW, Girdany BR. Radiographic evaluation of adenoidal size in children: adenoidal-nasopharyngeal ratio. *Am J Roentgenol.* 1979;133(3):401–4. doi:10.2214/ajr.133.3.401.
- Clemens J, Murray JSM, Wiliiging JP. Electrocautery versus curette adenoidectomy: comparison of postoperative results. *Int J Pediatric Otorhinolaryngol.* 1998;43:115–22.
- Bitar MA, Rahi A, Khalifeh M, Madanat LMS. A suggested clinical score to predict the severity of adenoid obstruction in children. *Eur Arch Oto-Rhino-Laryngology.* 2006;263(10):924–8. doi:10.1007/s00405-006-0086-y.
- Elwany S. The Adenoidal Nasopharyngeal ratio [ANR]: Its validity in selecting children for adenoidectomy. *J Laryngol Otol.* 1987;101:569–73.
- Sharifkashani S, Dabirmoghaddam P, Kheirkhan M, Hosseizadehnik R. A New Clinical Scoring System for Adenoid Hypertrophy in Children. *Iranian J Otorhinolaryngol.* 2015;27(78):55–61.
- Yaseen ET, Khammas AH, Al-Anbaky F. Adenoid enlargement, Assessment by plain X-ray and Nasoendoscopy. *Iraqi J Comm Med.* 2012;2012(1):88–91.
- Wright ED, Pearl AJ, Manoukian JJ. Laterally hypertrophic adenoids as a contributing factor in otitis media. *Int J Pediatr Otorhinolaryngol.* 1988;45:207–14.

**Author biography**

**P.S.N Murthy**, Professor

**A.S.L Jyothirmai**, Senior Resident

**Sadhana O**, Assistant Professor

**T Satish Chandra**, Professor and HOD

**Cite this article:** Jyothirmai ASL, Sadhana O, Chandra TS, Murthy PSN. Assessment of adenoid hypertrophy with clinical grading versus radiology and endoscopy- A cross-sectional study. *IP J Otorhinolaryngol Allied Sci* 2020;3(4):130-135.