



Original Research Article

Prospective study of Ear, Nose and Throat manifestations in head injury cases at a tertiary care hospital

Apurva Anil Jarandikar^{1,*}, Siddhartha S. Shrivastava¹, Parmanand D Chawan¹, Sneha S Bansode¹, Jasmeet Gill¹

¹Dept. of ENT, PCMC PG Institute YCM Hospital, Pimpri, Pune, Maharashtra, India



ARTICLE INFO

Article history:

Received 08-04-2020

Accepted 02-05-2020

Available online 16-08-2020

Keywords:

Head injury

ENT manifestations

Road traffic accidents

ABSTRACT

The rapid increase in the population and Road traffic accidents led to rise in the number of head injury cases. Most of the cases reporting to the tertiary care hospitals present with injuries to ear, nose and throat. these injuries need to be addressed by ENT surgeons in addition general surgeons and neuro surgeons. A prospective study was done by us at tertiary care centre to assess the ear, nose and throat manifestations in head injury cases. The study was carried over a period of ten years and 100 patients were included. Number of male patients were more than females and young age group was affected more. This study highlights the necessity of the ENT surgeon's inclusion in the trauma team and the present study has been done to evaluate various ear, nose and throat manifestations and investigations which help in earlier diagnosis.

© 2020 Published by Innovative Publication. This is an open access article under the CC BY-NC license (<https://creativecommons.org/licenses/by-nc/4.0/>)

1. Introduction

The incidence of head injury is increasing day by day. Motor vehicle accidents constitute the single largest cause of head injury. Other causes of head injury are assaults and industrial accidents. The incidence is increasing due to increased use of vehicles by the enormous population, inadequate traffic control system, abuse of alcohol, lack of use of safety helmets and seat belts while driving.

Most of the cases present with ear, nose and throat injuries and they need special attention by the ENT surgeons in addition to general surgeons and neurosurgeons. The commonest ENT manifestations following head injury are: injury to auricle, external auditory canal, temporal bone fractures, traumatic perforation of tympanic membrane, CSF otorrhoea, hearing loss, fracture of nasal bones and facial bones, cut throat injuries, laryngeal injuries.¹ Otorhino-laryngological problems associated with Road Traffic Accidents are grave and life threatening. All the important structures are located in the head and neck. These also serve as window to the brain. The nose is prominent structure on

the face and bones of face are liable to get traumatized. Facial cosmesis and restoration of physiology of sensory organs are very important and cannot be over emphasised. Due to advent of newer technologies of investigations and treatment like high resolution CT scan, MRI, newer endoscopic surgeries the management of head and neck injuries is significantly changed in past two decades. Accurate assessment of injuries is possible because of new techniques.

This study highlights the necessity of the ENT surgeon's inclusion in the trauma team and the present study has been done to evaluate various ear, nose and throat manifestations and investigations which help in earlier diagnosis.²

2. Materials and Methods

The prospective study of 100 patients of head injury having ear, nose and throat manifestations was carried out at department of ENT in a tertiary care hospital.

The duration of study was one year.

* Corresponding author.

E-mail address: apurvajarandikar@gmail.com (A. A. Jarandikar).

2.1. Inclusions criteria

1. Patients of all age groups and genders.
2. Head injury patients who presented with ear, nose and throat manifestations.

2.2. Exclusion criteria

1. Patients with severe systemic diseases.
2. Patients who failed to follow up.
3. Patients who gave history of previous ENT diseases or surgeries.
4. Brought dead persons.

2.3. Methods of Study

Each patient was evaluated completely and detailed history was taken. Grading of head injury was done with Glasgow Coma Scale.

Basic blood investigations, radiological investigations, pure tone audiometry, nasal and laryngeal endoscopic examination was done as and when required.

The routine CT brain with HRCT temporal bone was done for patients with ear bleeding, facial palsy, CSF otorrhoea.

X - ray nasal bone lateral view was done in suspected cases of nasal bone fractures. In cases of facio- maxillary trauma CT- face with 3D reconstruction was done. In cases of hearing loss, tinnitus and traumatic perforation of tympanic membrane, pure tone audiometry was done.

CT neck was done in suspected cases of injury to larynx trachea and oesophagus.

All patients were followed up in our OPD, following discharge from hospital.

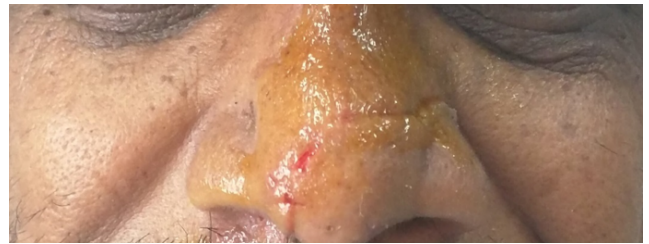
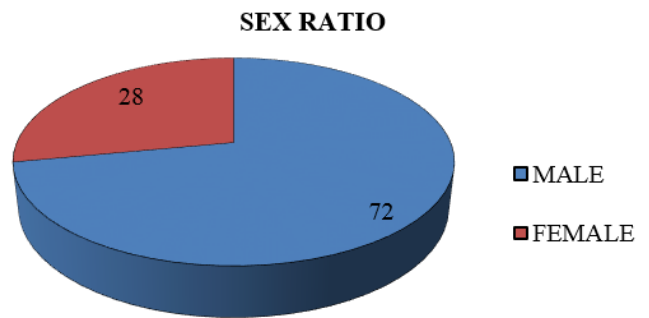
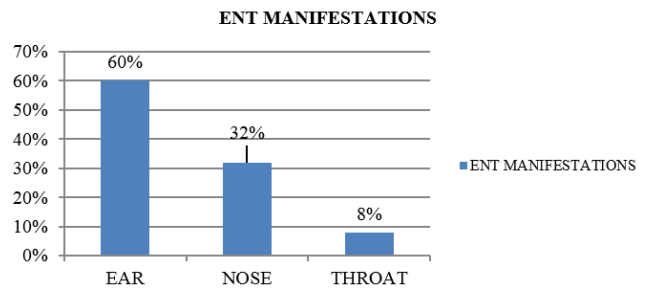


Fig. 2: Follow up after 10 days



Graph 1: Showing Gender wise Distribution



Graph 2: Showing ENT Manifestations Distribution.

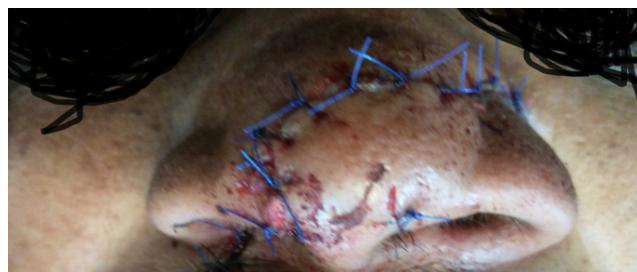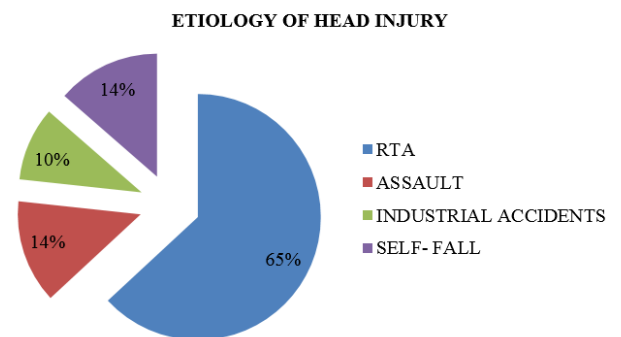


Fig. 1: Sutured lacerated wound

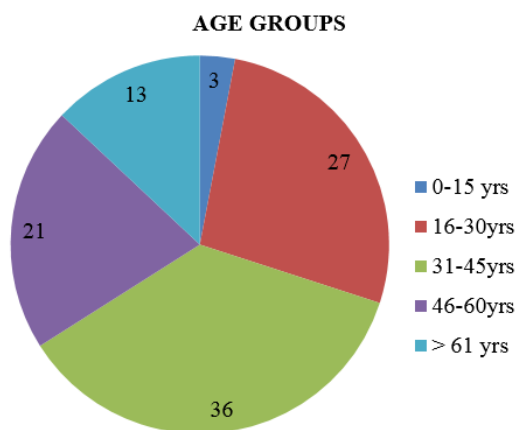
3. Results

Out of 100 patients 72 were males and 28 were females, out of which three patients were in the age group of 0-15 yrs. Maximum i.e. 36 patients were in the age group of 31-45 yrs.

Most common cause of head injury was road traffic accidents (65patients) followed by assaults, industrial accidents and self-fall.



Graph 3: Showing ENT Manifestations Distribution.



Graph 4: Showing Age wise Distribution.

Table 1: Showing Ear Manifestations

S. No.	Ear Manifestations	Numbers
1	Bleeding	14
2	Lacerations	8
3	Fracture temporal bone	5
4	Facial palsy	4
5	Hearing loss	5
6	CSF otorrhoea	4
7	Traumatic perforation	5
8	Tinnitus	6
9	Vertigo	7
Total		60

Table 2: Showing Nose Manifestations

S. No.	Nose manifestation	Numbers
1	Fracture nasal bone	15
2	Le Forts fracture	2
3	CSF Rhinorrhoea	2
4	Lacerations	10
5	Septal injuries	3
Total		32

Table 3: Showing Throat Manifestations

S. No.	Throat manifestations	Numbers
1	Vocal cord palsy	3
2	Laryngeal oedema	2
3	Laryngeal trauma	2
4	Tracheal stenosis	1
Total		8

60 patients were having ear manifestations like bleeding from the ear (14), external ear laceration (8), fracture temporal bone (5), facial palsy (4), CSF otorrhoea (4), traumatic perforation (5), tinnitus (6) and vertigo (7).

32 patients had injury to nose presenting with fracture nasal bones (15), lacerations (10), Le Fort fractures (2), septal injuries (3), CSF rhinorrhoea (2).

4. Discussion

Potstic explained in his study that trauma to external ear occurs in all age groups because the auricle has an unprotected position on the head and it is more in vehicular accidents.³ Templer et al also reported that ear injuries occur in patients of all ages. Moderate intensity force causes lacerations or even amputation of pinna.⁴

In our study, amongst all ear manifestations, 23.3% cases had bleeding from ear and 13.3% cases had ear lacerations. Lacerations of ear were sutured with all aseptic precautions and under antibiotic cover. Patients with ear bleeding were managed conservatively and were advised not to disturb the ear canal. HRCT temporal bone carried out whenever needed.

In a clinical study by Kuroda et al, they observed 43.72% cases of traumatic perforation of tympanic membrane.⁵ In our study, we observed 8.3% cases of traumatic perforation of tympanic membrane. It was treated conservatively and patients were asked for follow up in OPD. Pure tone audiometry was performed during follow up and average hearing loss was noticed in the range of 22-25dB which was conductive hearing loss. Patients with persistent tympanic membrane perforation and hearing loss were advised Tympanoplasty.

In CSF otorrhoea (6.66%), strict bed rest was advised in propped up position. The finding of the study was more or less comparable with the observations made by Raff et al and House et al.^{5,6} All cases improved by conservative management and antibiotic coverage was given and patients were monitored. HRCT brain with temporal bone was done for all the patients.

Out of 4 patients of facial palsy (6.66%), 3 patients were managed conservatively with steroids and only 1 patient required facial nerve decompression. While in the study conducted by Siddharam Patil and Girish P.B. 10% cases of facial palsy were reported and were treated conservatively.⁷

In our study, out of 32 cases, 15 cases (47%) had fracture nasal bones. Out of which 2-3 patients required fracture reduction while rest of the patients were managed conservatively. 10 cases presented with the lacerations and were sutured in the minor OT with all aseptic precautions.

Two cases of both CSF rhinorrhoea and Le Forts fracture were reported and managed with the assistance of oro - maxillofacial and neurosurgeons. While the study conducted by Adeyi A. Adoga et al all CSF rhinorrhoea cases were managed conservatively.⁸

While in throat manifestation predominant presentation was of vocal cord palsy and laryngeal oedema, followed by cut throat injuries and tracheal stenosis.

5. Source of Funding

None.

6. Conflict of Interest

None.

References

1. Abuabara A. Cerebrospinal fluid rhinorrhoea: diagnosis and management. . *Med Oral Patol Oral Cir Bucal*. 2007;12:397–400.
2. Sarafraz Z, Mirshamsi MH, Musavi SA, Azarain MH. Assessing the ignored associated injuries of the Ear, Nose and Throat in patients with multiple trauma in Shahid Rahnamun Hospital of Yazd in 2012 & 2013. . *Electron Physician*. 2015;7:1121–5.
3. Doty RL, Bromley SM. Abnormalities of Smell. Scott Brown's Otorhinolaryngology. vol. 2; 2008. p. 1667.
4. Zusho H. Posttraumatic Anosmia. *Archives of Otolaryngol- Head Neck Surg*. 1982;108:90–2.
5. Raff J, Ore P. post traumatic CSF leaks. *Arch Surg*. 1967;95:648–51.
6. House MR. Orbital forcing timescales: an introduction. In: GM E, editor. Geological Society, London, Special Publications. vol. 85. Geological Society of London; 1995. p. 1–17.
7. Patil S, B GP. Ear manifestations in head and neck injury. *Int J Otorhinolaryngol Head Neck Surg*. 2017;3(3):534–8.
8. Adeyi A, Adoga. otorhinolaryngological manifestations in head trauma: A prospective study of the epidemiology, clinical presentations, management and outcomes. *Int J Crit Illn Inj Sci*. 2017;7(4):231–5.

Author biography

Apurva Anil Jarandikar Senior Resident

Siddhartha S. Shrivastava Senior Resident

Parmanand D Chawan Consultant

Sneha S Bansode Junior Resident

Jasmeet Gill Senior Resident

Cite this article: Jarandikar AA, Shrivastava SS, Chawan PD, Bansode SS, Gill J. Prospective study of Ear, Nose and Throat manifestations in head injury cases at a tertiary care hospital. *IP J Otorhinolaryngol Allied Sci* 2020;3(2):42-45.