



Case Report

Myxoid variant of adrenocortical carcinoma in a middle aged female - A case report

Naba Hasan¹, Fatima Meraj¹, Suhailur Rahman¹, Kafil Akhtar^{1,*}

¹Dept. of Pathology, Jawaharlal Nehru Medical College, Aligarh Muslim University, Aligarh, Uttar Pradesh, India



ARTICLE INFO

Article history:

Received 16-12-2020

Accepted 22-01-2021

Available online 10-03-2021

Keywords:

Adrenal cortical malignancy

Cytokeratin

Histopathology

Immunohistochemistry

Myxoid

ABSTRACT

Adrenocortical neoplasms are rare tumours that can be diagnostically challenging in some cases. Numerous diagnostic algorithms and scoring systems are in practice to differentiate adenoma from carcinoma. Besides, the different histological variants of adrenocortical carcinoma need to be identified. We present a case of 44 year old female with vaginal bleeding with a large, heterogenous suprarenal mass on imaging. Provisional clinical diagnosis of pheochromocytoma was made and patient underwent adrenalectomy. The histological examination of tumour sections showed sheets and trabeculae of moderately pleomorphic cells with extracellular mucin deposition. Immunohistochemical evaluation showed tumour cells to be negative for chromogranin with focal pan cytokeratin positivity. Finally a diagnosis of adrenal cortical carcinoma – myxoid variant was made. Post operative period was uneventful and following en bloc resection of the tumour patient did not receive any adjuvant adrenolytic treatment. The patient is doing well at 6 months of follow up period, without any evidence of recurrence.

© This is an open access article distributed under the terms of the Creative Commons Attribution License (<https://creativecommons.org/licenses/by/4.0/>) which permits unrestricted use, distribution, and reproduction in any medium, provided the original author and source are credited.

1. Introduction

Adrenal cortical carcinoma is a very rare malignant epithelial tumour of adrenal cortical cells. The reported annual incidence is only 0.5 - 2 cases per million population, however they account for upto 14% of adrenal incidentaloma.¹ The median age of presentation is fifth to sixth decade with slight female predilection but cases have also been reported in children.^{2,3} The clinical presentation can be varied and related to either hormone excess (cushionoid features, hirsutism, virilization) or non specific symptomatology related to tumour growth (pain, abdominal fullness, general malaise).⁴

Most adrenal cortical carcinomas occur sporadically but rarely its association with hereditary syndromes like Li Fraumeni syndrome, Beckwith-Weidmann syndrome is reported in pediatric population, while in adults higher prevalence in association with Lynch syndrome, Multiple endocrine neoplasia type 1 (MEN 1) and Type 1

neurofibromatosis is well documented.⁵

Although radiological and histopathological characterization of adrenal cortical neoplasm as adenoma or carcinoma is quite straightforward, sometimes a benign tumour showing haemorrhage and revascularization on imaging and intermediate histology can pose a challenge. Histological diagnosis of adrenal cortical carcinoma is aided by a number of multiparametric scoring systems and diagnostic algorithms of which the Weiss system is most widely used.⁶ Some tumours commonly included in the differential diagnosis of adrenal cortical carcinoma include pheochromocytoma, renal cell carcinoma and sarcoma, hence immunohistochemistry plays an important role in the evaluation of adrenal masses.⁷

2. Case Summary

A 44 year old known hypertensive and hypothyroid female patient presented to the Gynaecology out patient department with complaints of bleeding per vaginum since 4 months and dull aching pain in the left lumbar region for the last

* Corresponding author.

E-mail address: drkafilakhtar@gmail.com (K. Akhtar).

3 months. There was no history of fever, cough, vomiting, altered bowel movement or any urinary complaints. The past medical history was non significant. Per abdomen examination revealed mild tenderness in the left lumbar region while per vaginum and per speculum examination did not reveal any mass/ lesion.

Ultrasound showed a large heterogenous mass in the left upper quadrant of the abdomen. An abdominal CT scan showed a heterogenous lobulated mass, measuring 6.1 x 4.2 cm in the left suprarenal region inseparable from the upper pole of the left kidney and displacing it anteriorly. Further MRI showed a large, 10 x 6x 6 cm, well marginated, heterogenous left adrenal mass abutting the upper pole and posterior margin of left kidney (Figure 1). Due to patients' financial constraints, biochemical examinations to see the hormonal status of the tumour could not be performed. Based on the clinical and radiological findings, a provisional diagnosis of left sided pheochromocytoma with renal involvement was made and patient was taken up for left adrenalectomy.

Grossly the specimen measured 12.5 x 8.2 x 3 cm in size with a well defined solid firm creamish white area of size 10.5 x 7.5 x 3 cm identified on cut section with foci of haemorrhage (Figure 2). Microscopic examination showed sheets and trabecular arrangement of tumour cells having mild to moderate anisonucleosis, hyperchromatic, irregular nuclei and moderate amount of eosinophilic cytoplasm (Figure 3). Prominent nucleoli was seen in some cells with <4 mitoses per 10 high power field. Diffuse foci of necrosis was present however no vascular invasion was noted. Sections also showed foci of extracellular myxoid background (Figure 4). Application of Weiss criteria for histological diagnosis gave a score of 3, which is consistent with malignant adrenal cortical tumour. Immunohistochemical expression of chromogranin showed negative staining (Figure 5) and pan cytokeratin showed faint focal cytoplasmic positivity (Figure 6). Based on histological morphology and immunohistochemistry, the case was signed out as myxoid variant of adrenocortical carcinoma.

3. Discussion

We present a rare case of adrenocortical carcinoma in a middle aged female who presented with vaginal bleeding for 4 months. This abnormal vaginal bleeding could be attributed to the hormonal stimulation by the tumour however this rare tumour has been frequently reported to be non functional and the initial presentation is usually due to mass effects produced by the lesion.⁸ The common clinical presentations of adrenocortical carcinoma include symptoms of hypercortisolism, hirsutism/ virilisation and general malaise.⁹ The initial presentation of the patient in this case prompted a gynaecological workup by the clinician.

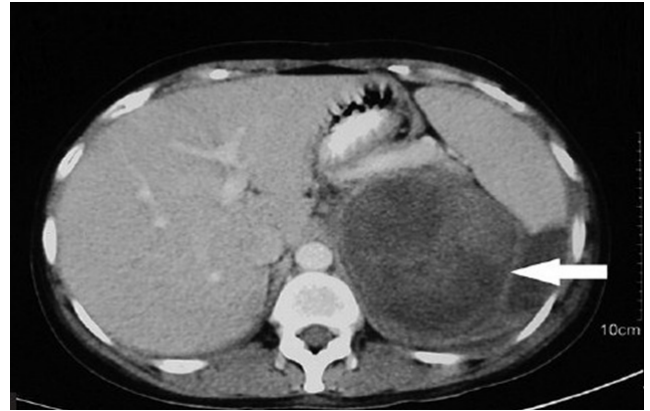

Fig. 1: MRI showed a large, 10 x 6x 6 cm, well marginated, heterogenous left adrenal mass abutting the upper pole and posterior margin of left kidney.

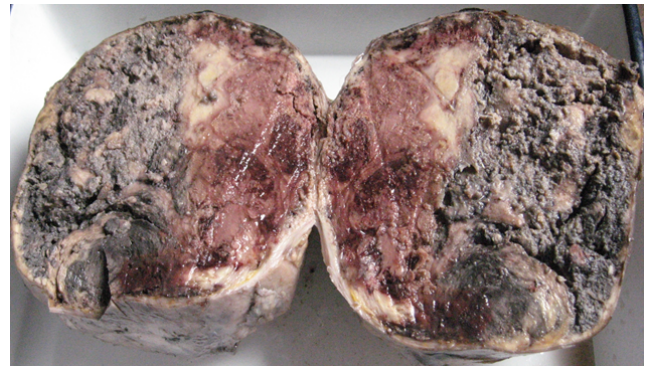


Fig. 2: Grossly the specimen measured 12.5 x 8.2 x 3 cm in size with a well defined solid firm creamish white area of size 10.5 x 7.5 x 3 cm identified on cut section with foci of haemorrhage.

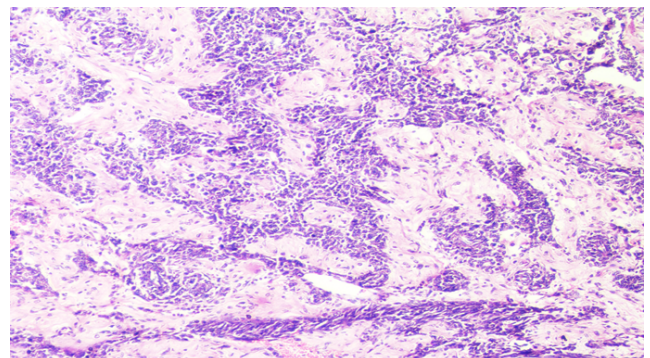


Fig. 3: Microscopic examination showed sheets and trabecular arrangement of tumour cells having mild to moderate anisonucleosis, hyperchromatic, irregular nuclei and moderate amount of eosinophilic cytoplasm. Haematoxylin and Eosin x10X.

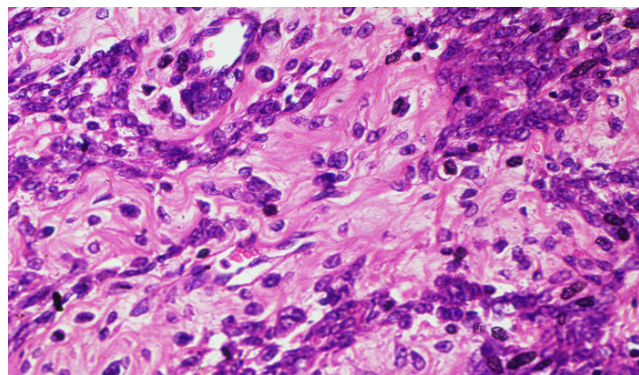


Fig. 4: Sections also showed foci of extracellular myxoid background. Haematoxylin and Eosin x10X.

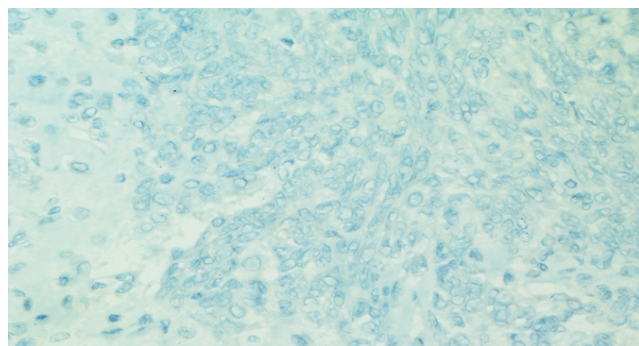


Fig. 5: Immunohistochemical expression of Chromogranin showed negative immuno-expression. IHC Chromogranin x 40X.

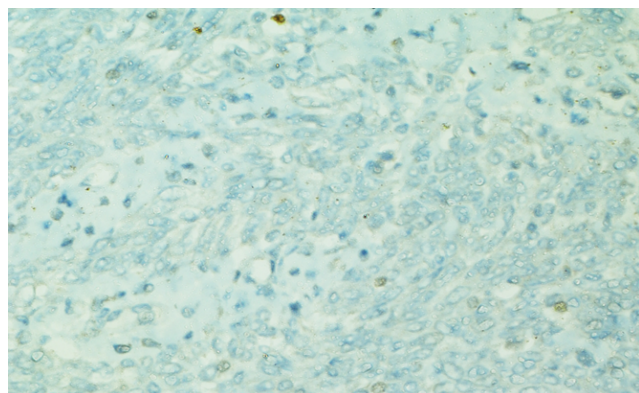


Fig. 6: Immunohistochemical expression of pan cytokeratin showed faint focal cytoplasmic positivity. IHC Cytokeratin x 40X.

Imaging plays a vital role in the assessment of adrenal masses. The adrenal cortical carcinomas usually measure >10 cm, are heterogenous and irregular masses with evidence of necrosis and haemorrhage within the tumour.¹⁰ The histopathological diagnosis of malignancy in adrenocortical tumours is aided by certain multifactorial diagnostic algorithms with high degree of concordance; Weiss score being the most popular one which takes into account parameters like nuclear grade, mitoses, percentage of clear cells, architecture, necrosis, vascular, sinusoidal and capsular invasion.¹¹ Recently modified Weiss score proposed by Aubert et al. has also come into practice.¹² The histological variants of adrenal cortical carcinoma include oncocytic, myxoid and sarcomatoid carcinoma, most common being oncocytic type. Myxoid adrenocortical carcinoma are very uncommon and often functional.¹³ Histologically this tumour is characterized by cords, clusters or pseudoglandular structures of tumour cells in a prominent myxoid background. Myxoid change in a tumour can vary from 10% to 95%.¹³

Immunophenotypically these tumours are similar to other variants, expressing markers specific for steroid producing cell like SF1, inhibin alpha, melan A and calretinin. Positivity for epithelial markers like cytokeratin, EMA and CEA is variable. Unlike chromogranin, synaptophysin is frequently expressed and hence its use for differentiation from pheochromocytoma is discouraged.^{14,15} The tumours included in the differential diagnosis of adrenal cortical carcinoma include adrenal cortical adenoma and oncocytoma (which can be differentiated on histology alone), pheochromocytoma (chromogranin positive; negative in the case described), renal cell carcinoma (positive for epithelial markers; negative in the case described).

Some other tumours that can show myxoid change in this location include myxoma, liposarcoma, malignant fibrous histiocytoma and nerve sheath tumours etc. However careful histological, radiological and histological evaluation of the tumour alongwith an appropriate immunohistochemical panel including markers associated with adrenocortical differentiation can help to establish the correct diagnosis.¹⁵

Gene expression profiling of adrenocortical tumours has elucidated the molecular pathogenesis of these tumours with emerging evidence for an adenoma to carcinoma progression. Studies have identified IGF2 as one of the most highly expressed genes in carcinoma while two other genes namely DLGAP5 and PINK1 have been identified in adrenocortical tumours of uncertain malignant potential and related with recurrence.^{16,17}

Surgery is the mainstay of treatment and the only potentially curative option. Adjuvant adrenolytic treatment with mitotane is offered to patients with incomplete/uncertain resection which is shown to reduce the risk of local recurrence.¹⁰ Radiotherapy of tumour bed

is recommended in incompletely resected tumours or those with complete resection but high risk (microscopic evidence of vascular invasion or Ki-67 >10%).¹⁸ The five year overall survival of patients with adrenocortical carcinoma is below 40%. The European Network for the Study of Adrenal Tumours (ENSAT) Staging Score, which assesses the extent of disease at the time of diagnosis is utilized as a major determinant of survival. Other prognostic factors include tumour grade, mitotic count and ki-67 proliferation index.¹⁹ p53 and CTNBB1 immunohistochemistry has been widely utilized as surrogates for molecular alteration in the two major signalling pathways of adrenocortical carcinoma, which also correlate with aggressive phenotypes and poor survival.²⁰

4. Conclusions

Adrenocortical carcinomas are rare tumours with varied clinical presentations or discovered incidentally. Tumours with unusual histology like myxoid need to be identified because of its rarity and to initiate immediate therapeutic interventions. Proper radiological and histological evaluation together with application of a panel of markers is indispensable in the work up of these adrenal masses.

5. Source of Funding

No financial support was received for the work within this manuscript.

6. Conflict of Interest

The authors declare they have no conflict of interest.

References

- Sharma E, Dahal S, Sharma P, Bhandari A, Gupta V, Amgai B, et al. The Characteristics and Trends in Adrenocortical Carcinoma: A United States Population Based Study. *J Clin Med Res* . 2018;10(8):636–40. doi:10.14740/jocmr3503w.
- Kebebew E, Reiff E, Quan-Yang D, Clark OH, McMillan A. Extent of Disease at Presentation and Outcome for Adrenocortical Carcinoma: Have We Made Progress? *World J Surg*. 2006;30(5):872–8. doi:10.1007/s00268-005-0329-x.
- de Melo-Leite A, Elias PL, Teixeira SR, Tucci S, Barros GE, Antonini SR, et al. Adrenocortical neoplasms in adulthood and childhood: distinct presentation. Review of the clinical, pathological and imaging characteristics. *J Pediatric Endocrinol Metab*. 2017;30(3):253–76. doi:10.1515/jpem-2016-0080.
- Nunes JM, Rodrigues E, Rios E, Eloy C, Carvalho I, Simoes MS. Adrenocortical Carcinoma-A 25 Years Tertiary Centre Experience and Short Review of the Literature. *Endocrinol Metab Int J*. 2018;6(1):148.
- Lerario AM, Moraitis A, Hammer GD. Genetics and epigenetics of adrenocortical tumors. *Mol Cell Endocrinol*. 2014;386(1-2):67–84. doi:10.1016/j.mce.2013.10.028.
- Ahmed AA, Thomas AJ, Ganeshan DM, Blair KJ, Lall C, Lee JT, et al. Adrenal cortical carcinoma: pathology, genomics, prognosis, imaging features, and mimics with impact on management. *Abdominal Radiol*. 2020;doi:10.1007/s00261-019-02371-y.
- Duregon E, Volante M, Bollito E, Goia M, Buttigliero C, Zaggia B, et al. Pitfalls in the diagnosis of adrenocortical tumors: a lesson from 300 consultation cases. *Human Pathol*. 2015;46(12):1799–807. doi:10.1016/j.humpath.2015.08.012.
- Allolio B, Fassnacht M. Clinical review: adrenocortical carcinoma: clinical update. *J Clin Endocrinol Metab*. 2006;91:2027–37.
- Bronswijk MJ, Laenen A, Bechter OE. Clinical presentation, treatment modalities and outcome in patients with adrenocortical carcinoma: A single center experience. *Neoplasma*. 2020;67(01):209–13. doi:10.4149/neo_2019_190105n17.
- Fassnacht M, Libé R, Kroiss M, Allolio B. Adrenocortical carcinoma: a clinician's update. *Nat Rev Endocrinol*. 2011;7(6):323–35. doi:10.1038/nrendo.2010.235.
- Libé R. Clinical and molecular prognostic factors in adrenocortical carcinoma. *Minerva Endocrinol*. 2018;44(1):58–69. doi:10.23736/s0391-1977.18.02900-0.
- Aubert S, Wacrenier A, Leroy X, Devos P, Carnaille B, Proye C, et al. Weiss system revisited: a clinicopathologic and immunohistochemical study of 49 adrenocortical tumors. *Am J Surg Pathol*. 2002;26(12):1612–9.
- Papotti M, Volante M, Duregon E, Delsedime L, Terzolo M, Berruti A, et al. Adrenocortical Tumors With Myxoid Features: A Distinct Morphologic and Phenotypical Variant Exhibiting Malignant Behavior. *Am J Surg Pathol*. 2010;34(7):973–83. doi:10.1097/pas.0b013e3181e2b726.
- Karim RZ, Wills EJ, McCarthy SW, Scolyer RA. Myxoid variant of adrenocortical carcinoma: Report of a unique case. *Pathol Int*. 2006;56(2):89–94. doi:10.1111/j.1440-1827.2006.01929.x.
- Weissferdt A, Phan A, Suster S, Moran CA. Myxoid adrenocortical carcinoma: a clinicopathologic and immunohistochemical study of 7 cases, including 1 case with lipomatous metaplasia. *Am J Clin Pathol*. 2013;139:780–6.
- de Fraipont F, Atifi ME, Cherradi N, Moigne GL, Defaye G, Houlgate R, et al. Gene Expression Profiling of Human Adrenocortical Tumors Using Complementary Deoxyribonucleic Acid Microarrays Identifies Several Candidate Genes as Markers of Malignancy. *J Clin Endocrinol Metab*. 2005;90(3):1819–29. doi:10.1210/jc.2004-1075.
- de Reyniès A, Assié G, Rickman DS, Tissier F, Groussin L, René-Corail F, et al. Gene Expression Profiling Reveals a New Classification of Adrenocortical Tumors and Identifies Molecular Predictors of Malignancy and Survival. *J Clin Oncol*. 2009;27(7):1108–15. doi:10.1200/jco.2008.18.5678.
- Polat B, Fassnacht M, Pfreundner L, Guckenberger M, Bratengeier K, Johanssen S, et al. Radiotherapy in adrenocortical carcinoma. *Cancer*. 2009;115(13):2816–23. doi:10.1002/encr.24331.
- Jouinot A, Bertherat J. Management of endocrine disease: adrenocortical carcinoma: differentiating the good from the poor prognosis tumors. *Eur J Endocrinol*. 2018;178(5):R215–30. doi:10.1530/eje-18-0027.
- Tissier F, Cavard C, Groussin L, Perlemoine K, Fumey G, Anne-Marie H, et al. Mutations of β -Catenin in Adrenocortical Tumors: Activation of the Wnt Signaling Pathway Is a Frequent Event in both Benign and Malignant Adrenocortical Tumors. *Cancer Res*. 2005;65(17):7622–7. doi:10.1158/0008-5472.can-05-0593.

Author biography

Naba Hasan, Senior Resident

Fatima Meraj, Junior Resident

Suhailur Rahman, Assistant Professor

Kafil Akhtar, Professor

Cite this article: Hasan N, Meraj F, Rahman S, Akhtar K. Myxoid variant of adrenocortical carcinoma in a middle aged female - A case report. *IP J Diagn Pathol Oncol* 2021;6(1):76-79.