

# Oral Squamous Cell Carcinoma of Tongue in a Young Patient - A Rare Case Report and Review of Literature.

Kavitha Gaddikeri<sup>1</sup>, Deepak D Bhorgonde<sup>2</sup>

<sup>1</sup>Reader, Department of Oral & Maxillofacial Pathology, S.B Patil Dental College and Hospital, Bidar, Karnataka, India.

<sup>2</sup>Professor & Head, Department of Prosthodontics, S.B Patil Dental College and Hospital, Bidar, Karnataka, India.

Received: November 2016

Accepted: November 2016

**Copyright:** © the author(s), publisher. Annals of International Medical and Dental Research (AIMDR) is an Official Publication of "Society for Health Care & Research Development". It is an open-access article distributed under the terms of the Creative Commons Attribution Non-Commercial License, which permits unrestricted non-commercial use, distribution, and reproduction in any medium, provided the original work is properly cited.

## ABSTRACT

Oral Squamous cell carcinoma is the most common malignant neoplasm affecting oral cavity, generally seen in individuals over 50 years of age and rarely before 40 years of age. As OSCC is rare in younger group, it may be often misdiagnosed resulting in inappropriate treatment leading to poor survival rates. Here we report a case of OSCC of left lateral border of the tongue in a 38 year old male patient and also review its literature.

**Keywords:** Oral cancer, Squamous cell carcinoma, Tongue.

## INTRODUCTION

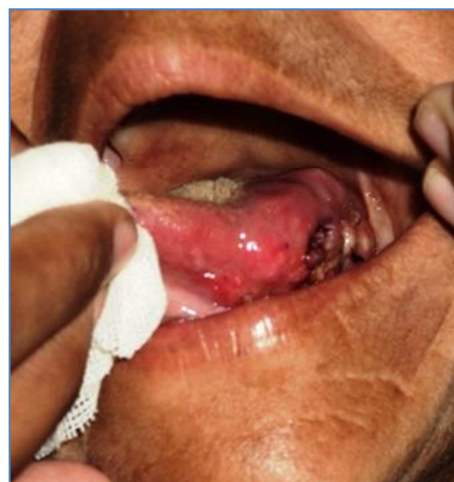Oral squamous cell carcinoma (OSCC) is most common cancer affecting head and neck region (above 90 % cases).<sup>[1]</sup> Pindborg et al (1977) defined squamous cell carcinoma as "a malignant epithelial neoplasm exhibiting squamous differentiation as characterized by the formation of keratin pearls and/or presence of intercellular bridges".<sup>[1,2]</sup> Globally, oral cancer makes for about 2%–4% of all cancer cases. However in Indian subcontinent the percentage of oral cancers was found to be more, around 45% in India and 10% in Pakistan. Worldwide, more than 3 lakh new cases of oral and oropharyngeal cancer were diagnosed between 2004-2009 and more than 7,000 died due to these cancers.<sup>[3,4]</sup> Its etiology is multifactorial, tobacco consumption in various forms being the main causative agent. It usually affects older males aged more than 50 years (5th to 8th decades) and rarely seen before 40 years. In the last few decades due to easy availability of tobacco in attractive forms, the incidence of OSCC has increased alarmingly and more so in younger individuals.<sup>[3-5]</sup> Here, we report a rare case of OSCC on lateral surface of tongue in a young patient.

### Name & Address of Corresponding Author

Dr. Kavitha Gaddikeri  
Reader,  
Department of Oral & Maxillofacial Pathology,  
S.B Patil Dental College and Hospital,  
Bidar, Karnataka, India.

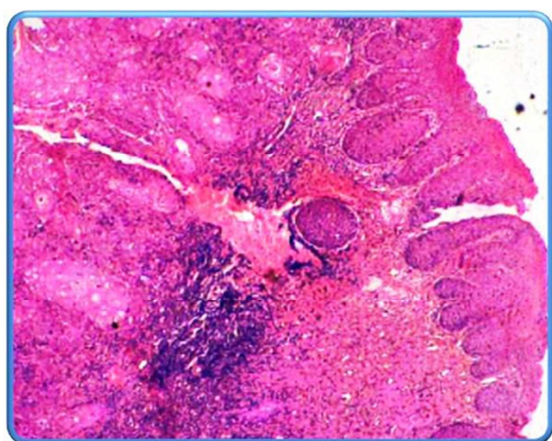
## CASE REPORT

A 38 year old male patient came to the department of oral and maxillofacial pathology with a chief complaint of slight pain and discomfort in the tongue since 6 months. Patient gave a history of tobacco chewing since 5 years, 8-10 gutkha packets per day and consumption of alcohol once a week. Examination revealed an ulcerative lesion over left lateral border of the tongue measuring approximately 3x2 cm. The margins of the lesion were irregular and indurated [Figure 1]. His medical and family history was insignificant. He did not had any difficulty in mouth opening and adjacent teeth were normal without any sharp edges. Lymph nodes were not palpable.



**Figure 1:** Intraoral view showing ulcerative lesion on lateral border of tongue.

Based on the history and clinical findings a malignant ulcer was kept in mind and an incisional biopsy was carried out. Histopathological examination revealed a para-keratinised stratified squamous surface epithelium with dysplastic features like abnormal mitosis, individual cell keratinisation. There was loss in continuity of the epithelium at few places and epithelium was seen invading into the connective tissue and keratin pearl formation was evident at many sites. The connective tissue showed few epithelial islands showing dysplastic features, surrounded by chronic inflammatory cells [Figure 2].



**Figure 2: Photomicrograph showing a well differentiated squamous cell carcinoma.**

A confirmative diagnosis of well differentiated squamous cell carcinoma was made and the patient was referred to oncology department where a Magnetic Resonance Imaging (MRI) and a Positron Emission Tomography (PET) scan was done. There was no evidence of regional lymphatic spread or distant metastasis. Hence as per standard oncological staging, T2N0M0 was given. Partial glossectomy was carried out and patient was called up for regular follow-up.

## DISCUSSION

In last few decades, the occurrence of OSCC has shown a rapid increase causing a high rate of morbidity and mortality. Studies have shown cancer in all forms causes about 18% of the deaths worldwide. The term “oral cancer” is a broader nomenclature that encompasses cancers of the tongue, lip, buccal mucosa, floor of mouth, tongue, pharynx and other parts of oral cavity. According to WHO, oral cancer has one of the highest mortality rates compared to other cancers.<sup>[5-8]</sup>

Studies have shown that the mean age at the diagnosis of OSCC to be 61 years. Only about 2% of patients with OSCC are diagnosed before 35 years age and only about 7% before 45 years. But our

patient was 38 years, very young and the finding is rare when compared to the median age of OSCC occurrence. Recent studies have shown an increasing trend for appearance of OSCC in younger individuals.<sup>[9]</sup> Atual et al reported an increase of percentage of OSCC of tongue cases in young adults from 3% annually from 1953 to 1962 to 7% annually during 1983 to 1992.<sup>[10]</sup> Myers et al also found similar results of gradually increase in occurrence of OSCC tongue in younger adults during the past 25 years.<sup>[11]</sup> This rapid increase in the incidence of OSCC, especially in younger individuals is implicated to several inter-related aspects like lifestyle factors including chronic usage of tobacco in various forms, alcohol consumption as habit or as social drinking, smoking and nutritional factors. Genetic factors have also been shown to have a predominant role in occurrence of OSCC. This detection of OSCC in younger individuals might be also due to increased awareness among general public as well as improved diagnostic aids in recent time.<sup>[9-11]</sup>

Tobacco consumption has been the main causative agent for OSCC. But due to the rarity of OSCC in younger patients, it is not clear regarding the etiological factors related to the development of OSCC in them. Kuriakose et al compared the role of etiological factors for OSCC tongue in young and older individuals and concluded that OSCC in younger patients was associated with fewer etiologic factors.<sup>[12]</sup> Sankaranarayanan et al compared percentage of patients without tobacco habit in younger and older individuals and found that 82% of patients under 30 years of age and only 10 % of patients above 30 years of age did not had tobacco-related habits.<sup>[13]</sup> Whereas Miller et al found in their study that most of the patients with OSCC tongue, who were under 40 years of age had a habit of heavy smoking and drinking.<sup>[14]</sup> The patient in our case gave a history of tobacco chewing in form of gutkha and alcohol consumption for the past 5 years. Many studies have been conducted to compare aggressiveness and recurrence rates of OSCC tongue in younger and older patients and shown higher recurrence rate and a smaller survival rate in the younger patients.<sup>[12-15]</sup>

The commonest site of OSCC was tongue, followed by buccal mucosa, lips and floor of mouth. The site of OSCC in our case was left lateral border of tongue. Commonly OSCC appears clinically as ulcer and sometimes as a lump. In our case, it appeared as a ulcerative lesion.<sup>[5,6]</sup>

Even though oral cavity is easy to view for clinical examination, most of the OSCC cases are diagnosed in advanced stages. This might be due to lack of knowledge among clinicians and also due to the ignorance of the patients also and the fact that in initial stages, OSCC remains painless also prevents the patients to approach dental surgeons. It still remains unproven if oral cancer in younger patients

is inherently more aggressive with a worse prognosis than the disease in older individuals.<sup>[3-5]</sup> Further in depth studies are needed to better understand the behaviour and carcinogenesis process in these patients.

## CONCLUSION

OSCC may occur even in younger individuals. It should be considered in the differential diagnosis of ulcerative lesions in young patients also. Early diagnosis is vital in successful treatment of OSCC. Clinicians must have adequate knowledge about ulcers, red or white plaques over tongue and mainly the lesions that persist for more than two weeks, as these have malignant potential. In such cases, biopsy is mandatory and use of newer technologies should be carried out to detect OSCC in early stages, to reduce the morbidity and mortality of this dreadful disease.

## REFERENCES

1. Singh A, Kumar A, Berwal V, Kaur M. Squamous Cell Carcinoma of Tongue- A Case Report. *J Adv Med Dent Scie* 2014;2(1):146-148.
2. Singh HP, Kumar P, Aggarwal P, Goel R. De-novo squamous cell carcinoma of an edentulous ridge. *Clin Cancer Investig J* 2012;1:83-5
3. Ramesh G, Pathak S, Gupta B, Raj A, Pathak R. Is Blood group an important factor in oral cancer? – A Review. *Rama Univ J Dent Sci* 2015;2(4):17-22.
4. Khalili, J. Oral cancer: risk factors, prevention and diagnostic. *Experiment Oncology* 2008; 30 (4):259-64.
5. Parkin DM, Bray F, Ferlay J and Pisani P. Estimating the world cancer burden: Globocan 2000. *Int. J. Cancer* 2001;94:153-6.
6. Friedlander PL, Schantz SP, Shaha AR, Yu G, Shah JP. Squamous cell carcinoma of the tongue in young patients: A matched-pair analysis. *Head Neck* 1998;20:363-8.
7. Burzynski NJ, Flynn MB, Faller NM, Ragsdale TL. Squamous cell carcinoma of the upper aerodigestive tract in patients 40 years of age and younger. *Oral Surg Oral Med Oral Pathol* 1992;74:404-8.
8. Sharma P, Saxena S, Aggarwal P. Trends in the epidemiology of oral squamous cell carcinoma in Western UP: an institutional study. *Ind J Dent Res* 2010; 21: 316-9.
9. Patel SC, Carpenter WR, Tyree S, et al. Increasing incidence of oral tongue squamous cell carcinoma in young white women, age 18 to 44 years. *J Clin Oncol* 2011; 29(11): 1488-94.
10. Atual S, Greman R, Laippala P, Syrjanen S. Cancer of the tongue in patients younger than 40 years. *Arch Otolaryngol Head Neck Surg* 1996;122:1313-9.
11. Myers JN, Elkins T, Roberts D, Byers RM. Squamous cell carcinoma of the tongue in young adults: Increasing incidence and factors that predict treatment outcomes. *Otolaryngol Head Neck Surg* 2000;122:44-51.
12. Kuriakose M, Sankaranarayanan M, Nair MK, Cherian T, Sugar AW, Scully C, et al . Comparison of oral squamous cell carcinoma in younger and older patients in India. *Eur J Cancer B Oral Oncol* 1992;28:113-20.
13. Sankaranarayanan R, Najeeb Mohideen M, Krishnan Nair M, Padmanabhan TK. Aetiology of oral cancer in patients < 30 years of age. *Br J Cancer* 1989;59:439-40.
14. Miller RH, Lipkin A, Woodson GE. Squamous cell carcinoma of the oral cavity, pharynx and larynx in young adults. *Laryngoscope* 1985;95:790-3.
15. Taghavi N, Yazdi I. Prognostic factors of survival rate in oral squamous cell carcinoma: clinical, histologic, genetic and molecular concepts. *Arch Iran Med* 2015;18:314-9.

**How to cite this article:** Gaddikeri K, Bhorgonde DD. Oral Squamous Cell Carcinoma of Tongue in a Young Patient - A Rare Case Report and Review of Literature. *Ann. Int. Med. Den. Res.* 2017; 3(1):DE07-DE09.

**Source of Support:** Nil, **Conflict of Interest:** None declared