



## Original Research Article

## A clinicopathological study of non-infectious papulo - squamous lesions of skin

V. L. Kusuma Chandrika<sup>1</sup>, Krishna Tadepalli<sup>2,\*</sup><sup>1</sup>Dept. of Pathology, SK Diagnostics, North Kamalnagar, Secunderabad, Telangana, India<sup>2</sup>Dept. Of Pathology, SVS Medical College, Yenugonda, Mahabubnagar, Telangana, India

## ARTICLE INFO

## Article history:

Received 15-02-2020

Accepted 24-02-2020

Available online 04-06-2020

## Keywords:

Papulosquamous lesions

Lichen Planus

Psoriasis

## ABSTRACT

**Aim:** The prospective study is aimed to study the clinicopathological characteristics of various non infectious papulo - squamous lesions among the skin biopsies.

**Materials and Methods:** Skin biopsies of patients presenting with clinical manifestations of Papulo - squamous lesions to the outpatient Department of dermatology. A total of 65 cases were studied.

**Results:** During the study period total number of skin biopsies received was 192, among These, non infectious Papulo - squamous lesions were 65, accounting to 33.85%. In the present study Lichen Planus (64.6 %) was the most common lesion followed by Psoriasis (24.6 %), Pityriasis Rosea (6.2%), and Pityriasis Rubra Pilaris (3.1 %).

**Conclusion:** Papulo - squamous lesions of skin are commonly seen by Dermatologists in their daily practice and because of the considerable overlap in their clinical pattern, presentation and distribution, clinical diagnosis is often difficult. So histopathological study will give a conclusive diagnosis.

© 2020 Published by Innovative Publication. This is an open access article under the CC BY-NC license (<https://creativecommons.org/licenses/by-nc/4.0/>)

## 1. Introduction

Papulo - squamous diseases comprise the largest conglomerate of skin diseases seen by the Dermatologist. The frequency of occurrence of Papulo - squamous diseases is high.<sup>1</sup> It is feasible to consider them in a group because all of them are characterized by similar morphological characteristics. The morphology is characterized by primary lesion most commonly a papule, usually erythematous, with a variable degree of scaling on the surface and plaques through coalescing of primary lesions. This amounts a lot of confusion and hence a definitive histopathological diagnosis goes a long way in treatment of such diseases.<sup>2</sup>

The interpretation of many skin biopsies requires identification and interpretation of two different morphological features – the tissue reaction pattern and pattern of inflammation. Although histopathological study is considered the gold standard in diagnosing dermatological lesions, it has its own limitations and very often a definite

specific diagnosis is not possible. In these cases correlation of histopathological findings with clinical findings will make a diagnosis possible.<sup>3</sup>

The present study is a prospective study done to evaluate the role of histopathology in the diagnosis of Papulo squamous lesions of skin and its correlation with clinical signs and symptoms. The major non infectious Papulo squamous lesions included in the study are psoriasis, parapsoriasis, lichen planus, lichen nitidus, lichen striatus, Pityriasis rosea, and Pityriasis rubra pilaris.

## 2. Materials and Methods

The present study was conducted in department of pathology. Various non infectious Papulo - squamous lesions in relation to age and sex were evaluated. The incidence of various types of non infectious Papulo - squamous lesions were evaluated. Histopathological features of various non infectious Papulo - squamous lesions were studied. Clinico - pathological correlation of non infectious Papulo - squamous lesions were analysed and

\* Corresponding author.

E-mail address: [tadepalli@yahoo.co.in](mailto:tadepalli@yahoo.co.in) (K. Tadepalli).

compared with other similar studies.

### 3. Results

**Table 1:** Non- infectious Papulo - squamous lesions in comparison to total skin biopsies

Lesion	No. of Cases	Percentage (%)
Non Infectious Papulo - squamous Lesions	65	33.85
Other Skin Lesions	127	66.15
Total Skin Biopsies	192	100

**Table 2:** Distribution of Non Infectious Papulo - squamous Lesions

Disease	No. of Cases	Percentage (%)
Lichen Planus	42	64.6
Psoriasis	16	24.6
Pityriasis Rosea	04	6.2
Pityriasis Rubra Pilaris	02	3.1
Lichen Nitidus	01	1.5
Total	65	100

**Table 3:** Gender Distribution of Non-Infectious Papulo - squamous Lesions

Disease	Male	Female
Lichen Planus	14	28
Psoriasis	10	06
Pityriasis Rosea	02	02
Pityriasis Rubra Pilaris	01	01
Lichen Nitidus	01	0
Total	28	37

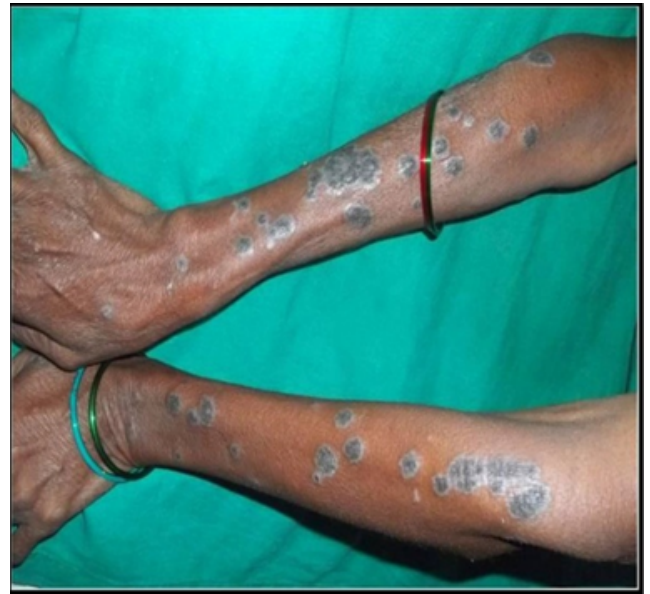**Table 4:** Clinicopathological correlation

Histopathological diagnosis	Clinical Diagnosis	Clinically Different Diagnosis
Lichen Planus	38	04
Psoriasis	15	01
Pityriasis Rosea	04	0
Pityriasis Rubra Pilaris	02	0
Lichen Nitidus	01	0
Total	60	05

Out of 65 cases, 60 cases (92%) cases showed positive clinicopathological correlation and 5 cases (8%) showed clinicopathological discrepancies (Table 1). Histopathologically most cases of lichen planus showed irregular acanthosis, wedge shaped hypergranulosis in the epidermis and band like lymphocytic infiltrate in the superficial dermis (Figure 1). Civatte bodies were noted in

23.80% of cases and Max Joseph spaces were seen in 11.90% (Table 2) (Table 3).

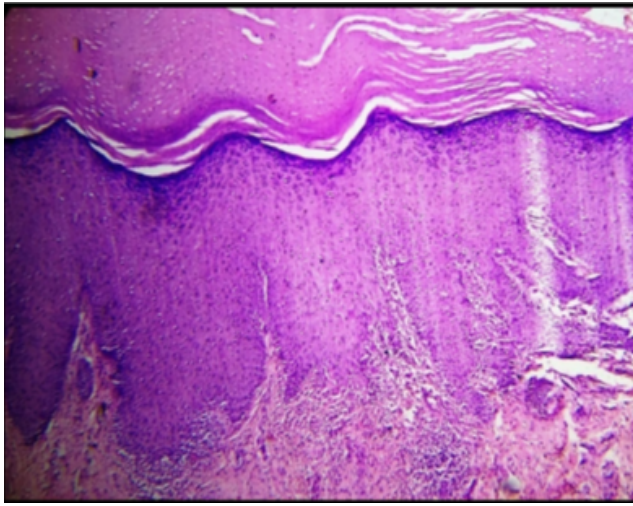
Histopathologically, common features were in psoriasis: Hyperkeratotic epidermis with psoriasiform hyperplasia, elongated rete ridges with suprapapillary thinning. Munro Microabscesses were seen in 25% cases. Scattered inflammatory cells and edema were also noted in 12 and 8 cases respectively (Figures 2 and 3). All four cases of Pityriasis Rosea showed epidermal acanthosis and perivascular dermal infiltrates. Slight spongiosis and Extravasated erythrocytes in the dermis extending up to epidermis were seen in 3 cases (Table 4).



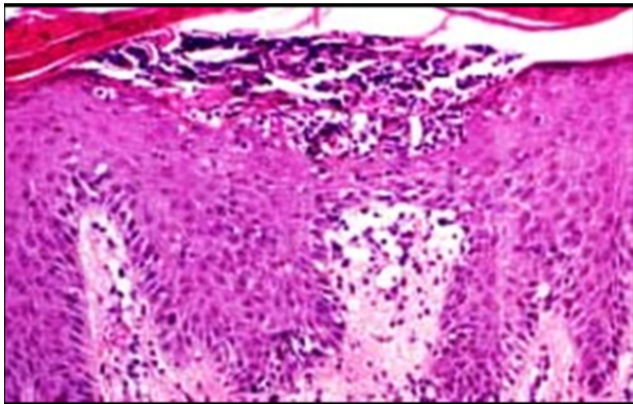
**Fig. 1:** Clinical picture of lichen planus showing well defined hyperpigmented plaques with violaceous halo.

### 4. Discussion

In the present study Lichen Planus (64.6 %) was the most common lesion followed by Psoriasis (24.6 %), Pityriasis Rosea (6.2%), and Pityriasis Rubra Pilaris (3.1 %). One case of Lichen Nitidus was noted in the present study. Parapsoriasis and Lichen striatus were not noted in the present study. Other studies show Lichen Planus as significantly more common than other Papulo - squamous lesions.<sup>4-8</sup> In our study most common age group for lichen planus was 31-40 years which was comparable with the study done by D'Costa and Bharambe. In the present study 22 cases (34 %) were clinically diagnosed correctly, 38 cases (58%) were differentially diagnosed and 5 cases (8 %) had different clinical diagnosis. Clinical, differential and histopathological diagnosis was same in 92 % of cases and different in 8% of cases which was comparable with the study done by D'costa & Bharambe (2010).



**Fig. 2:** HYPERTROPHIC LICHEN PLANUS – showing hyperkeratosis, hypergranulosis and papillomatosis with band like Lymphocytic infiltrate in dermo-epidermal junction (H&E stain: 400x).



**Fig. 3:** PSORIASIS VULGARIS-Munro microabscess in parakeratotic layer (H&E stain:400x).

In the present study 6(37.5%) cases were diagnosed clinically as psoriasis without any differential diagnosis and in 9(56.25%) cases psoriasis was among the differential diagnosis.

## 5. Conclusion

Separation of each entity is important because the treatment and prognosis for each tends to be disease specific. Most

of these cases have characteristic Histopathological features that confirm the diagnosis.

However nonspecific and overlapping of Histopathological features are not so uncommon. In those cases clinical correlation is very important to make final diagnosis. Hence a combination of proper clinical observation, history and histopathological study will give a conclusive diagnosis.

## 6. Source of Funding

None.

## 7. Conflict of Interest

None.

## References

1. Hosamane S. Clinicopathological Study of Non-Infectious Erythematous Papulosquamous Skin Diseases. *J Clin Diagn Res.* 2016;10(6):EC19.
2. Elder ED, Elenitsas R, Johnson LB, and FGM. Introduction to dermatopathologic diagnosis in Lever's Histopathology of the Skin; 2005.
3. Costa GD, Bharambe B. Spectrum of non-infectious erythematous, papular and squamous lesions of the skin. *Indian J Dermatol.* 2010;55(3):225.
4. Weston G, Payette M. Update on lichen planus and its clinical variants. *Int J Women's Dermatol.* 2015;1:140–9.
5. Gorouhi F, Davari P, Fazel N. Cutaneous and Mucosal Lichen Planus: A Comprehensive Review of Clinical Subtypes, Risk Factors, Diagnosis, and Prognosis. *Scientific World J.* 2014;2014.
6. Capella GL, Finzi AF. Psoriasis and other papulosquamous diseases in infants and children. *Clin Dermatol.* 2000;18(6):701–9.
7. Cotton CH, Tom WL. Psoriasis and Other Papulosquamous Skin Disorders. In: *Therapy in Pediatric Dermatology.* Cham: Springer; 2017. p. 33–50.
8. Di M, Wan DF, Xu SQ, Lu Y, Shen JM, Zhu WY, et al. Papulosquamous diseases. In: *Atlas of Skin Disorders.* Springer; 2018. p. 105–126.

## Author biography

**V. L. Kusuma Chandrika** Consultant Pathologist

**Krishna Tadepalli** Associate Professor

**Cite this article:** Chandrika VLK, Tadepalli K. A clinicopathological study of non-infectious papulo - squamous lesions of skin. *IP J Diagn Pathol Oncol* 2020;5(2):141-143.