



Case Report

Unusual histological presentation of a residual cyst: A case report

Sanpreet Singh Sachdev^{1,*}, Amol Dubey², Parmeet Singh Banga³, Akshat Shetty⁴

¹Dept. of Oral Pathology, Government Dental College and Hospital, Mumbai, Maharashtra, India

²Dept. of Oral Surgery, YMT Dental College & Hospital, Mumbai, Maharashtra, India

³Dept. of Prothodontics, YMT Dental College and Hospital, Mumbai, Maharashtra, India

⁴Naseem al Rabeeh Medical Center, Doha, Qatar



ARTICLE INFO

Article history:

Received 20-04-2021

Accepted 30-04-2021

Available online 29-05-2021

Keywords:

Inflammatory cyst

Prosoplasia

Metaplasia

ABSTRACT

Cystic lesions of jaws are fairly common of which radicular cysts that form as a result of inflammatory changes associated with a non-vital pulp are most frequent. The removal of source of infection by either root canal treatment or extraction of the involved tooth leads to resolution of inflammatory cysts. However, infrequently, certain lesions may persist even after appropriate treatment which are termed as 'residual cysts'. Although residual cysts are histopathologically indistinguishable from radicular cysts, certain changes may occur owing to removal of the aggravating stimulus which may lead to a varied histopathological picture. The present case report comprises of a residual cyst with a relatively unusual histopathological presentation.

© This is an open access article distributed under the terms of the Creative Commons Attribution License (<https://creativecommons.org/licenses/by/4.0/>) which permits unrestricted use, distribution, and reproduction in any medium, provided the original author and source are credited.

1. Introduction

Various types of cysts develop in the jaws having either developmental or inflammatory cause that present themselves as a clinical problem for dental surgeons. Over the past years, researchers have answered questions pertaining to the etiology, pathogenesis, clinical behavior, diagnosis and treatment of the various types of cyst. Despite ample standardized descriptions and classification, unusual histopathological presentation renders certain cases as unclassifiable.¹

About half of the cases of cysts of the jaws comprise of inflammatory cysts, particularly, radicular cysts.² These form as a result of endotoxins released from an infected pulp canal followed by stimulation of epithelial rests in the periapical periodontal region of a tooth.³ Performing root canal treatment or extraction of the involved tooth is deemed as an appropriate treatment for such cases. However, at times, a cyst may persist even after removal of the source

of infection or the offending tooth itself. Such retained cysts are termed as 'residual cysts' (RCs) that are relatively infrequent comprising of approximately 10% of all the odontogenic cysts.⁴

What is most perplexing is that the epithelial lining of inflammatory cysts can assume a myriad of differentiation end-points which result in corresponding variable histopathological picture. We report once such case of residual cyst displaying an unusual histopathological appearance.

2. Case Report

A 25-year-old female reported with an asymptomatic swelling in the posterior left mandibular region which had gradually increased in size over the past two months. Past dental history of the patient revealed that the mandibular left second and third molars were extracted seven months before. The patient did not have any significant past medical history. No gross deformity or facial asymmetry could be noted extra-orally.

* Corresponding author.

E-mail address: Sunpreetss@yahoo.in (S. S. Sachdev).

Intraoral examination revealed expansion of buccal and lingual cortical plates from distal of mandibular left first molar up to the retromolar region. Cone Beam Computed Tomography revealed a well-defined corticated saucer-shaped concavity involving the lingual cortical plate in mandibular third molar region [Figure 1]. Healing socket was appreciated in place of the extracted second molar. Mild to moderate periodontal bone loss could be noted involving the mandibular left second premolar and first molar teeth. The inferior alveolar nerve canal was traceable and unaffected.

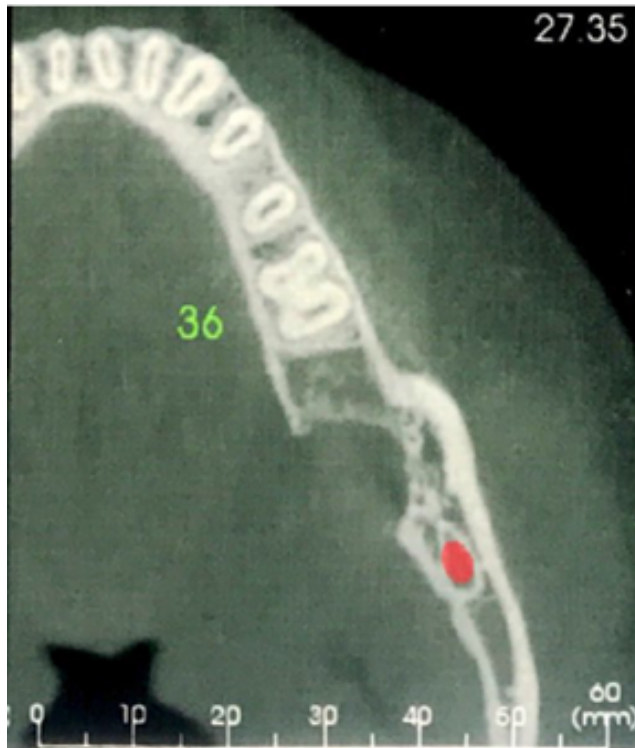


Fig. 1: Cone beam computed tomography scan exhibiting saucer-shaped defect of lingual cortical plate in mandibular left third molar region

The lesion was enucleated under local anesthesia using inferior alveolar nerve block technique followed by curettage. On gross examination, two bits of excised tissue, the largest measuring 1.5 x 1 cm were noted. The bits had irregular shape and surface texture, soft to slightly firm consistency and brownish color.

Microscopically, cystic lumen was lined by pseudostratified columnar epithelium overlying the cystic wall [Figure 2]. The underlying connective tissue capsule comprised of parallel arrangement dense bundles of collagen fibers interspersed with fibroblasts devoid of an inflammatory infiltrate. Certain areas of the lesion consisted of loose and edematous capsule towards the lumen along with foci of dense chronic inflammatory cell infiltrate chiefly comprising of lymphocytes and

plasma cells. Several congested endothelial lined vascular spaces were noted along with areas of extravasation of the vascular elements. Under high power, the lining cells exhibited pseudostratification with intracellular vacuolation. Correlating the clinicoradiohistopathological features with history of extracted teeth a final diagnosis of Residual cyst was imparted.

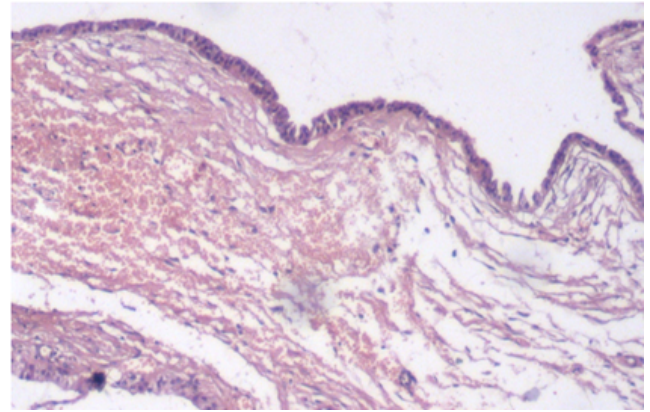


Fig. 2: H and E-stained section under 10x magnification shows pseudo stratified ciliated columnar epithelium with a collagen cystic wall devoid of inflammatory changes lining the lumen.

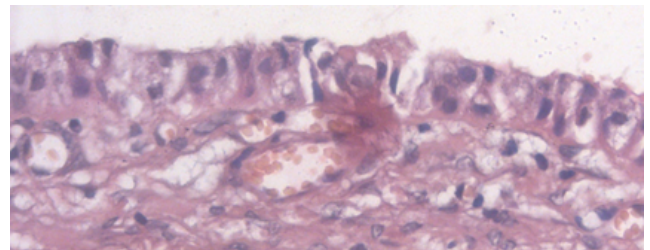


Fig. 3: H and E-stained section under 40x magnification shows ciliated columnar epithelial cells exhibiting pseudo stratification and intracellular vacuolization.

3. Discussion

When considering nature of periapical cysts, two types of cysts have been described.³ Firstly, a periapical pocket cyst or 'bay cyst' communicates directly with the infected root canal and is attached only to the margins of apical foramen by means of epithelium. The second type represents 'true' radicular cyst which comprises of a true cystic lumen lined by epithelium throughout its perimeter. The former can be expected to resolve following removal of the source of infection. The latter can be designated as 'self-sustaining' and may therefore, persist even after removal of the cause and these may account for the relatively low frequency of residual cysts.⁵

The present case exhibited a RC that had persisted and gradually increased in size following extraction of the

involved mandibular molars over a course of seven months. In contrast to infected or rapidly enlarging residual cysts, the gradually expanding lesions are generally asymptomatic and present as well-defined radiolucencies surrounded by a narrow radiopaque margin as noted in the present case.⁶ Although these represent well-contained nature of the cysts due to responses by the body tissues, the differential diagnosis of odontogenic keratocyst must be considered which also present in an identical manner.

The histopathological features of a RC are undoubtedly similar to a conventional radicular cyst. However, removal of the aggravating factor causes the cyst wall to become progressively less inflamed and at the same time, the epithelial lining tends to become thin and consistent closely resembling that of a dentigerous cyst or a lateral periodontal cyst.⁷ Thus, these differentials must be kept in mind while examining a cystic lesion and should be subsequently correlated with clinical history to rule out a developmental cyst. The regressive histopathological changes noted within a lining of residual cyst are indicative of the fact that a vast majority of RCs are slowly resolving lesions. The resolving nature of RCs closely follows removal of inflammatory stimulus which is further reinforced by cessation of epithelial proliferation and its ability to differentiate up to some extent.⁷

Additionally, the differentiation of lining epithelium is accompanied by certain metaplastic changes amongst which mucous metaplasia occurs most frequently. Ciliated cells with vacuolization have also been reported in the cystic lining which are suggested to represent an intermediate stage in the process of mucous metaplasia or as a result of involvement of lining of maxillary antrum.⁸ However, interestingly, pseudostratified ciliated epithelium has also been observed in the lining of radicular and RCs of mandible.⁹ This peculiar finding represents the potential of the lining epithelium to undergo 'prosoplasia', consequently resulting in development of pseudostratified ciliated columnar epithelium even in mandibular cystic lesions as noted in the present case.¹⁰

Thus, a pathologist must be wary of various unusual ways in which a simple inflammatory cyst may present with. The prosoplasia of lining epithelium is indicative of resolution of the inflammatory changes in the cystic wall and consequently, less aggressive nature of the lesion. Surgical enucleation with curettage was deemed as appropriate treatment for the present case, being that of a resolving cystic lesion.

4. Conclusion

Metaplastic changes in the lining of a residual cyst may add confusion to the already existing one in case if the association of lesion with the tooth is lacking. The lesion may be confused with other developmental cysts such as

dentigerous cyst or odontogenic keratocyst and therefore, warrants meticulous examination of patient and elicitation of relevant history. Familiarity with possible unusual ways of presentation of cystic lining will help a pathologist in diagnosing the lesion appropriately and subsequently guiding the surgeon with respect to the treatment plan.

5. Source of Funding

No financial support was received for the work within this manuscript.

6. Conflict of Interest

The authors declare that they have no conflict of interest.

References

1. Jones AV, Craig GT, Franklin CD. Range and demographics of odontogenic cysts diagnosed in a UK population over a 30-year period. *J Oral Pathol Med.* 2006;35(8):500–7.
2. Tamiolakis P, Thermos G, Tosios KI, Sklavounou-Andrikopoulou A. Demographic and clinical characteristics of 5294 jaw cysts: a retrospective study of 38 years. *Head Neck Pathol.* 2019;13(4):587–96.
3. Nainani P, Sidhu GK. Radicular cyst-an update with emphasis on Pathogenesis. *J Adv Med Dent Sci Res.* 2014;2(3):97–101.
4. Titinchi F, Morkel J. Residual cyst of the jaws: A clinico-pathologic study of this seemingly inconspicuous lesion. *PLoS ONE.* 2020;15(12):244250.
5. Nair PNR, Pajarola G, Schroeder HE. Types and incidence of human periapical lesions obtained with extracted teeth. *Oral Surgery, Oral Medicine, Oral Pathology, Oral Radiol, Endod.* 1996;81:93–102.
6. High AS, Hirschmann PN. Symptomatic residual radicular cysts. *J Oral Pathol.* 1988;17:70–2.
7. High AS, Hirschmann PN. Age changes in residual radicular cysts. *J Oral Pathol.* 1986;15:524–8.
8. Slabbert H, Shear M, Altini M. Vacuolated cells and mucous metaplasia in the epithelial linings of radicular and residual cysts. *J Oral Pathol Med.* 1995;24(7):309–12.
9. Takeda Y, Oikawa Y, Furuya I, Satoh M, Yamamoto H. Mucous and ciliated cell metaplasia in epithelial linings of odontogenic inflammatory and developmental cysts. *J Oral Sci.* 2005;47(2):77–81.
10. Sarode GS, Maniyar N, Sarode SC, Rao R, Patil S. Mucous cell prosoplasia in oral pathologies: a brief review. *J Clin Diagn Res: JCDR.* 2017;11:ZE8.

Author biography

Sanpreet Singh Sachdev, Post Graduate

Amol Dubey, Oral Surgeon

Parmeet Singh Banga, Reader

Akshat Shetty, General Dentist

Cite this article: Sachdev SS, Dubey A, Banga PS, Shetty A. Unusual histological presentation of a residual cyst: A case report. *IP Arch Cytol Histopathology Res* 2021;6(2):117-119.