



## Original Research Article

## A study of FNAC of head and neck region at a tertiary level hospital

Jyoti P Sapre<sup>1,\*</sup>, Kirti N Vyas<sup>1</sup>, Alpeshkumar M Maru<sup>1</sup><sup>1</sup>Dept. of Pathology, Dr. N D Desai Medical College, Nadiad, Gujarat, India

## ARTICLE INFO

## Article history:

Received 03-05-2021

Accepted 12-05-2021

Available online 29-05-2021

## Keywords:

Fine needle aspiration cytology

Head and Neck

Inexpensive

Simple

## ABSTRACT

**Introduction:** Swellings in the Head and Neck region are very common and are evaluated with the help of a detailed clinical history, physical examination and investigations like FNAC, USG, CT scan or excisional biopsy. Fine Needle Aspiration Cytology (FNAC) is a simple, quick, inexpensive and minimally invasive OPD procedure used in the diagnosis of different swellings of Lymph nodes, thyroid, salivary gland and soft tissues in the Head and Neck region.

**Aim:** We did this study with the purpose of identifying the frequency and distribution of different pathologies found in FNAC done in patients presenting with a swelling in the Head and Neck region as per the site, age, sex and type of the lesion.

**Materials and Methods:** A retrospective study was conducted on the patients presenting with swelling in the Head and Neck region at the Pathology department of a tertiary care hospital between the duration of 1<sup>st</sup> August 2019 to 30<sup>th</sup> April 2021. FNAC was performed on total 260 patients.

**Results:** Out of 260 cases, 157 cases (60.4%) were from Lymph nodes, 50 cases (19.2%) from thyroid gland, 27 cases (10.3%) from skin and subcutaneous tissue, 23 cases (8.84%) from salivary gland and 3 cases (1.1%) were inconclusive due to inadequate material aspiration. 149 cases (57.98%) were inflammatory, 70 cases (27.24%) benign and 38 cases (14.78%) were found to be malignant.

**Conclusion:** FNAC is a simple, quick, inexpensive, minimally invasive OPD procedure and used as first line of investigation in the diagnosis of swellings in the Head and Neck region.

© This is an open access article distributed under the terms of the Creative Commons Attribution License (<https://creativecommons.org/licenses/by/4.0/>) which permits unrestricted use, distribution, and reproduction in any medium, provided the original author and source are credited.

## 1. Introduction

The method of obtaining cells or tissue from abnormal lesions located at superficial locations with the help of a needle is known as Fine Needle Aspiration Cytology (FNAC) and it is being used since a very long time to aid in diagnosis.<sup>1</sup> In deep seated lesions FNAC can be done with radiological guidance as in USG/CT/MRI guided FNACs. This method was used by many pathologists as well as clinicians as it is a quick and easy process with the procedure done on OPD basis and can give a reliable diagnosis within a short time. FNAC technique began to flourish in the Europe in 1950 and 1960 and soon it was accepted and integrated in the diagnostic work up of a

patient throughout the world. FNAC is now part of the service of all sophisticated departments of pathology.<sup>1</sup>

FNAC was initially conceived as a means to confirm a clinical suspicion of local recurrence or metastasis of known cancer without subjecting the patient to further surgical intervention. This remains one of the most important contributions of the technique from a practical point of view. Following success in this area, the interest focused on preliminary preoperative diagnosis of all kinds of neoplastic processes, benign or malignant, in any organ or tissue of the body and on definitive, specific diagnosis in inoperable cases as a guide to rational treatment. The expansion of FNAC in primary diagnosis of tumours in the last 30 years or so has been impressive and generally successful. This development is to a large degree the result of consistent, continuous and critical correlation between cytological

\* Corresponding author.

E-mail address: [jyotisapre@gmail.com](mailto:jyotisapre@gmail.com) (J. P. Sapre).

assessment and histopathological diagnosis facilitated by the organisational coordination of laboratory resources.<sup>1,2</sup> The utility of FNAC is not limited to only malignant lesions but it is equally useful in the diagnosis of inflammatory, infectious and degenerative conditions. Also, it is used as a diagnostic and monitoring tool of graft rejection in transplant recipients. Intraoperative cytology is another application where it complements the process of Frozen section with comparable level of accuracy.<sup>3,4</sup>

A wide variety of swellings are seen in the Head and Neck region ranging from infective, inflammatory, cystic to neoplastic in nature. The location of the swellings in this region near to important tissues and vessels makes this a very sensitive site making incisional biopsy in this region problematic. FNAC, being a quick, accurate and easy inexpensive procedure is the first choice in this region and also is quite reliable in diagnosing non neoplastic lesions or confirming suspected metastatic or recurrent lesions hence can obviate the need of surgery. It can be both diagnostic as well as therapeutic in cystic lesions, it can differentiate between benign and malignant lesions of salivary glands with 90% accuracy. Having said the above things it has to be noted that FNAC is a complementary process to Histopathological diagnosis and should not be done solely but as a part of the diagnostic work up along with histopathological biopsy.<sup>1,3</sup>

## 2. Materials and Method

The study was carried out on patients coming to the cytology section of Pathology department at a tertiary level hospital between the period of 1<sup>st</sup> August 2019 to 30<sup>th</sup> April 2021. The patients presented with a swelling in the Head and Neck region to the OPD section of the hospital and were referred by the clinicians from departments like surgery, ENT, paediatrics and medicine. Detailed clinical history of the patient was taken and physical examination of the swelling was done with details about size, appearance, consistency, mobility and skin over the swelling being noted. The findings of any investigation like USG, CT scan, MRI and any haematological/biochemical/serological tests if done were noted down. The FNAC procedure was explained to the patient and consent taken. FNAC was performed with aseptic precautions without local anaesthetic agent. We used 10 ml syringe and needles with gauge 22 – 27 depending on the location of the swelling. The needle was inserted in the swelling at a convenient angle and multiple hits made with enough negative pressure. The needle was removed after releasing the negative pressure and then pressure was applied to the site of aspiration with the help of cotton to avoid bleeding or hematoma formation. The material obtained was immediately fixed in methanol for routine haematoxylin and eosin stain, few slides stained with Pap stain and few smears were air dried for Giemsa stain.

## 3. Results

The study included 260 patients ranging from the age of 9 months to the age of 90 years. There were 159(61.15%) females and 101(38.85%) males. Majority of the lesions were located in the neck region and lymph node involvement was the commonest amongst all accounting for 157 cases (60.4%) of which 67(42.67%) cases were males and 90(57.33%) cases were females (Table 1). Among the lymph node lesions, chronic granulomatous lymphadenitis was the commonest constituting 80 cases (Figure 1), followed by reactive lymphadenitis 39 cases, metastatic lymph nodes 26 cases, chronic non - specific lymphadenitis 7 cases and 5 cases of lymphoproliferative disorders (Chart 1).

Thyroid was the second most commonly involved site accounting for total of 50 cases (19.23%) of which 8 cases (16%) were males and 42 cases (84%) were females. Colloid goitre is the commonest thyroid lesion with 18 cases (Figure 2), followed by 14 cases of thyroiditis, 11 cases of cystic lesions, 6 cases of follicular neoplasms and 1 case of malignant lesion of the thyroid (Chart 2).

There were total 27 cases of skin and subcutaneous tissue of which 14 cases (51.85%) were males and 13 cases (48.15%) were females. 10 cases were of epidermal cysts followed by 4 cases of lipoma, 6 cases of benign inflammatory lesions, 6 cases of cystic lesions and a single case of malignant lesion (Chart 3).

There were total 23 cases of salivary gland lesion of which 12 cases (52.17%) were males and 11 cases (47.83%) were females. 14 cases were of pleomorphic adenoma (Figure 3) followed by 5 cases of sialadenitis, 3 cases of cystic lesions and 1 case of malignant lesion (Chart 4).

Total of 3 cases were inconclusive due to very small lesion with inadequate material.

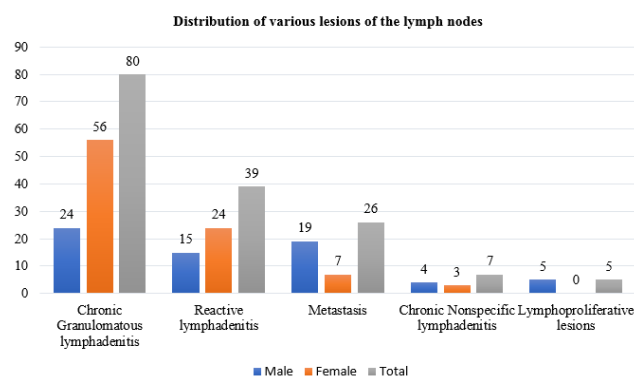


Chart 1: Distribution of various lesions of the lymph node

## 4. Discussion

In our study of 260 cases of different swellings in the Head and Neck region, lymph node lesions (157 cases)

**Table 1:** Distribution of lesions according the site involved and gender

Lesions	Male	Female	Total	Percentage %
Lymph nodes	67	90	157	60.38%
Thyroid	08	42	50	19.23%
Skin and Subcutaneous tissue	14	13	27	10.38%
Salivary Glands	12	11	23	8.84%
Inconclusive	00	03	03	1.15%
Total	101	159	260	100%

**Table 2:** Distribution of various Head and Neck lesions according to Age

Age	No. of cases	Percentage of cases
0-10	21	8.07%
11-20	39	15.0%
21-30	55	21.15%
31-40	35	13.46%
41-50	60	23.07%
51-60	30	11.53%
61-70	14	5.38%
71-80	05	1.92%
81-90	01	0.38%
Total	260	100%

**Table 3:** Distribution of Head and Neck lesions between our study and other studies

	Lymph node %	Thyroid gland %	Salivary gland %	Skin and Subcutaneous tissue %
Our study	60.38	19.23	8.84	10.38
Shobha <sup>5</sup>	86	-	12	02
Shekhar <sup>6</sup>	42	18	15.5	17.5
Shreedevi <sup>7</sup>	50.32	44.07	3.28	2.3
S. Khetrapal <sup>8</sup>	64.1	16.9	4.1	13.8
SanghviAKB <sup>9</sup>	41	37	5	7
Patel D <sup>10</sup>	64	22.8	4.8	2
Kapoor S <sup>11</sup>	43	34	15	8

**Table 4:** Distribution of cases according the type of lesions in our study

Type of Lesions	Male	Female	Total
Inflammatory	49	100	149
Benign	25	45	70
Malignancy	27	11	38
Total	101	156	257

(Here total number of cases is taken as 257 as 3 FNACs were inconclusive)

were the commonest of all with chronic granulomatous inflammation (80 cases) being the most common. Thyroid gland lesions (50 cases) were the second commonest followed by lesions of the skin and subcutaneous tissue (27 cases) and Salivary gland lesions (23 cases). We compared our results with various studies undertaken nationally as well as internationally (Table 3).

A study carried by El Hag et al<sup>12</sup> in Saudi Arabia in 2003 included 225 patients over a period of 5 years. 70% of lesions were in the lymph nodes showing reactive lymphadenitis as the commonest cause constituting 33% cases followed by chronic granulomatous lesion accounting

for 21% cases and malignant lesions in 13% cases which is comparable with our study.<sup>13,14</sup>

A study done by Shreedevi et al<sup>7</sup> at Andhra Pradesh in 2016 is also similar to our study where 50% cases out of total 304 cases were lesions from the lymph nodes followed by lesions in the Thyroid gland. Reactive lymphadenitis is the commonest lesion seen in lymph nodes, colloid goitre in thyroid gland and pleomorphic adenoma in the salivary gland.<sup>15-17</sup> The commonest lesions seen in the soft tissues were epidermal cysts and lipoma.

Other studies conducted by Shobha et al,<sup>5</sup> Shekhar et al<sup>6</sup> and SanghviAKB et al<sup>9</sup> had maximum lesions from the

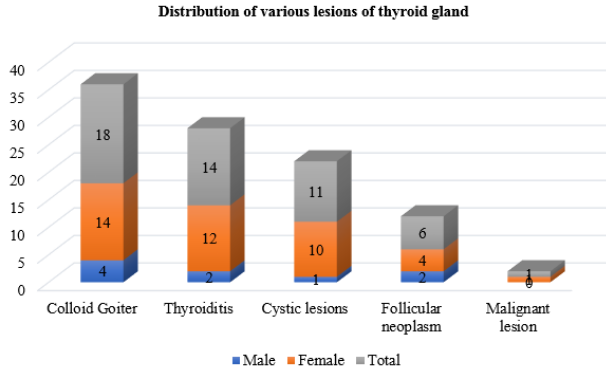


Chart 2: Distribution of various lesions of Thyroid Gland

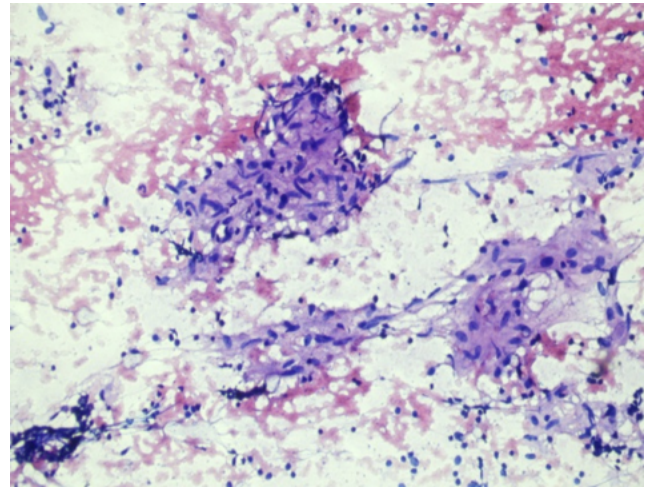


Fig. 1: H & E 10X FNAC findings of Chronic Granulomatous Lymphadenitis

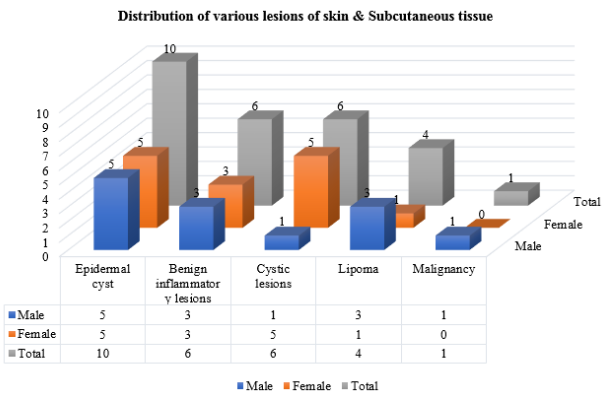


Chart 3: Distribution of various lesions of skin & Subcutaneous tissue

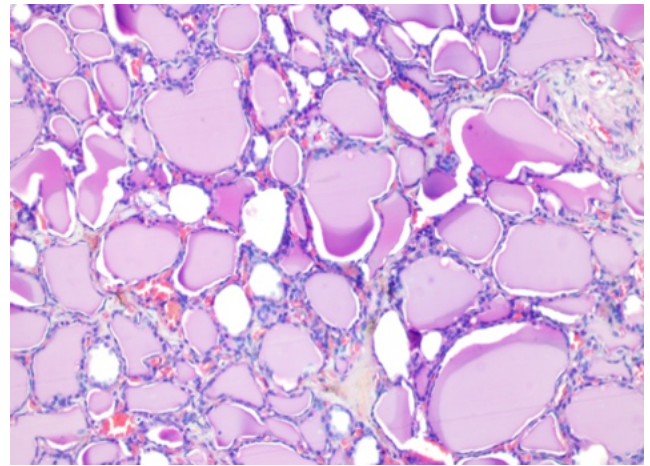


Fig. 2: H & E 10X FNAC findings of Colloid Goitre

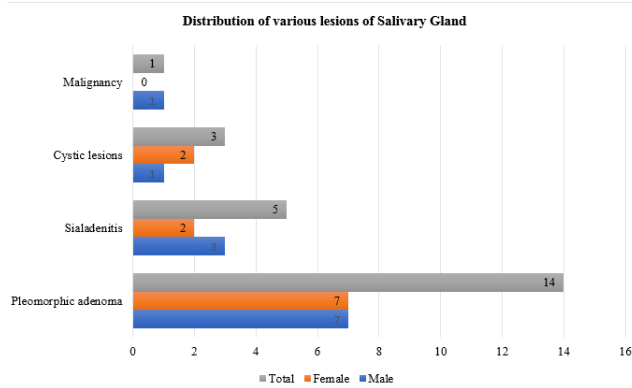


Chart 4: Distribution of various lesions of salivary gland

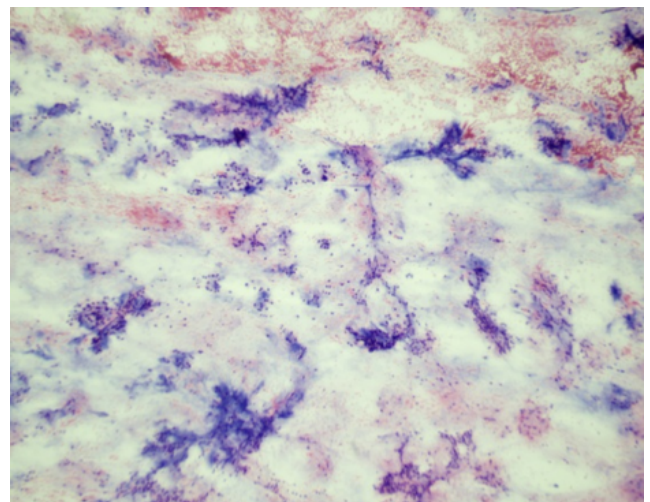


Fig. 3: H & E 10X FNAC findings of Pleomorphic Adenoma

lymph nodes which is comparable with our study.

Studies done by SangaviAKB et al<sup>9</sup> and S. Khetrpal et al<sup>8</sup> had maximum inflammatory lesions which is similar to our study (Table 4).

The studies conducted by SangaviAKB et al<sup>9,18</sup> and Kapoor S et al<sup>11,15</sup> showed lesions more in females as compared to the males which is similar to our study. In our study of thyroid gland lesions the Female to Male ratio is 5.25:1 which is comparable with study undertaken by Patel D et al.<sup>10,19–21</sup>

## 5. Conclusion

FNAC is a simple, quick, inexpensive, minimally invasive OPD procedure. It is the first line of investigation in the diagnosis of swellings in the Head and Neck region. It is highly accurate and reliable and acts as a complementary process to Histopathological diagnosis. In many lesions the need for biopsy can be avoided and a fairly accurate diagnosis can be obtained with the help of FNAC.

The distribution and nature of various lesions in the Head and Neck region was studied by us and following conclusions were derived:

1. Majority of the lesions are inflammatory in nature and are seen more in the female population
2. Lymph nodes were the commonest involved and chronic granulomatous inflammation being the most common lesion
3. Colloid goitre in thyroid lesions and Pleomorphic adenoma in the salivary gland lesions were the commonly seen lesions
4. Metastatic carcinoma was commonly seen in the malignant lesions of the lymph nodes.

Fine Needle Aspiration Cytology plays a significant role in the diagnosis of swelling in the Head and Neck region. It reduces unnecessary burden, expenditure, psychological trauma and hospitalisation in these patients and it should be used as a first line investigation wherever feasible and as a complementary procedure along with biopsies wherever applicable.

## 6. Source of Funding

No financial support was received for the work within this manuscript.

## 7. Conflict of Interest

The authors declare they have no conflict of interest.

## References

1. Orell S, Sterrett G. Orell and Sterrett's Fine Needle Aspiration Cytology. In: 5th edn. Churchill Livingstone; 2011.
2. Anne R, Sadhana D, Sabina A. FNAC in the diagnosis of Lymph node malignancies: A simple and sensitive tool. *Indian J Med Paediatr Oncol.* 2012;33(1):21–4. doi:10.4103/0971-5851.96964.
3. Watkinson JC, Wilson JA, Gaze M, Stell PM, Maran AGD. Stell and Maran's Head and Neck surgery. In: Butterworth-Heinemann. 4th Edn. Butterworth-Heinemann, Oxford; 2000. p. 20–1.
4. Layfield LJ. Fine needle aspiration of the head and neck. *Pathol - Phila.* 1996;4(2):409–38.
5. Shobha SN, Rajashekar YR. Role of Fine needle aspiration cytology in head and neck lesions Indian. *J Pathol Oncol.* 2017;4(3):408–12.
6. Shekhar H, Kaur A, Agrawal P, Pancharia A, Jadeja P. Fine needle aspiration cytology in head and neck swellings: a diagnostic and therapeutic procedure. *Int J Res Med Sci.* 2014;2(4):1667–71.
7. Sreedevi P, Kumar K, Parankusa N. Diagnostic Role of FNAC in evaluation of Head and Neck lesions. *J Med Dent Sci.* 2016;15(9):11–3.
8. Khetrpal S, Jetley S, Jairapuri Z, Rana S, Kohli S. FNAC of head and neck regions and its utility in clinical diagnosis: A Study of 209 cases. *Nat J Med Res.* 2015;5(1):33.
9. Sangavi AKB, Itagi IR, Choudhari SY, Venkatesh U. Evaluation of FNAC of head and neck swellings: a retrospective study. *Int J Otorhinolaryngol Head Neck Surg.* 2018;4(1):189–92.
10. Patel DN, Patel PB, Patel HV, Gandhi TJ. Fine needle aspiration cytology role in head and neck lesions. *IAIM.* 2015;2(8):99–104.
11. Kapoor S, Bagga PK, Rupesh S, Singh A, Kumar A, Singh H, et al. Diagnostic accuracy of fine needle aspiration cytology in palpable lesions of head and neck in comparison to histopathology. *Int J Contemp Med Res.* 2017;(2):449–53.
12. Hag IAE, Chiedozi LC, Reyees FAA, Kollur SM. Fine needle aspiration cytology of head and neck masses. Seven years' experience in secondary care hospital. *Acta Cytol.* 2003;47(3):387–92.
13. Shykhon M, Macnamara, El-Assy W. Role of repeat Fine needle aspiration cytology in head and neck lesions: Preliminary study. *J Laryngology Otol.* 2006;4:294–98.
14. Gupta A, Nayar M, Chandra M. Reliability and limitations of fine needle aspiration cytology of lymphadenopathies. *Acta Cytol.* 1991;35:773–83.
15. Rathore H, Jethani N, Panchori G, Bansod P, Kalpana R. Cytomorphology of Head and Neck lesions: A study in tertiary care hospital. *Panacea J Med Sci.* 2015;3:234–9.
16. Ahmad T, Naeem M, Ahmed S. Fine needle aspiration cytology (FNAC) and neck swellings in the surgical outpatient. *J Ayub Med Coll Abbottabad.* 2008;20(3):30–2.
17. Nfangul A, Vani BR, Srinivasa M. Fine needle aspiration cytology Profile of Head and Neck Lesions in a Tertiary Care Hospital. *Indian J Pathol.* 2017;6(2):372–7.
18. Rajyalakshmi R, Rajeshwari R, Satynarayana R, Vijaya Bhaskar R. Fine needle aspiration of Head and Neck tumours (excluding Thyroid lesions) in correlation with Histopathology and Immunohistochemistry- a retrospective study. *J Med Dent Sci.* 2016;15:26–32.
19. Vaishnani HV, Vekaria PN, Patil D, Shah Y, Sanjini N. Retrospective study of fine needle aspiration cytology of head and neck lesions in tertiary care hospital. *Int J Biomed Adv Res.* 2013;4:253–8.
20. Pathak R, KBRPrasad, Rauniyar SK, Pudasaini S, Pande K, Koirala S, et al. Fine needle aspiration cytology of head and neck lesions and its correlation with histopathology. *J Pathol Nepal.* 2016;6(1):985–9.
21. Srimahalakshmi, Arunalatha. Metastatic Malignancies Presenting as Nodal Enlargement. 2015;2:19–22.

## Author biography

**Jyoti P Sapre**, Associate Professor

**Kirti N Vyas**, Associate Professor

**Alpeshkumar M Maru**, Associate Professor

**Cite this article:** Sapre JP, Vyas KN, Maru AM. A study of FNAC of head and neck region at a tertiary level hospital. *IP Arch Cytol Histopathology Res* 2021;6(2):91-96.