



Case Report

Gastrointestinal basidiobolomycosis in children mimicking as abdominal malignancy: A rare case report

Ram Nawal Rao^{1,*}, Vikrant Verma¹, Varnika Rai¹, Anshima Singh¹

¹Dept. of Pathology, Sanjay Gandhi Postgraduate Institute of Medical Sciences, Lucknow, Uttar Pradesh, India



ARTICLE INFO

Article history:

Received 18-09-2020

Accepted 26-09-2020

Available online 20-10-2020

Keywords:

Basidiobolomycosis

Gastrointestinal

Pediatrics

Malignancy

Entomophthorales

Immunocompetent

ABSTRACT

Gastrointestinal Basidiobolomycosis (GIB) is an unusual fungal disease caused by *Basidiobolus ranarum*, seen in the stomach, small intestine, colon, and liver. It has been rarely reported in the literature and most of the reported cases have been from US, Saudi Arabia, Kuwait, and Iran. *Basidiobolus ranarum* is an environmental saprophyte found worldwide. It is a member of the order Entomophthorales of the class zygomycete. The infection is generally restricted to subcutaneous tissues but the disease can also involve visceral organs. GIB usually has nonspecific clinical manifestations and its diagnosis is more challenging. Delayed diagnosis of GIB increases the risk of morbidity and mortality, especially in pediatric patient. The plan of our case report is to illustrate the wide range of clinical presentations, clinico-radiological and histopathological diagnosis, management and outcomes.

© 2020 Published by Innovative Publication. This is an open access article under the CC BY-NC license (<https://creativecommons.org/licenses/by-nc/4.0/>)

1. Introduction

GIB is a rare fungal infection that causes unusual chronic, skin infections and is increasingly being recognized as a causative agent of gastrointestinal basidiobolomycosis (GIB), especially in pediatric populations from tropical and subtropical regions. Basidiobolomycosis is almost always misdiagnosed as other chronic granulomatous diseases, malignancies or inflammatory bowel diseases.¹ GIB is rarely reported in medical literature although sporadic cases have been reported worldwide, predominantly in the United States and Saudi Arabia, with some additional cases observed in Brazil and Iran.² The first presumed case of Gastrointestinal Basidio-bolomycosis (GIB) was reported in 1964 in a six years old Nigerian boy. Subsequently, two cases were reported in 1979 involving the gastrointestinal tract in apparently healthy individuals.³ Diagnosis of GIB is difficult as its occurrence in immunocompetent host is a cofounder. In addition, the nonspecific clinical presentations, such as fever, abdominal pain, or abdominal

mass, could mimic infectious gastrointestinal tract disease or tumors.

2. Case Report

A 3yr old boy presented with moderate to high grade fever since 15 days (102 F to 103 F). No history of cough, ear discharge, headache, vomiting, loose stools or burning micturition. There were pain abdomen–10 days (intermittent pain abdomen), history of constipation, passage of hard stools and sometimes blood streaked. Abdominal distension 3-4 day (left side of abdomen) was noticed. No history of pallor, icterus, cyanosis, clubbing, lymphadenopathy and oedma are seen. Liver is palpable 3 cm BCM. Routine blood investigation showed increased TLC-21.3x1000/ul, DLC showed eosinophilia(18%), HB-8.4gm/dl, and PLT-639x1000/cmm.

2.1. Radiological Findings

USG showed a mass in the abdomen, a suspicion of intussusception was raised. Computerised tomography(CT)

* Corresponding author.

E-mail address: mrnao@sgpgi.ac.in (R. N. Rao).

of the abdomen showed irregular heterogeneous enhancing mass approximately 5.5x5.5x3.5cm, adjacent bowel loops. Similar thickening is also noted involving the ileal loop in the right iliac fossa with maximum thickness of 10.5mm.

2.2. Colonoscopy

Child also underwent colonoscopy that showed a large ulcerated area covering 1/3rd of the circumference of the ascending colon below which there was a proliferative growth (Biopsies Taken). Mucosa of the surrounding area showed multiple superficial ulcerations with abnormal vascularity.

2.3. USG Guided FNA Cytology

Guided FNA from Mass was done and cytospin smears from the mass are cellular and show predominantly polymorphonuclear leukocytes admixed with reactive mesothelial cells and histiocytes on a clear background (Figure 1A,B). Few sheets of benign columnar epithelial cells are also seen. Several non-septate fungal elements with broad based are seen. No atypical or malignant cells are seen. May Grunwald-Giemsa (MGG) and Periodic acid schiff (PAS) stain on the smears (Figure 1C,D) highlighted the few broad based, non-septate, fungal elements. CSM stain on the smear also showed the several broad based, non-septate, fungal elements (Figure 2 A,B).

2.4. Histopathological examination

Section shows fibrocollagenous and fibroadipose tissue infiltrated by sheets of dense inflammatory cell infiltrate comprising chiefly of eosinophils, neutrophils, histiocytes, few plasma cells and lymphocytes. There are necrotizing granulomas with histiocytic palisading along with eosinophilic microabscesses. Many scattered multinucleated giant cells are seen (Figure 2C). Several broad, non-septate, fungal elements are seen on CSM stain (Figure 2D). These are focally surrounded by granular eosinophilic material (Splendore-Hoepli phenomenon as diagnostic histological criteria). Abdominal lump biopsy also showed Fungal inflammation (The morphological features of the fungus is suggestive of Mucor species possibility of Gastrointestinal Basidiobolomycosis was considered). Fungal culture study displayed tissue examined in 10% KOH showed broad, hyaline, infrequently septate mycelia. Growth on Sabouraud dextrose agar (SDA) was creamy, waxy and glabrous colonies with radial folds. LPCP from culture showed infrequently septate hyphae, and numerous globose zygosporangia with conjugation beaks characteristic of *Basidiobolus ranarum* (Entomophthoromycosis).

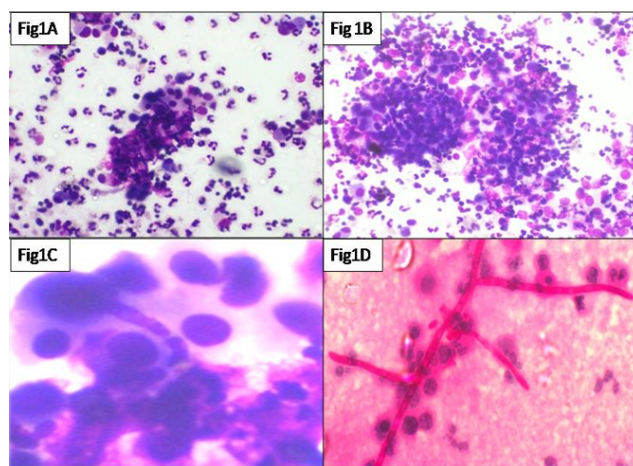


Fig. 1: A & B: Cytospin smears showed predominantly polymorphonuclear leucocytes admixed with reactive mesothelial cells and histiocytes on a clear background (MGG, 40x magnification). **C&D** Smears showed several broad based, non-septate, fungal elements (MGG and PAS, 40 magnification).

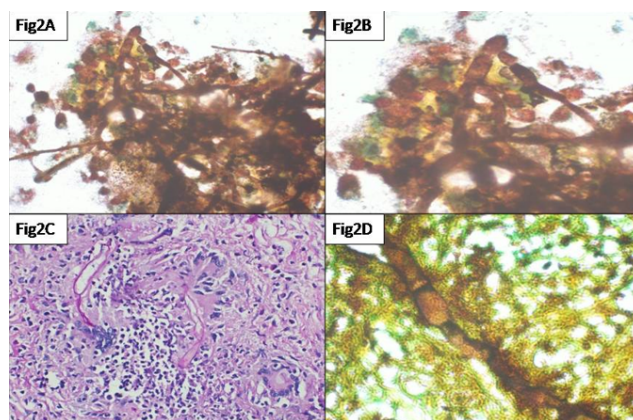


Fig. 2: A & B: Cytospin smear showed several broad based, non-septate, fungal elements (CSM, 20 & 40x magnification). **C.** Section showed several broad based, non-septate, fungal elements and focally surrounded by granular eosinophilic material known as Splendore-Hoepli phenomenon (h & e, 40x magnification). **D:** Section showed several broad based, non-septate, fungal elements (CSM, 40 magnification).

3. Discussion

Basidiobolomycosis is a rare fungal infection and it was previously included in the Zygomycete class. Of all the pediatric GIB cases reported, almost 70% are from Saudi Arabia.⁴ Saudi Arabia also has the second highest overall reported GIB patient pool.⁵ However, basidiobolomycosis is almost always misdiagnosed as other chronic granulomatous diseases, malignancies or inflammatory bowel diseases.¹

The most common presenting symptom is abdominal pain, followed by fever, weight loss, or abdominal mass.

GIB has been increasingly reported in the literature, and it is an emerging disease from arid regions worldwide, in particular, the south-western Saudi Arabia.

In patients presenting with peripheral eosinophilia, fever and abdominal pain with presence of intestinal thickening or mass on imaging, the common differential diagnosis comprises of tuberculosis, malignancy, lymphoma, Crohn's disease and diverticulitis.⁶ GIB usually has nonspecific clinical manifestations and its diagnosis is challenging. Missed and delayed diagnosis of GIB increases the risk of morbidity and mortality, especially in pediatric patient. Histopathologic examination showed a necrotizing, granulomatous process, with a prominent Splendore-Hoeppli reaction surrounding spores and aseptate hyphae. It is usually a subcutaneous infection that affects mostly young, male persons, and it is transmitted through traumatic inoculation. Confirm diagnosis of GIB requires culture or demonstration of aseptate hyphae with surrounding eosinophilic projections (Splendore-Hoeppli phenomenon) on histopathological examination. This should be differentiated from mucormycosis which may also rarely involve the gastrointestinal tract and show aseptate hyphae without Splendore-Hoeppli phenomenon.⁶

Because of its indolent presentation, it is often misdiagnosed as IBD, tuberculosis or Malignancy. An author reported in a 7 year old Saudi girl with abdominal mass, fever and eosinophilia resembling malignancy on radiological and pathological picture fully recovered with only medical therapy in the form of oral Voriconazole.⁷ A two month old male child from the deserts of western part of Rajasthan, India presented with the complaint of abdominal swelling associated with vomiting, Computed Tomography of abdomen (day+5) showed large heterogeneously enhancing abdomino-pelvic mass predominantly in pre-sacral and right inguinal fossa (RIF) region with encasement of sigmoid colon and upper part of rectum, with resultant bowel obstruction and disseminated gastrointestinal basidiobolomycosis.⁸ Radiologically, most of the cases reported as abdominal masses in the colon, liver mass or small bowel mass. Serious complication such as intestinal perforation, abscess and hydronephrosis were reported as well.⁹ Youngest case report of GIB in a 16-month-old infant and highlighted two important points. First, the need of high index of suspicious for diagnosis of GIB and its inclusion in the differential diagnosis of any abdominal mass, fever and eosinophilia. Second, it gives additional supportive evidence that medical management with voriconazole without surgical intervention is curative.¹⁰

Most of the reported cases treated as combined treatment (surgical and medical). There are few reported cases responded to medical treatment alone without surgical intervention.^{11,12}

Treatment advised as ebulking surgery and itraconazole therapy. Patient continued Itraconazole therapy for 3 to 6

months duration. Dose of Itraconazole, or changing over to oral Voriconazole or combination therapy of Itraconazole and Voriconazole. Child showed dramatic response to IV Voriconazole in the form of being afebrile within 48 hrs of starting IV Itraconazole. Child also demonstrated normalization of blood counts (TLC and eosinophils) within a week of starting antifungal therapy. Basidiobolomycosis has a good prognosis based on the available data. Most of the mortalities are attributable to younger age groups, delays in diagnosis and initiation of appropriate antifungal therapy as well as complications of this illness. Our case highlighted the important points is of either GIB as an increasingly recognized cause of abdominal mass and eosinophilia that can mimic other diseases or it gives additional clinical experience that Itraconazole/Voriconazole without surgical intervention can be curative without relapses, thus avoiding unnecessary major surgeries.

4. Conclusion

We presented a rare case of gastrointestinal basidiobolomycosis with abdominal pain and mass as the initial presenting symptoms. Although diagnosis is confirmed by cytology, histopathology after surgical removal of the mass in the gastrointestinal tract, the antifungal treatment using itraconazole/Voriconazole showed significant improvement of the clinical symptoms. The result of this case report could assist clinicians to better manage patients with GIB with the intend of avoiding any complications associated with this rare disease. Due to non-availability of this patient was managed with voriconazole for one year. On follow-up, the child is asymptomatic and doing well

5. Source of Funding

None.

6. Conflicts of Interest

None.

References

1. Khan ZU, Khoursheed M, Makar R, Al-Waheeb S, Al-Bader I, Al-Muzaini A, et al. Basidiobolus ranarum as an Etiologic Agent of Gastrointestinal Zygomycosis. *J Clin Microbiol*. 2001;39(6):2360–3.
2. El-Shabrawi MH, Kamal NM, Kaerger K, Voigt K. Diagnosis of gastrointestinal basidiobolomycosis: a mini-review. *Mycoses*. 2014;57:138–43.
3. Chronic abdominal pain and intestinal obstruction in a 24-year-old woman. *Clin Infect Dis*. 2014;58(7):990.
4. El-Shabrawi MH, Kamal NM, Kaerger K, Voigt K. Diagnosis of gastrointestinal basidiobolomycosis: a mini-review. *Mycoses*. 2014;57:138–43.
5. Vikram HR, Smilack JD, Leighton JA, Crowell MD, Petris GD. Emergence of Gastrointestinal Basidiobolomycosis in the United States, With a Review of Worldwide Cases. *Clin Infect Dis*.

- 2012;54(12):1685–91.
6. Gupta N, Razik A, Soneja M. Staring at the stars: a case of gastrointestinal basidiobolomycosis from the Indian subcontinent. *BMJ Case Rep.* 2018;.
 7. Almoosa Z, Alsuhailani M, AlDandan S, Alshahrani D. Pediatric gastrointestinal basidiobolomycosis mimicking malignancy. *Med Mycol Case Rep.* 2017;18:31–3.
 8. Sharma A, Saxena R, Sinha A, Singh S, Yadav T. Disseminated Gastrointestinal Basidiobolomycosis (GIB) in an infant from Western India. *Med Mycol Case Rep.* 2019;26:38–41.
 9. Al-Asmi MM, Faqeeli HY, Alshahrani DA, Al-Hussainia A. A case of pediatric gastrointestinal Basidiobolomycosis mimicking Crohn's disease. A review of pediatric literature. *Saudi Med J.* 2013;34:1068–72.
 10. Al-Juaid A, Al-Rezqi A, Almansouri W. Pediatric Gastrointestinal Basidiobolomycosis: Case Report and Review of Literature. *Saudi J Med Med Sci.* 2017;5(2):167–71.
 11. Albaradi BA, Babiker AMI, Al-Qahtani HS. Successful Treatment of Gastrointestinal Basidiobolomycosis with Voriconazole without Surgical Intervention. *J Trop Pediatr.* 2014;60(6):476–9.
 12. Rose SR, Lindsley MD, Hurst SF, Paddock CD, Damodaran T, Bennett J, et al. Gastrointestinal basidiobolomycosis treated with posaconazole. *Med Mycol Case Rep.* 2013;2:11–4.

Author biography

Ram Nawal Rao Professor

Vikrant Verma Senior Resident

Varnika Rai Senior Resident

Anshima Singh Senior Resident

Cite this article: Rao RN, Verma V, Rai V, Singh A. Gastrointestinal basidiobolomycosis in children mimicking as abdominal malignancy: A rare case report. *IP Arch Cytol Histopathology Res* 2020;5(3):254-257.