



Case Report

Malherbe's Masquerade

Archana^{1,*}, Hilda Fernandes¹, Crysle Saldanha¹, Christol Moras¹

¹Dept. of Pathology, Father Muller Medical College, Mangalore, Karnataka, India



ARTICLE INFO

Article history:

Received 14-03-2020

Accepted 29-04-2020

Available online 11-06-2020

Keywords:

Cytology of Pilomatricoma

Benign cutaneous tumour

adnexal tumour

ABSTRACT

Introduction: Pilomatricoma, also known as calcifying epithelioma of Malherbe, was first described by Malherbe and Chenantais in 1880. It was described as a benign cutaneous tumour arising from the sebaceous glands. In 1961, its classical histopathological characteristics of epithelial cells and shadow cells were documented and hence, it was renamed as Pilomatricoma to be correct etymologically.

Case Report: A 47 year old male was referred to the cytology lab from the general surgery outpatient department for a fine needle aspiration with a history of a swelling on the right side of the neck since 1 year which was gradually progressive in size, no pain/discharge. A clinical diagnosis of? sebaceous cyst was provided. On examination, solitary swelling on the right side of the neck, 5 cm below the angle of the mandible, measuring 1.5x1 cm, firm in consistency, well defined with a smooth surface and mild erythema. Skin over the swelling – pinchable.

Fine needle aspiration was performed and on microscopy, the smears obtained were highly cellular and showed tight clusters of basaloid cells and few were singly dispersed. This was admixed with keratin flakes and few shadow cells, background also showed occasional multinucleate giant cells. A diagnosis of Benign adnexal tumour morphology favouring pilomatricoma was given.

Following the Fine needle Aspiration cytology report, he underwent an excision biopsy. Grossly - skin covered nodular tissue bit, cut surface - grey white areas with specs of calcification. Microscopically, an encapsulated lesion composed of basaloid cells undergoing abrupt transition to the formation of shadow cells with central clearing, mixed inflammatory infiltrate and foreign body giant cells. A diagnosis of Pilomatricoma was made.

Conclusion: Pilomatricoma (PMC) is a relatively uncommon benign skin neoplasm arising from the skin adnexa. Although there has been a gradual increase in the understanding of its clinical presentation and morphological features however, difficulties still persist in making a cytologic diagnosis. The purpose of this case report is to create awareness about the cytological features of pilomatricoma.

© 2020 Published by Innovative Publication. This is an open access article under the CC BY-NC license (<https://creativecommons.org/licenses/by-nc/4.0/>)

1. Background

Pilomatricoma, also known as calcifying epithelioma of Malherbe, was first described in 1880 by Malherbe and Chenantais as a benign subcutaneous tumour arising from sebaceous glands.¹

Dubreuilh and Cazenave later described the unique histopathologic characteristics of this neoplasm, with features of islands of epithelial and shadow cells.² In 1961, Forbis and Helwig suggested the term pilomatricoma, to

describe the condition to avoid an implication of malignancy and also depict its origin from hair matrix cells. In 1977, the term was eventually changed as "pilomatricoma" to be more correct etymologically.³ There is a female preponderance in the ratio of 3:2 with Caucasians being the most commonly affected group. These tumours have a predilection for the head and neck region. Surgical removal is the treatment of choice with an excellent prognosis.

* Corresponding author.

E-mail address: archana_mithran@yahoo.co.in (Archana).

2. Case Report

A 47 year old male patient was referred to the cytology lab from the general surgery OPD for an FNA with a history of a swelling on the right lateral aspect of the neck since 1 year and was gradually progressive in size. It was not associated with pain or discharge. No history of similar swellings elsewhere in the body. A clinical diagnosis in favour of sebaceous cyst was provided to us.

On examination, we found a solitary swelling on the right lateral aspect of the neck, 5 cm below the right angle of the mandible, measuring 1.5x1 cm, firm in consistency, well defined with a smooth surface. Skin over the swelling showed mild erythema and was pinchable; no tenderness was elicited. A punctum was not visible.

After explaining the procedure and obtaining consent from the patient, Fine needle aspiration was performed using a 23 gauge needle and 5mL syringe. Two passes were done from the lesion and haemorrhagic greasy material was obtained. Some of the smears were fixed in alcohol for PAP staining while the remaining were air dried for MGG staining.

FNA/1243/18

The smears obtained were highly cellular and showed tight clusters of basaloid cells and few were singly dispersed. This was admixed with keratin flakes and few shadow cells. Fibrillary material was seen enveloping the basaloid cells.

The background showed multinucleate giant cells, stromal fragments, necrosis, histiocytes and few RBCs.

A Diagnosis of Benign adnexal tumour morphology favouring pilomatricoma was given.

Following the FNAC report, he underwent an excision biopsy.

H/8092/19 – Grossly, we received a skin covered nodular tissue bit measuring 1.7x1.5x1.4 cms, ellipse of skin measured 1.5x1 cm and the cut surface was greyish white with areas of calcification. Microscopically, the sections studied showed an encapsulated lesion composed of basaloid cells undergoing abrupt transition to the formation of shadow cells with central clearing. Stroma showed mixed inflammatory infiltrate and foreign body giant cells. Special stain - von Kossa was performed and showed fine calcific deposits in the shadow cells.

Diagnosis of Pilomatricoma was made

3. Discussion

Pilomatricoma is a benign and slow growing cutaneous tumour with a differentiation towards the hair matrix of the hair follicle. On clinical examination, the skin over the swelling is either normal or hyperemic, with a size range from 0.5 to 3 cm.⁴ Apart from the head and neck region, other locations are the upper extremity, trunk and lower extremity in decreasing order of frequency. There are no documented cases on the palms, soles or genital

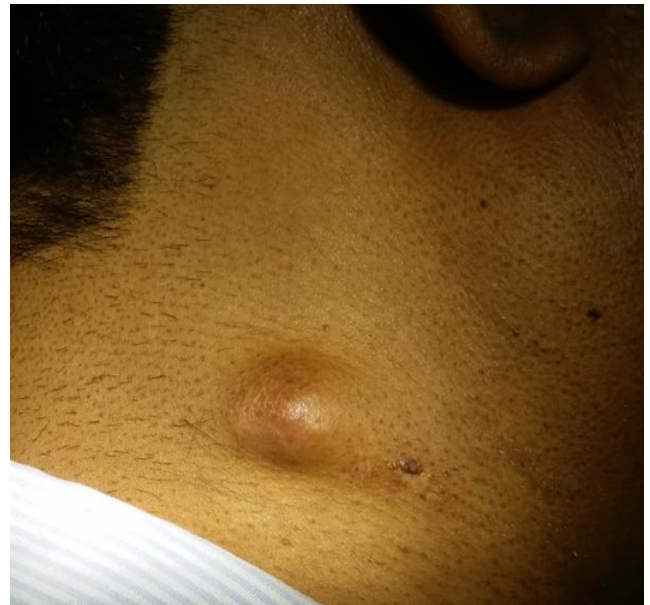

Fig. 1: – Swelling over the right side of the neck

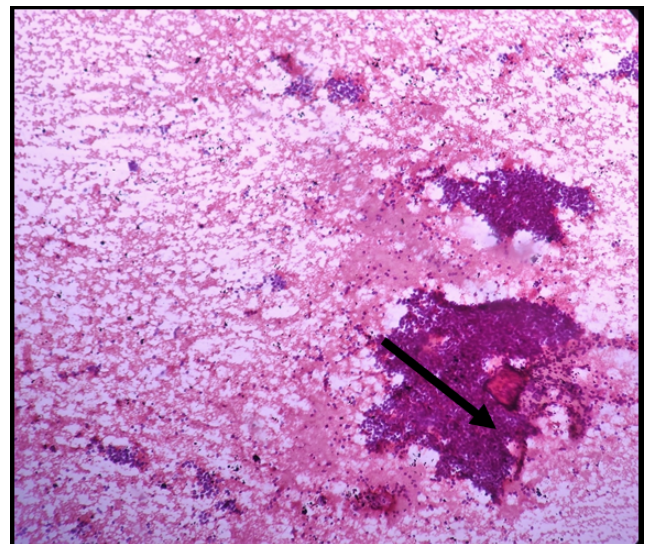


Fig. 2: Fine needle aspiration - Low power view– PAP stain clusters of basaloid cells with fibrillary material and keratin flakes

region.⁵ Lymphadenopathy at the time of diagnosis has never been reported.

A bimodal age of presentation is seen in the first and sixth decades of life, although, 40% of cases occur in patients younger than 10 years of age and 60% of cases occur within the first two decades of life.⁶

Pilomatricomas are usually asymptomatic, deep seated and firm, nontender subcutaneous masses. They are generally adherent to the overlying skin but are not fixed to the underlying tissue. Stretching of the skin over the tumor shows the characteristic “tent sign” with multiple

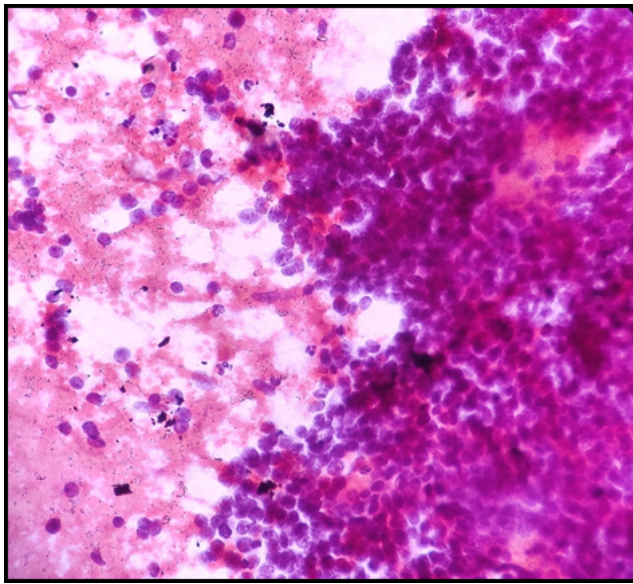


Fig. 3: Fine needle aspiration– high power view – PAP stain – clusters of basaloid cells and fibrillary material

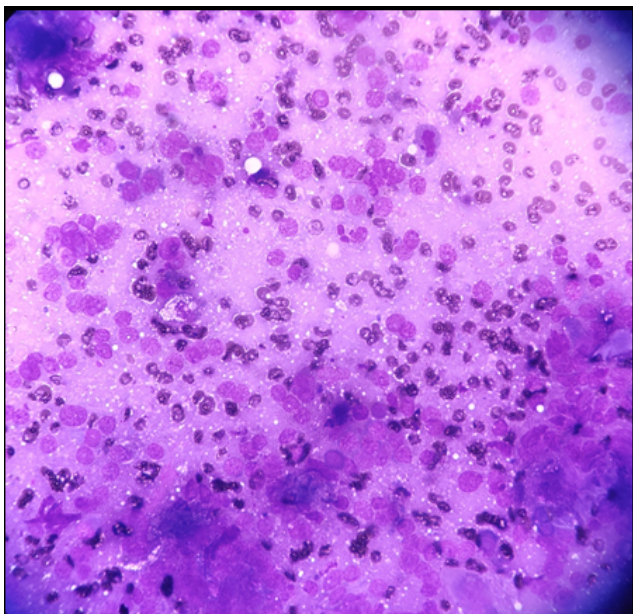


Fig. 4: Fine needle aspiration– High power view - MGG stain – Scattered basaloid cells

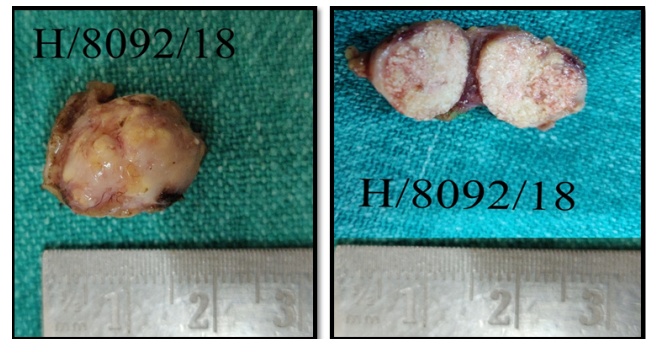


Fig. 5: H/8092/18 – Gross specimen – nodular tissue bit with a grey-white cut surface and foci of calcification

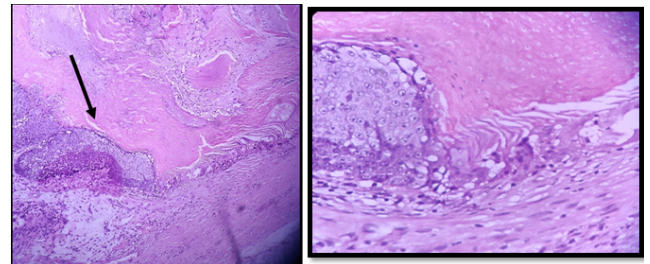


Fig. 6: Low and high power view– H/8092/18 – basaloid cells showing abrupt transition into shadow cells

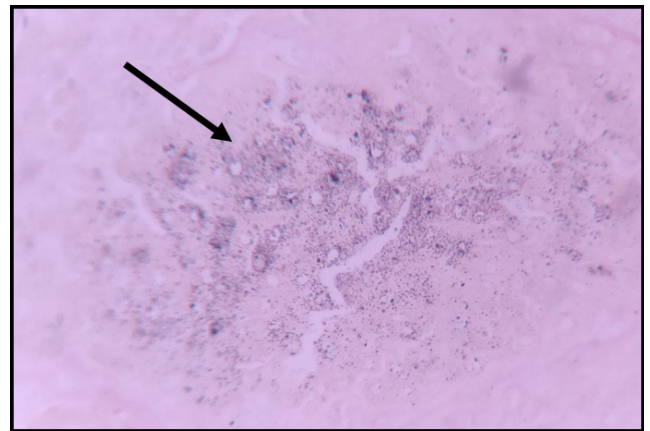


Fig. 7: Von Kossa stain showing fine granular calcific deposits in the shadow cells

facets and angles, and this is considered as a pathognomonic sign for pilomatricoma.² Another characteristic feature of Pilomatricoma is the bluish red discoloration of the overlying skin which excludes the possibility of a dermoid cyst or an epidermal inclusion cyst.

Even though pilomatricomas have well described features in literature, they continue to be frequently misdiagnosed. Surveys have demonstrated that the accuracy rate of the preoperative diagnosis of pilomatricoma ranges

from as low as 0% to 30%. This is probably attributable to the lack of familiarity with this tumour. Factors contributing to frequent misdiagnosis are: cystic lesions with a varying consistency, punctum like appearance due to skin tethering, atypical location and absence of clinically recognizable calcification. Another clinical predicament encountered is in the differentiation of this tumour from other benign non cutaneous and cutaneous masses which are encountered in the clinical practice more often. These lesions constitute a large spectrum and include: epidermal inclusion cyst,

dermoid cyst, brachial cleft remnants, preauricular sinuses, foreign body reaction, lipoma, degenerating fibroxanthoma, osteoma cutis, ossifying hematoma etc.⁴

Inclusion cysts have a diffuse yellow color when filled with keratin, are softer and more palpable. They are rarely encountered in childhood.² On the other hand, dermoid cysts are firmly attached to the underlying tissue and show normal skin moving freely over the lesion. Neither of these two masses exhibit irregular nodules on the skin whereas pilomatricoma does. Clinically, branchial cleft cysts present as a firm draining nodule.

Fine needle aspiration cytology FNAC may be helpful. However, the results of FNAC can be misleading if there are no ghost cells present in the aspirate attributing to the misdiagnosis of many cases.⁴ Histopathologically, pilomatricoma consists of basophilic cells and eosinophilic shadow cells in lobules and nests. Early lesions are predominantly comprised of basophilic cells which are grouped in islands at the periphery of the tumour. As the tumour progresses, the basophilic cells acquire more cytoplasm and gradually lose their nuclei to become eosinophilic shadow cells. The eosinophilic shadow cells form the central portion of the tumour and tend to calcify. These calcified foci impart a hard consistency to the tumour.²

The morphological stages of pilomatricoma are:

1. **Early:** small and cystic lesions.
2. **Fully developed:** large and cystic.
3. **Early regressive:** foci of basaloid cells, shadow cells and lymphocytic infiltrate with multinucleated giant cells.
4. **Late regressive:** numerous shadow cells, absence of basaloid and inflammatory cells, calcification and ossification may be present. Based on these criteria our case fits into the early regressive stage.⁵

Pilomatricomas have never been known to regress spontaneously and malignant transformation is highly infrequent and hence, surgical excision is the gold standard of treatment options. Recurrence after surgery is rare, with an incidence of 0 to 3%. Malignant transformation to a pilomatrix carcinoma should be suspected in cases with repeated local recurrences.³

4. Conclusion

Pilomatricoma is a relatively uncommon clinically diagnosed condition. A strong index of suspicion is required by the pathologist when clusters of basaloid cells with shadow cells are encountered. One of the pitfalls in fine needle aspiration is a non-representative aspirate. In our case, the clusters of basaloid cells with a focus of shadow cells helped in the diagnosis which was confirmed with histopathology. Hence, a familiarity with this tumour will help in an accurate diagnosis.

5. Source of Funding

None.

6. Conflict of Interest

None.

References

1. Malherbe A, Chenanatis J. Note sur l'epitheliomacalcifiedes glandes sebacees. *Prog Med.* 1880;8:826–37.
2. Pant I, Joshi S, Kaur G, Kumar G. Pilomatricoma as a diagnostic pitfall in clinical practice: Report of two cases and review of literature. *Indian J Dermatol.* 2010;55(4):390–2.
3. FORBIS R. Pilomatricoma (Calcifying Epithelioma). *Arch Dermatol.* 1961;83(4):606–17.
4. Yencha MW. Head and neck pilomatricoma in the pediatric age group: a retrospective study and literature review. *Int J Pediatr Otorhinolaryngol.* 2001;57(2):123–8.
5. Boyd AS, Martin RW. Pathologic quiz case 1. Pilomatricoma calcified epithelioma of Malherbe with secondary ossification. *Arch Otolaryngol Head Neck Surg.* 1992;118:212–5.
6. Moehlenbeck FW. Pilomatricoma calcifying epithelioma. A statistical study. *Arch Dermatol.* 1973;108:532–4.

Author biography

Archana Post Graduate Resident

Hilda Fernandes Professor and Former HOD

Cryslle Saldanha Assistant professor

Christol Moras Assistant professor

Cite this article: Archana , Fernandes H, Saldanha C, Moras C. **Malherbe's Masquerade.** *IP Arch Cytol Histopathology Res* 2020;5(2):159-162.