



## Case Report

# Non-surgical endodontic management of mandibular first premolar with three roots and root canals: A case report

Deepa Jayaraj<sup>1,\*</sup>, Elsy P Simon<sup>1</sup>, M Ramesh Kumar<sup>1</sup>, Chandini Raveendran<sup>1</sup>,  
Amitha Krishna<sup>1</sup>, Mariyam Sanoona Areekan<sup>1</sup>

<sup>1</sup>Dept. of Conservative Dentistry and Endodontics, KMCT Dental College, Kozhikode, Kerala, India



### ARTICLE INFO

#### Article history:

Received 07-09-2020

Accepted 11-09-2020

Available online 11-11-2020

#### Keywords:

Anatomical variations

Mandibular first premolar

Three root canals

### ABSTRACT

A detailed knowledge of the pulp canal anatomy and variations in individual tooth is important to effectively clean and shape the root canal system. Identification of such variations and their instrumentation together with adequate disinfection can avoid need for future retreatment and surgical intervention. Several case reports reported variations in tooth morphology and root canal systems related to the mandibular first premolars. The occurrence of three roots in the mandibular first premolar is unusual. This article reports the identification and management of mandibular first premolar with aberrant root and root canal system.

© 2020 Published by Innovative Publication. This is an open access article under the CC BY-NC license (<https://creativecommons.org/licenses/by-nc/4.0/>)

## 1. Introduction

For root canal treatment to be successful, it is necessary to locate all root canals, debride them thoroughly and seal them three-dimensionally with an inert root filling material. A complete knowledge on the pulp canal anatomy is critical to successfully clean and shape the canal and its varying morphology which eventually will build the long-term success of the treatment. In the literature, the mandibular first premolar is usually single-rooted with incidence of 97.1%. However, studies revealed an incidence of approximately 2.7% of bifurcated teeth. Mandibular first premolar with three roots are extremely rare with an incidence of 0.2%. Scott and Turner described the accessory root as “Tome’s root”.<sup>1</sup>

Although uncommon, possible variations in morphology reported in the literature include mandibular one rooted first premolars with two canals, three canals and four canals; two rooted with two canals, three canals and four canals; three rooted with three canals and four rooted with four canals.<sup>1</sup>

This article reports identification and nonsurgical endodontic management of mandibular first premolar with

three separate roots and three separate root canals.

## 2. Case Report

A 46-year-old female reported to the Department of Conservative Dentistry and Endodontics with a chief complaint of pain in her lower right back tooth region while having food for five days. Medical history of the patient was noncontributory. She reported lingering pain associated with intake of hot and cold drinks in the right posterior mandibular tooth. Clinical examination revealed deep distal caries in relation to #44. Cold test with EndoFrost (Coltene Whaledent, Langenau, Germany) and electric pulp test on the involved tooth showed hyper response and lingering pain. Pre-operative radiograph for #44 [Figure 1A] revealed radiolucency involving enamel and dentin which was approximating pulp chamber. There was no radiographic evidence of apical periodontitis. Radiographic examination revealed the aberrant morphology of the first premolar root. The tooth was diagnosed with symptomatic irreversible pulpitis secondary to dental caries based on the clinical and radiographic examination and it was decided to carryout endodontic treatment in mandibular first right premolar.

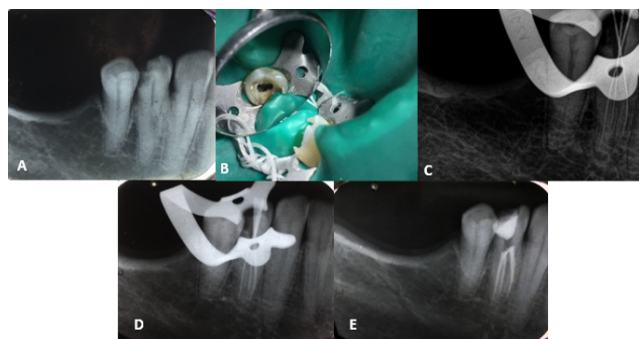
\* Corresponding author.

E-mail address: [deepadjs@gmail.com](mailto:deepadjs@gmail.com) (D. Jayaraj).

Inferior alveolar nerve block with 2% lignocaine was administered to achieve profound anesthesia. The tooth #44 was isolated with rubber dam (Hygenic Coltene Whaledent). After the removal of caries, a conventional access cavity was prepared with Endo Access bur (Dentsply Maillefer, Switzerland). Exploration of pulpal floor with a DG 16 explorer (Hu-Friedy, USA) and the use of dental loupe revealed three orifices. Two separate buccal orifices and one lingual were identified [Figure 1B]. The access cavity was slightly modified for straight line access.

All the canals were negotiated with #10 K file, with Glyde EDTA gel (Dentsply Maillefer, USA) as a lubricant. Working length was determined using electronic apex locator (Apex ID, Densply Sirona, USA) and confirmed with radiograph. Three separate roots with three separate canals was confirmed in the working length radiograph [Figure 1C]. All canals were initially prepared with K-files 10, 15, and 20 (Mani Inc., Japan) then completed with hand ProTaper (Dentsply Maillefer, USA) up to size F2. 17% EDTA, normal saline and 3% sodium hypochlorite (Prevest Denpro, Jammu City, India) irrigant were used during cleaning & shaping. Sodium hypochlorite and normal saline were used as final irrigants. After radiographic confirmation of master cones (Diadent, India) [Figure 1D], the root canals were dried with paper points (Diadent, India) and obturated with gutta percha and Zical sealer (Prevest Denpro, Jammu City, India) by lateral condensation technique Temporary restoration (Cavit G, 3M ESPE, Germany) was given.

The presence of three distinct roots with three separate canals also confirmed in the post obturation radiograph [Figure 1E]. After one week, access was permanently restored with amalgam and patient was referred to the Department of Prosthodontics for post endodontic and prosthetic management.



**Fig. 1:** Mandibular right first premolar (#44) A. Preoperative radiograph, B. Access cavity with three canals, C. Working length radiograph, D. Master cone radiograph and E. Postobturation radiograph.

### 3. Discussion

The mandibular premolars present highly variable and complex root canal morphology and it is a challenging task in locating, cleaning, shaping, and obturating all root canals for successful endodontic therapy with such teeth. Failure of any of these principles can lead to posttreatment disease, pain, and/or complications of root canal treated tooth.

Because of the wide variation in the internal and external root morphology, mandibular premolars are considered to be the most difficult to treat endodontically. Also, the division of the roots and/or root canals in these teeth occurs mostly in the middle and apical thirds which makes detection of these anatomical variations difficult.<sup>2</sup>

An inability to locate and adequately treat all the canals of the root canal system was accepted as a major reason for root canal treatment failure.<sup>3</sup> Allen et al reported that untreated canals were responsible for failure with a prevalence of 8.8% in their classic study for factors that may contributed to the failure of the original treatment with 1300 endodontic subjects.<sup>4</sup> According to Hoen and Pink, missed canals were the major reason for endodontic re-treatment in 42% of the cases studied.<sup>5</sup> From the studies of Serman and Hasselgren with full mouth series of radiographs, at least one mandibular first premolar with either a divided canal or root was observed in 15.7% of patients.<sup>6</sup> According to the classic Washington study of endodontic therapy in mandibular premolars, 11.45% of failure rate was observed in mandibular first premolar.<sup>7</sup> The extreme variations in root canal morphology of mandibular premolar teeth may be ascribed to this and therefore poses an endodontic challenge to the dentist. Difficult access, cleaning and sealing of a second canal were also possible reasons for a high failure rate.<sup>1</sup>

Detection of any morphological variations of teeth and root canals are best accomplished with sound knowledge of the anatomical variations of the tooth in concern. Careful evaluation of two or more high quality diagnostic periapical radiographs at different horizontal angulations together with proper use of available armamentarium can aid in its management.<sup>2,8,9</sup> These radiographs provide much needed information about root canal morphology. A “fast break” of the canal on parallel radiographs might be an indication of the presence of more than one canal.<sup>3</sup> In addition, using advanced diagnostic radiographic techniques such as Cone Beam Computed Tomography (CBCT) is very helpful to detect such variations if conventional radiographic techniques lack to provide obvious information and more details required.

In the present case, unusual root shape was observed in the pretreatment radiograph of the mandibular right first premolar, which suggested the possibility of extra roots and canals. During access cavity preparation, vague outlines of three canal orifices were noticed. It was in accordance with Rodig and Hulsmann, who stated that the presence

of a triangle-shaped pulp chamber is the characteristic of mandibular premolars with three root canals, in which the distance from the distobuccal to the lingual orifices was at a peak.<sup>10</sup> Visual examination of the sub-pulpal floor dentin map with loupe at 3.5x and exploration of the developmental groove with DG-16 help to locate three canal orifices; one canal orifice was on the lingual aspect, one canal orifice was on the buccal aspect, and the third orifice was located distal to the two other orifices (mesiobuccal, mesiolingual, and distal).

The working length determination radiograph of the mandibular first premolar provided valuable information on the presence and position of the extra root, as the third root was not visible on the preoperative radiograph because of the superimposition of roots.

Magnification with loupes or dental operating microscope (DOM) is an indispensable tool to locate extra canals. The American Association of Endodontics have reported the benefits of magnification in locating hidden canals, tracing cracks or fracture lines, removal of canal obstructions, refinement of the access preparations, and all aspects of endodontic microsurgery.<sup>11,12</sup> Various ranges of magnification levels are available, but typically 2.5x to 4.5x is appropriate to visualize the extra canal with increased depth of field.<sup>2</sup> Commercially available microscopes provide adjustable magnification ranging from approximately 4x-25x magnification, while most loupes provide fixed magnification between 2.5x-6x. Low (~2x-8x), mid (~8x-16x) and high (~16x-25x) magnification are applicable for different procedural steps throughout nonsurgical and surgical endodontic treatment. Low magnification is providing an overview of the operating field. Mid magnification is mainly used for procedural steps throughout root canal therapy and endodontic surgery. High magnification is used for the identification of minute structures and documentation of the finest details.<sup>11</sup>

Even though DOM was not used in this clinical case, its use is recommended in routine endodontic practice as it offers an excellent illumination and magnification to the operating field and provides a tremendous advantage in locating and treating 'extra' canals as it brings minute details into clear view. Several studies and case reports have shown that the DOM significantly increases the dentist's ability to locate and negotiate canals.<sup>13-15</sup> Baldassari-Cruz et al demonstrated an increase in the number of second mesio-buccal canals (MB2) located from 51% with the naked eye to 82% with the DOM.<sup>13</sup> Coelho de Carvalho and Zuolo concluded that the DOM made locating canals easier by magnifying and illuminating the grooves in the pulpal floor and differentiating the color differences between the dentin of the floor and the walls.<sup>14</sup> The DOM had enabled them to locate 8% more canals in mandibular molars.<sup>14</sup>

DOM will aid in the proper examination of the floor of the pulp chamber, localizing canals orifices, and detecting these variations which could not be seen easily due

to the limited access opening. Interpretation of angled radiographs, good access preparation, proper inspection of pulpal floor, and a detailed examination of the interior of the tooth perfectly under magnification and illumination are important prerequisites for a successful treatment outcome.

#### 4. Conclusion

Although it is very rare for a mandibular first premolar to have three roots, each case should be carefully examined radiographically and clinically to locate all the root canals. An endodontist should be prepared for the variations and thoroughly scrutinize the pulpal floor and root canals. The triumph of nonsurgical endodontic procedures is greatly influenced by thorough knowledge of root canal anatomy and its variations, careful interpretation of the radiographs, close clinical inspection of the floor of the chamber and proper modification of access opening along with adequate magnification.

#### 5. Source of Funding

No financial support was received for the work within this manuscript.

#### 6. Conflict of Interest

The authors declare they have no conflict of interest.

#### References

1. Ingle R, Ingle's JI. Ingle's Endodontics. PMPH USA; 2019.
2. Cleghorn BM, Christie WH, Dong CCS. The Root and Root Canal Morphology of the Human Mandibular First Premolar: A Literature Review. *J Endod.* 2007;33(5):509–16.
3. Vertucci FJ. Root canal morphology and its relationship to endodontic procedures. *Endod Topics.* 2005;10(1):3–29. doi:10.1111/j.1601-1546.2005.00129.x.
4. Allen RK, Newton CW, Brown CE. A statistical analysis of surgical and nonsurgical endodontic retreatment cases. *J Endod.* 1989;15(6):261–6. doi:10.1016/s0099-2399(89)80221-3.
5. Hoen M, Pink F. Contemporary Endodontic Retreatments: An Analysis based on Clinical Treatment Findings. *J Endod.* 2002;28(12):834–6. doi:10.1097/00004770-200212000-00010.
6. Serman NJ, Hasselgren G. The radiographic incidence of multiple roots and canals in human mandibular premolars. *Int Endod J.* 1992;25(5):234–7. doi:10.1111/j.1365-2591.1992.tb01155.x.
7. Ingle JI, Bakland LK. Ingle's endodontics 5. Decker Inc; 2002.
8. England MC, Hartwell GR, Lance JR. Detection and treatment of multiple canals in mandibular premolars. *J Endod.* 1991;17(4):174–8. doi:10.1016/s0099-2399(06)82012-1.
9. Hulsman M. Mandibular first premolar with three root canals. *Dent Traumatol.* 1990;6(4):189–91. doi:10.1111/j.1600-9657.1990.tb00416.x.
10. Rödiger T, Hülsmann M. Diagnosis and root canal treatment of a mandibular second premolar with three root canals. *Int Endod J.* 2003;36(12):912–9. doi:10.1111/j.1365-2591.2003.00750.x.
11. and CFS. Dental Operating Microscope Clinical Newsletter - AAE; 2016.
12. AAE Special Committee to Develop a Microscope Position Paper. AAE Position Statement. Use of microscopes and other magnification techniques. *J Endod.* 2012;38(8):1153–5.

13. Baldassari-Cruz LA, Lilly JP, Rivera EM. The influence of dental operating microscope in locating the mesiolingual canal orifice. *Oral Surg, Oral Med, Oral Pathol, Oral Radiol, Endodontol.* 2002;93:190–4. doi:10.1067/moe.2002.118285.
14. de Carvalho M, Zuolo ML. Orifice Locating with a Microscope. *J Endod.* 2000;26(9):532–4. doi:10.1097/00004770-200009000-00012.
15. Al-Fouzan KS. The microscopic diagnosis and treatment of a mandibular second premolar with four canals. *Int Endod J.* 2001;34(5):406–10. doi:10.1046/j.1365-2591.2001.00408.x.

**M Ramesh Kumar**, Professor and HOD

**Chandini Raveendran**, Senior Lecture

**Amitha Krishna**, Post Graduate Student

**Mariyam Sanoona Areekan**, Post Graduate Student

### Author biography

**Deepa Jayaraj**, Post Graduate Student

**Elsy P Simon**, Professor

**Cite this article:** Jayaraj D, Simon EP, Kumar MR, Raveendran C, Krishna A, Areekan MS. Non-surgical endodontic management of mandibular first premolar with three roots and root canals: A case report. *IP Indian J Conserv Endod* 2020;5(4):203-206.