



Case Report

Endodontic management and follow-up of two rooted maxillary lateral incisor with open apex – A case report

R. AnithaKumari^{1,*}, Sneha Jeetendra¹, Siddharth Rai¹, Sudhanva Eregowda¹

¹Dept. of Conservative Dentistry & Endodontics, V.S.Dental College & Hospitals, Bangalore, Karnataka, India



ARTICLE INFO

Article history:

Received 26-09-2020

Accepted 06-10-2020

Available online 11-11-2020

Keywords:

MTA plug

Openapex

Periapical lesion

Two rooted lateral incisor

ABSTRACT

Anatomical variations in the root are quite possible, if such teeth are infected, it is challenging to treat them. A patient with two rooted maxillary lateral incisor having open apex with periapical lesion reported to the department. Non-surgical endodontic treatment was initiated under magnification, open apex was sealed with MTA plug and root canal treatment completed. The case was followed up for one year and there was radiographic healing of periapical lesion.

© 2020 Published by Innovative Publication. This is an open access article under the CC BY-NC license (<https://creativecommons.org/licenses/by-nc/4.0/>)

1. Introduction

Thorough knowledge of the root canal anatomy is very important for the success of endodontic therapy.¹ Anatomical complexities might interfere hindering the exploration, shaping, cleaning and disinfection of root canals.² Maxillary lateral incisors normally have a single root and single canal.³ However, morphological variations for these teeth include the presence of two^{4,5} three^{6,7} four⁸ and even five canals⁹ usually associated with the occurrence of traumatic stimuli during tooth development process¹⁰. Other morphological variations such as dens invagination^{9,11} radicular groove¹² and fusion,¹³ germination¹⁴ are also associated with the maxillary lateral incisors. There were cases of maxillary lateral incisors with two roots^{5,15–19} reported, but two rooted maxillary lateral incisor, one root with open apex and another normal root has not been reported in the literature.

2. Case Report

32 year old male patient reported to the department of conservative Dentistry & Endodontics, complaining of discoloured front tooth, on clinical examination # 22 was discoloured, the labial surface was intact, free of any surface defect and the palatal surface had a groove like defect extending from the cervical third of the crown & extending below the gingival margin. On probing the labial surface a groove was found starting in the Cemento Enamel junction extending subgingivally. The tooth was grade one mobile on percussion and did not respond to thermal tests. Intra Oral Periapical Radiograph (IOPA) (Figure 1) revealed two roots, one wide mesial root with open apex and thin distal root with periapical radiolucency involving both the roots. Based on the clinical examination and radiographic finding, diagnosis of pulpal necrosis with chronic apical periodontitis was established. Root canal treatment with the apexification was planned for the tooth.

Informed consent was taken from the patient and access opening was done using Endo Access bur no 1(Dentsply) under rubber dam isolation and magnification with loupes (3.5X) (Sanma Medineer Vision), working length determination done using Root ZX(JM Morita,

* Corresponding author.

E-mail address: anitha.blr53@yahoo.in (R. AnithaKumari).

Japan) apex locator & confirmed with the intraoral periapical radiograph. Cleaning and shaping was done using stainless steel K-files in circumferential and step-back technique till size 80 in mesial root and size 25 in distal root at working length while irrigating with 1.5% sodium hypochlorite throughout the procedure. Apical plug of MTA (proroot) was placed in the mesial root using MTA plugger(GDC, India) and hand plugger and moist cotton pellet was placed over it and coronal access sealed with caviti (3M ESPE). In the next visit back filling of mesial root was done using Calamus dual obturation system (Dentsply Sirona) and lateral canal was obturated with gutta-percha points and AHplus sealer (Dentsply De Trey GmbH, Germany) in lateral condensation technique (Figure 2). Coronal access was sealed with light cure composite Z250 (3MESPE). The tooth was followed up for 1 year after the root canal treatment with IOPA radiograph. (Figure 3). The patient was asymptomatic & the post-operative IOPA radiograph was suggestive of periapical healing.

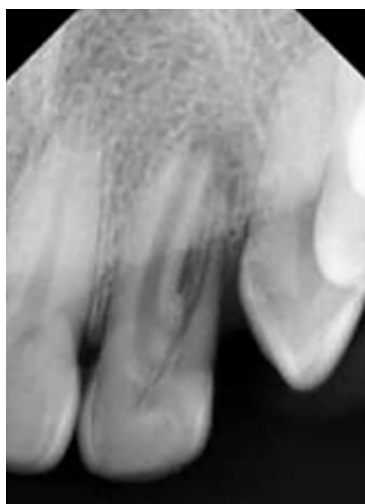


Fig. 1: pre-operative radiograph of #22 showing two roots

3. Discussion

The common developmental anomalies associated with maxillary lateral incisor are gemination, fusion, dens in dente and palatogingival groove. In gemination, there will be larger incompletely separated crown with single root & root canal. Fusion is union of two tooth germs resulting in a large crown with two root canals. Gemination & fusion are a common occurrence in deciduous than permanent dentition. Dens invaginatus presents itself as a radio-lucent sac surrounded by a radio-opaque enamel border in the radiograph. Since none of these findings were seen in our case & it presented in the radiograph with two distinct roots, broader mesial root and narrow thin distal root it was considered as a case of maxillary lateral incisor with

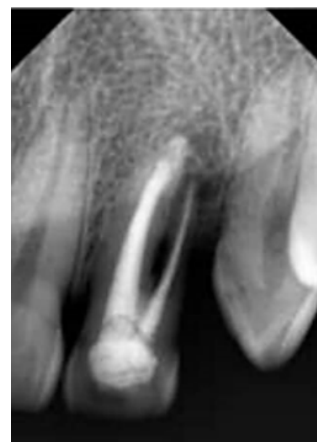


Fig. 2: Post endodontic radiograph of #22

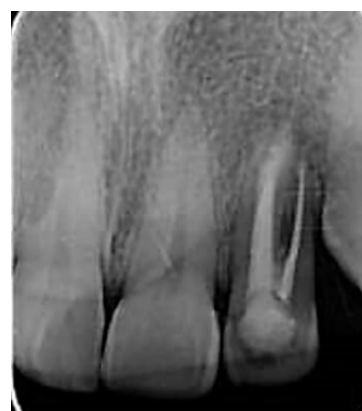

Fig. 3: One year follow-up radiograph of #22 showing healing of peirapical lesion

one regular & extra accessory root. There were cases of maxillary lateral incisors with two roots^{5,15–19} reported, but two rooted maxillary lateral incisor, one root with open apex and another normal root has never been reported in the literature. Since one mesial and one distal root was clearly seen in the IOPA radiograph, we did not find the need for CBCT imaging. One of the challenges faced in the treatment of open apex is lack of apical stop, thus achieving a good apical seal is difficult. Apexification is formation of an apical calcified barrier consisting of osteocementum or other bone like tissue.²⁰ Materials such as calcium hydroxide, Mineral Trioxide Aggregate (MTA) and Biodentine are used in the apexification procedure. Calcium hydroxide requires about 3 to 17 months,²¹ requiring multiple visits for material replacement and long term exposure may weaken the root structure. MTA has many advantages such as hard tissue formation, sealing ability and biocompatibility. In spite of disadvantages such as long setting time, handling difficulty, expensive material²², MTA still remains the preferred material in the apexification of open apex cases. The shorter treatment time with MTA may translate

into higher overall success rate because of better patient compliance.²³

4. Conclusion

Thorough knowledge of the anatomical variations in the root and root canal, adequate knowledge and skill with newer materials and techniques aid in the better management and outcome of clinically challenging endodontic cases.

5. Source of Funding

No financial support was received for the work within this manuscript.

6. Conflict of Interest

The authors declare they have no conflict of interest.

References

- Vertucci FJ. Root canal morphology and its relationship to endodontic procedures. *Endod Top*. 1971;10(1):3–29.
- Andreasen JO, Sundstrom B, Ravn JJ. The effect of traumatic injuries to primary teeth on their permanent successors. *Eur J Oral Sci*. 1971;79(3):219–83. doi:10.1111/j.1600-0722.1971.tb02013.x.
- Vertucci FJ. Root canal anatomy of the human permanent teeth. *Oral Surg, Oral Med, Oral Pathol*. 1984;58(5):589–99. doi:10.1016/0030-4220(84)90085-9.
- Lee MH, Ha JH, Jin MU, Kim YK, Kim SK. Endodontic treatment of maxillary lateral incisors with anatomical variations. *Restor Dent Endod*. 2013;38(4):253–7.
- Mohan AG, Ebenezar AVR, George L, Sujathan, Josy SA. Maxillary lateral incisors with two canals and two separate curved roots. *Contemp Clin Dent*. 2012;3(4):519–21. doi:10.4103/0976-237x.107460.
- Jung M. Endodontic treatment of dens invaginatus type III with three root canals and open apical foramen. *Int Endod J*. 2004;37(3):205–13. doi:10.1111/j.0143-2885.2004.00778.x.
- Peix-Sánchez M, Mi-ana-Laliga R. A case of unusual anatomy: a maxillary lateral incisor with three canals. *Int Endod J*. 1999;32(3):236–40.
- Nosrat A, Schneider SC. Endodontic Management of a Maxillary Lateral Incisor with 4 Root Canals and a Dens Invaginatus Tract. *J Endod*. 2015;41(7):1167–71. doi:10.1016/j.joen.2015.02.013.
- Jaikailash S, Kavitha M, Ranjani MS, Saravanan B. Five root canals in peg lateral incisor with dens invaginatus: A case report with new nomenclature for the five canals. *J Conserv Dent*. 2014;17(4):379–81.
- Diab M, Badrawy HEE. Intrusion injuries of primary incisors. Part III: effects on the permanent successors. *Quintessence Int*. 2000;31(6):377–84.
- Bahmani M, Adl A, Javanmardi S, Naghizadeh S. Diagnosis and treatment of a type III dens invagination using cone beam computed tomography. *Iranian Endod J*. 2016;11(4):341–6.
- Kishan KV, Hegde V, Ponnappa KC, Girish TN, Ponappa MC. Management of palato radicular groove in a maxillary lateral incisor. *J Nat Sci, Biol Med*. 2014;5(1):178–81.
- Yagci A, Cantekin K, Buyuk SK, Pala K. The Multidisciplinary Management of Fused Maxillary Lateral Incisor with a Supernumerary Tooth in Cleft Lip Adolescence. *Case Rep Dent*. 2014;2014:1–5. doi:10.1155/2014/459416.
- Mahendra L, Govindarajan S, Jayanandan M, Shamsudeen SM, Kumar N, Madasamy R, et al. Complete bilateral gemination of maxillary incisors with separate root canals. *Case Rep Dent*. 2014;p. 4.
- Sykaras SN. A two-rooted maxillary lateral incisor. *Oral Surg, Oral Med, Oral Pathol*. 1972;34(2):349. doi:10.1016/0030-4220(72)90429-x.
- Zillich RM, Ash JL, Corcoran JF. Maxillary lateral incisor with two roots and dens formation: A case report. *J Endod*. 1983;9(4):139–43. doi:10.1016/s0099-2399(83)80034-x.
- Ravindranath M, Neelakantan P, and CVSR. Maxillary lateral incisor with two roots: a case report. *Gen Dent*. 2011;59(1):68–77.
- Lee MH. Endodontic treatment of maxillary lateral incisors with anatomical variations. *Rest Dent Endo*. 2013;38(4):253–7.
- Yadav SS, Shah N. Nonsurgical endodontic management of a two-rooted maxillary lateral incisor. *Saudi Endod J*. 2016;6(1):40–2. doi:10.4103/1658-5984.172001.
- Mohammadi Z, Dummer PMH. Properties and applications of calcium hydroxide in endodontics and dental traumatology. *Int Endod J*. 2011;44(8):697–730.
- Finucane D, Kinirons MJ. Non-vital immature permanent incisors: factors that may influence treatment outcome. *Dent Traumatol*. 1999;15(6):273–7. doi:10.1111/j.1600-9657.1999.tb00787.x.
- Kokate SR, Pawar AM. An invitro comparative streomicroscopic evaluation of marginal seal between MTA, GIC and Biodentine as root end filling materials using 1% methylene blue as tracer. *Endodontol*. 2012;2:36–42.
- Lin JC, Lu JX. Comparison of MTA and Calcium hydroxide for apexification of immature permanent teeth. A systematic review and meta-analysis. *J Formosan Med Assoc*. 2016;115(7):523–30.

Author biography

R. AnithaKumari, Professor

Sneha Jeetendra, Post Graduate Student

Siddharth Rai, Post Graduate Student

Sudhanva Eregowda, Reader

Cite this article: AnithaKumari R, Jeetendra S, Rai S, Eregowda S. Endodontic management and follow-up of two rooted maxillary lateral incisor with open apex – A case report. *IP Indian J Conserv Endod* 2020;5(4):200-202.