



## Review Article

## Different materials used for repair of root perforation: A review

Abhishek Sharma<sup>1,\*</sup>, Abhishek Avasthi<sup>2</sup>, Ramandeep Singh<sup>2</sup>, Neha<sup>3</sup>, Namita Tandon<sup>4</sup>, Atul Kumar<sup>5</sup>

<sup>1</sup>Dept. of Prosthodontics Crown Bridge and Implantology, Himachal Institute of Dental Sciences, Paonta Sahib, Himachal Pradesh, India

<sup>2</sup>Dept. of Prosthodontics Crown Bridge and Implantology, Bhojia Dental College and Hospital, Bhud, Baddi, Himachal Pradesh, India

<sup>3</sup>Dept. of Paedodontics and Preventive Dentistry, Himachal Institute Of Dental Sciences, Paonta Sahib, Himachal Pradesh, India

<sup>4</sup>Dept. of Conservative Dentistry and Endodontics, Post Graduate Institute of Medical Education & Research, Chandigarh, India

<sup>5</sup>Dental Surgeon, Jammu City, Jammu & Kashmir, India



## ARTICLE INFO

## Article history:

Received 22-10-2020

Accepted 29-10-2020

Available online 11-11-2020

## Keywords:

Root Perforation

MTA

Calcium hydroxide

## ABSTRACT

Root perforation is commonly caused by procedural accident during operative procedure or might be due to any pathological alteration. Perforation can be defined as an artificial communication between oral environment and the supporting structures in the external root surfaces which may causes serious implications that can even lead to extraction. If the perforation diagnosed at early and proper measures taken for the perforation, can lead to long term survival of the tooth/teeth.

© 2020 Published by Innovative Publication. This is an open access article under the CC BY-NC license (<https://creativecommons.org/licenses/by-nc/4.0/>)

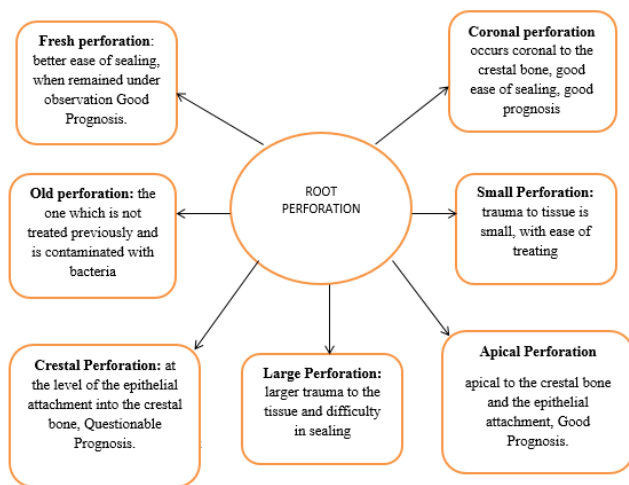
## 1. Introduction

Root perforations can occur pathologically as a result of resorption and caries or iatrogenically during root canal treatment procedure.<sup>1</sup> Such types of injury to the tooth might lead for compromising treatment outcome of the tooth and may lead to further complications, if not treated appropriately. This type of injury might occur during access cavity preparation for the endodontic treatment, might occur during post space creation for endodontically treated tooth to undergo post and core procedure, or may occur as a result of internal resorption.<sup>2</sup> Errors during operative procedure can occur at any time during endodontic treatment and may lead to failure of the treatment.<sup>3</sup> Some factors may proceed to operative accidents, such as pulp stone, calcification, incorrect inclination of the tooth in the arch, grossly decayed tooth, or internal resorption, extra coronal restoration, may lead to perforation of the

root.<sup>4-9</sup> Root perforation may contribute to doubtful or poor prognosis.<sup>10</sup> The consequences of root perforation may lead to inflammatory response to the surrounding periodontal tissue which may lead to destruction of alveolar bone.<sup>9</sup> Depending on the severity of the injury, and possible chronic inflammatory reaction, it may cause the development of granulomatous tissue, proliferation of the epithelium, and, eventually, the development of a periodontal pocket. Lack of knowledge of root perforation may result in future problem and may eventually lead to tooth loss.<sup>11</sup>

\* Corresponding author.

E-mail address: [abhi16febabhi1992@gmail.com](mailto:abhi16febabhi1992@gmail.com) (A. Sharma).



### Classification:- According to Fuss and Trope<sup>12</sup>

2-12% of endodontically treated teeth have the chances of accidental root perforation. This injury act as an open channel for microorganisms to enter through periodontal tissue or root canal finally eliciting towards inflammatory responses that results in destruction of alveolar bone. When there is lateral perforation or injury occur in the furcation area, there might be a chance of growth of epithelium towards the site of injury, which finally results in poor prognosis.<sup>9</sup> There are several factors which determines the prognosis of the defect, which includes, size of the perforation, location of the perforation, time, duration, material used for the repair, and the accessibility to the main CANAL.<sup>13</sup> Always a small perforation/ injury which is apical to the crestal bone and which is closed immediately, always have the good prognosis.

## 2. Different materials used in the repair of perforation

### 2.1. Indium foil

Initially indium foil was used as repair material for root perforation, but it has shown that indium foil leads to more severity of bone resorption, and that's why not using in now a days. It was mainly used to prevent gross filling.<sup>14</sup>

### 3. Plaster of paris

One of the most common material, which has its wide use in the field of dentistry. Plaster of paris is a bio compatible, resorbable material. The rate of resorption of plaster of paris is equal to rate of growth of new alveolar bone in to the tissue. Plaster of paris has also been used as a bone substitute for filling the bone defects.<sup>15</sup>

### 4. Zinc Oxide Eugenol

One of the most commonly used material in the field of dentistry in various aspects. According to Bramante et al,

they stated that, tooth perforations treated with zinc oxide eugenol shows severe inflammatory response in the peri radicular tissue, which results in formation of abscess, and finally lead to resorption of alveolar bone. Tooth/teeth perforation treated with zinc oxide eugenol shows poor prognosis.<sup>16</sup>

## 5. Gutta Percha

Most commonly used in endodontic treatment. Gutta percha when used in case of tooth/teeth perforation, cause less inflammation when compared to perforation treated with zinc oxide eugenol, zinc phosphate. Benenati et al stated that, perforation treated with gutta percha, shows poor prognosis and the repair in most of the cases is a failure.<sup>17</sup>

## 6. GIC (Glass ionomer cement)

Glass ionomer cement shows higher sealing potential towards root perforation, because of its mechanism of adhesion. A study done by Alhadainy and Himel, stated that the glass ionomer cement which is light cured, shows more sealing towards the root perforation and provide better seal than the amalgam or cavite.<sup>18</sup>

## 7. Metal modified glass ionomer cement

Metal modified GIC is manufactured by sintering of silver particles to aluminosilicate powder. It shows good properties of adhesion to the dentine, provide adequate sealing, adequate working time and good ease of delivery. Studies shown that perforations treated with resin modified GIC cement shows less amount of microleakage when compared with perforations treated with amalgam.<sup>19</sup> Studies has also revealed that perforations treated with resin modified Glass ionomer cement provides much better seal when compared with amalgam, cavite and conventional GIC.<sup>18,20</sup>

## 8. DFDB

Decalcified frozen dried bone, is one of the most biocompatible, non toxic which is easy to obtain, easy to manipulate, very much inexpensive, and can act as barrier against which filling material can be placed, and it is completely degradable while the repair process goes on. Whenever there is need to pack in the bony defect, it is mixed with the blood present and turns into a solid mass that will ultimately fill the defect.<sup>21</sup>

According to a study conducted by Hartwell et al, stated that Decalcified frozen dried bone has some of its negative points also like there is absence of new bone formation in the perforation area, when treated with Decalcified frozen dried bone along with some positive points that includes good clinical and radiographic findings at the end of six months, no formation of periodontal pocket and most

importantly no signs of inflammation.<sup>21</sup>

### 9. Calcium Hydroxide

In 1920, Bernhard W. Hermann suggested the use of calcium hydroxide for dental pulp treatment. This material favors the healing process of pulp and periapical tissue.<sup>22–27</sup> Calcium hydroxide is obtained by the calcination of calcium carbonate, which is transformed into calcium oxide, and then hydrated to form calcium hydroxide. The reaction between calcium hydroxide and carbon dioxide forms calcium carbonate. The ionic dissociation of calcium hydroxide into calcium and hydroxyl ions, and the action of these ions on tissues and bacteria explains its biological and antimicrobial properties.<sup>28</sup> It is one of the most biologically compatible material which is used in dentistry. It is very much compatible with the pulp and the periapical tissue. A study conducted by P Bogaerts et al, they used calcium hydroxide as material of choice in sealing the root perforation and found excellent clinical results with positive outcome and with no signs of inflammation.<sup>29</sup>

### 10. Mineral Trioxide Aggregate

It is one of the most commonly employed material in the field of dentistry, with its wide range of use. It was introduced by Mahmoud Torabinejad in the year 1992. It is composed of Tricalcium silicate, Tricalcium aluminate, Tricalcium oxide, Silicate oxide, calcium sulphate dihydrate, tetracalcium aluminoferrite and small amounts of mineral oxides (bismuthoxide) with a mean setting time of  $165 \pm 5$  minutes.<sup>30,31</sup> MTA results in cementum formation by stimulating cementoblasts to produce matrix which in turn results in formation of cementum at the site earlier perforated and treated with mineral trioxide aggregate. It is highly biocompatible with periapical and periradicular tissue.<sup>31</sup>

### 11. Biodentine

It is a calcium cement based bioactive material. It is a powder liquid system, powder composed of Tri-calcium silicate, Di-calcium silicate, Calcium carbonate and oxide, Iron oxide, Zirconium oxide. Liquid consist of Calcium chloride, Hydro soluble polymer. This material having some positive points like easy to handle, easy to manipulate, and very much important a short setting time of approximately 12 minutes, a biocompatible material, makes it material of choice in the repair of perforation. It showed excellent performance as a sealing material when the material is exposed to various endodontic irrigants as compared to MTA.<sup>32</sup>

### 12. Source of Funding

None.

### 13. Conflict of Interest

Authors has no conflict of interest whatsoever.

### References

- Nicholls E. Treatment of traumatic perforations of the pulp cavity. *Oral Surg, Oral Med, Oral Pathol.* 1962;15:603–11. doi:10.1016/0030-4220(62)90180-9.
- Bryan EB, Woollard G, Mitchell WC. Nonsurgical repair of furcal perforations: a literature review. *Gen Dent.* 1999;47:274–8.
- Estrela C, Pécora JD, Estrela CRA, Guedes OA, Silva BSF, Soares CJ, et al. Common Operative Procedural Errors and Clinical Factors Associated with Root Canal Treatment. *Braz Dent J.* 2017;28(2):179–90.
- Frank AL, Weine FS. Nonsurgical Therapy for the Perforative Defect of Internal Resorption. *J Am Dent Assoc.* 1973;87(4):863–8.
- Frank AL. Resorption, perforations, and fractures. *Dent Clin North Am.* 1974;18(2):465–87.
- Oswald RJ. Procedural accidents and their repair. *Dent Clin North Am.* 1979;23(4):593–616.
- Fuss Z, Trope M. Root perforations: classification and treatment choices based on prognostic factors. *Dent Traumatol.* 1996;12:255–64. doi:10.1111/j.1600-9657.1996.tb00524.x.
- Roda RS. Root perforation repair: surgical and nonsurgical management. *Pract Proced Aesthet Dent.* 2001;13(6):467–72.
- Tsesis I, Fuss Z. Diagnosis and treatment of accidental root perforations. *Endod Top.* 2006;13:95–107. doi:10.1111/j.1601-1546.2006.00213.x.
- Estrela C, Pécora JD, Estrela CRA, Guedes OA, Silva BSF, Soares CJ, et al. Common Operative Procedural Errors and Clinical Factors Associated with Root Canal Treatment. *Braz Dent J.* 2017;28(2):179–90.
- Holland R, Filho JAO, Souza V, Nery MJ, Bernabé PF, Dezan Junior E. Mineral trioxide aggregate repair of lateral root perforations. *J Endod.* 2001;27(4):281–4.
- Kakania K, Veeramachaneni C, Chandrakanth M, Tummala M, Khiyani L. A Review on Perforation Repair Materials. *J Clin Diagn Res.* 2015;9(9):ZE9–13.
- Oswald R. Procedural accidents and their repair. *Dent Clin North Am.* 1979;23:593–616.
- Aguirre R, Eldeeb ME, ElDeeb ME. Evaluation of the repair of mechanical furcation perforations using amalgam, gutta-percha, or indium foil. *J Endod.* 1986;12(6):249–56.
- Bahn SL. Plaster: a bone substitute. *Oral Surg Oral Med Oral Pathol.* 1962;21:672–81.
- Bramante CM, Berbert A. Root perforations dressed with calcium hydroxide or zinc oxide and eugenol. *J Endod.* 1987;13(8):392–5.
- Benenati FW, Roane JB, Biggs JT, Simon JH. Recall evaluation of iatrogenic root perforations repaired with amalgam and gutta-percha. *J Endod.* 1986;12(4):161–6.
- Alhadainy HA, Himel VT. Evaluation of the sealing ability of amalgam, Cavit, and glass ionomer cement in the repair of furcation perforations. *Oral Surg, Oral Med, Oral Pathol.* 1993;75(3):362–95.
- Fuss Z, Abramovitz I, Metzger Z. Sealing Furcation Perforations with Silver Glass Ionomer Cement: An In Vitro Evaluation. *J Endod.* 2000;26(8):466–8. doi:10.1097/00004770-200008000-00009.
- Alhadainy HA, Himel VT. Evaluation of the sealing ability of amalgam, Cavit, and glass ionomer cement in the repair of furcation perforations. *Oral Surg, Oral Med, Oral Pathol.* 1993;75(3):362–6.
- Hartwell GR, England MC. Healing of furcation perforations in primate teeth after repair with decalcified freeze-dried bone: A longitudinal study. *J Endod.* 1993;19(7):357–61.
- Mitchell DF, Shankwalker GB. Osteogenic Potential of Calcium Hydroxide and Other Materials in Soft Tissue and Bone Wounds. *J Dent Res.* 1958;37(6):1157–63.
- Holland R. Histochemical response of amputated pulps to calcium hydroxide. *Rev Bras Pesqui Med Biol.* 1971;4:83–95.

24. Heithersay GS. Periapical repair following conservative endodontic therapy. *Aus Dent J.* 1970;15(6):511-8.
25. Heithersay GS. Calcium Hydroxide in the Treatment of Pulpless Teeth with Associated Pathology. *Int Endod J.* 1975;8(2):74-93. doi:10.1111/j.1365-2591.1975.tb01000.x.
26. Holland R, de Mello W, Nery MJ, Bernabe PFE, d Souza V. Reaction of human periapical tissue to pulp extirpation and immediate root canal filling with calcium hydroxide. *J Endod.* 1977;3(2):63-7.
27. Holland R, Desouza V, Nery M, Bernabé F, Filho JAO, Dezan E, et al. Calcium Salts Deposition in Rat Connective Tissue After the Implantation of Calcium Hydroxide-Containing Sealers. *J Endod.* 2002;28(3):173-6.
28. Estrela C, Sydney GB, Bammann LL, Felipe Júnior O. Mechanism of action of calcium and hydroxyl ions of calcium hydroxide on tissue and bacteria. *Braz Dent J.* 1995;6(2):85-90.
29. Bogaerts P. Treatment of root perforations with calcium hydroxide and SuperEBA cement: a clinical report. *Int Endod J.* 1997;30(3):210-9.
30. Torabeinejad M, Ford TRP. Antibacterial effects of some root end filling material. *Am Assoc Endod.* 1995;21(8):403-6.
31. Keiser K, Johnson C, TIPTON D. Cytotoxicity of Mineral Trioxide Aggregate Using Human Periodontal Ligament Fibroblasts. *Am Assoc Endod.* 2000;26:288-91. doi:10.1097/00004770-200005000-00010.
32. Guner MB, Akbulut MB, Eldeniz AU. Effect of Various Endodontic Irrigants on the Push-out Bond Strength of Biodentine and Conventional Root Perforation Repair Materials. *J Endod.*

2013;39(3):380-4.

### Author biography

**Abhishek Sharma**, Senior Lecturer

**Abhishek Avasthi**, Reader

**Ramandeep Singh**, Senior Lecturer

**Neha**, Senior Lecturer

**Namita Tandon**, Senior Resident

**Atul Kumar**, Dental Surgeon (Jammu City)

**Cite this article:** Sharma A, Avasthi A, Singh R, Neha, Tandon N, Kumar A. Different materials used for repair of root perforation: A review. *IP Indian J Conserv Endod* 2020;5(4):161-164.