



Case Report

The premolar miscellany- A case series of various aberrant root canal systems

Shashin Shah¹, Aadil Thimwala^{1,*}, Mihir Pandya¹, Soham Patel¹

¹Dept. of Conservative Dentistry and Endodontics, Goenka Research Institute of Dental Science, Gandhinagar, Gujarat, India



ARTICLE INFO

Article history:

Received 17-07-2020

Accepted 08-08-2020

Available online 07-09-2020

Keywords:

Premolars

Canal negotiation

ABSTRACT

Premolars have been blessed for having an aberrant root canal anatomy. The occurrence of more than 2 canals with different portal of exit is very rare. If one is facing the scenario of treating the maxillary and mandibular premolars clinically than he must be aware of the internal anatomy of these teeth. These teeth may require special shaping and obturating techniques. This case series is the reflection of the endodontic challenges clinicians face to manage such cases. Careful examination of pre-operative radiograph and careful negotiation is necessary to deal with such variable anatomies.

© 2020 Published by Innovative Publication. This is an open access article under the CC BY-NC license (<https://creativecommons.org/licenses/by-nc/4.0/>)

1. Introduction

To achieve a successful endodontic treatment, a thorough knowledge of root and root canal morphology as well as possible variation in anatomy of the root canal system is of utmost importance. This is followed by negotiation, cleaning, shaping, and obturation of the entire root canal system in three dimensions. Failure to recognize the presence of an additional root canal may result in unsuccessful treatment and may be the origin of acute flare ups during and after treatment.

Dealing with the canal morphology of the first maxillary premolars have revealed that it has two cusps with the buccal cusp prominently larger than the palatal cusp. Morphological variations in root consist of fused roots with separate canals, fused roots with interconnections or “webbing”, fused roots with a common apical foramen and the unusual but always to be considered three- rooted tooth. In most instances they have two canals, although teeth with one or three canals do exist. Mariusz et al found 9.2% of first maxillary premolars with three canals.¹

The mandibular premolars are the most difficult teeth to treat endodontically.² This is because of the narrow cervix as compare to other teeth, and the large number

of possible variations of root canal anatomy. According to Green the highest incidence of 47% of accessory foramina was observed in mandibular second premolars.³ Rahimi et al. also reported high incidence of lateral canals that was of 38.7% and apical delta of 4.38% in mandibular second premolars.⁴

Vertucci et al. reported that the mandibular second premolar had one root canal at the apex in 97.5% and two canals in only 2.5% of the teeth; however, three root canals were scarce.⁵ Zillich and Dowson found the incidence of three canals in mandibular second premolars to be 0.4%.⁶ The clinician should be aware of these variations, their clinical and radiographic anatomy, and the location of orifices. Vertucci has classified root canal anatomy into 8 types. Sert and Bayirli in their study encountered fourteen new root canal configurations which were not included in the classification given by Vertucci or other classification systems.⁷

The purpose of these case reports is to discuss the treatment and diagnosis recommendations for an unusual occurrence of three canals in mandibular and maxillary premolars.

* Corresponding author.

E-mail address: dr.thimwala@gmail.com (A. Thimwala).

2. Case Report 1

35 years old male reported to the department of Conservative Dentistry & Endodontics, GRIDS. On careful clinical examination the condition revealed as the partial edentulous arch with upper right first molar missing, after arriving the definitive diagnosis of missing teeth intentional root canal therapy was advised as the part of the treatment planning of fixed partial denture. Preoperative radiograph of the patient was taken which showed difference of apical zone of variation (Figure 1a).

Informed consent was obtained from the patient before initiation of therapy. Root canal therapy initiated under rubber dam application after carefully administering the local anaesthesia. Access cavity preparation done using endo access bur no. # 2. 3 canals with 3 orifices negotiated by 10#k stainless steel files and working length determined using Ingle's radiographic technique (Figure 1b).

Root canals prepared using K files (NITI Flex Dentsply, Maillifer) upto 30 and obturated using cold lateral condensation technique (Figure 1c). Post operative CBCT was taken to evaluate the complete filling of the canals which shows 3 canals filled in 3 separate roots (Figure 2) (Slice taken at the apical third of the tooth). 1 year follow up of the same revealed favourable status of the periapical tissues (Figure 1d).

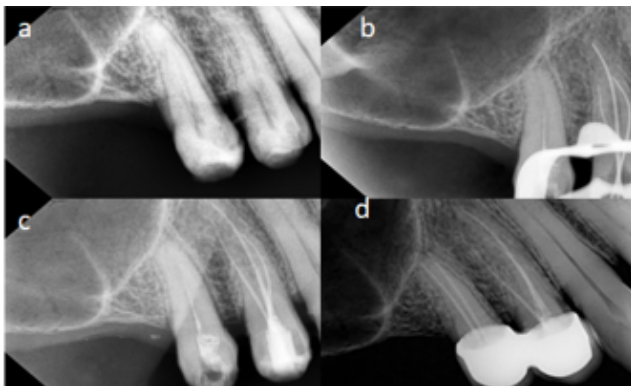

Fig. 1: a: Pre op radiograph, b: Canals 3roots, c: Obturation, d: 1 Year follow up

A 46 years male patient reported in the department of Conservative Dentistry & Endodontics, GRIDS, with the chief complain of pain in the upper left back region of the jaw. Careful clinical examination revealed the tooth having deep proximal lesion on the distal aspect with respect to the left maxillary first premolar. The tooth was tender on percussion and radiographic evaluation screened diffuse periapical radiolucency which was irregular in the outline. After taking proper history of signs and symptoms the definitive diagnosis established as the symptomatic chronic periapical abscess with respect to left maxillary first premolar.

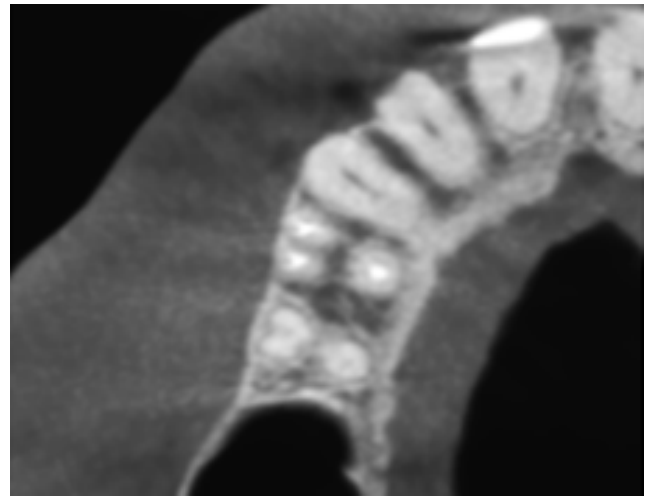


Fig. 2: Post op CBCT with three roots and three canals obturated

Root canal therapy was planned for the tooth. Root canal therapy initiated under the rubber dam application. Local anaesthesia administered. Access cavity established using endo access bur #2. After the preparation of access cavity the root canal access gained using #10K file. Initially the chamber pictured only 2 orifices with the large orifice in the buccal region (Figure 3a)

Careful filing with the precurved #6K file helped to negotiate the second buccal canal in the tooth. Working length established using #10K files using Ingle's radiographic method (Figure 3b). The existing anatomy revealed anatomical variation.

Cleaning and shaping done using step-back technique by hand files (NITI Flex Dentsply Maillifer). Shaping done till the size of 30 in all the canals. Obturation carried out using warm vertical gutta percha technique (Figure 3c)

Post obturation radiograph revealed the nice filling of 3 canals. Post obturation CBCT was taken. 3 separate canals can be appreciated in the CBCT (Figure 4) (slice taken at the middle third of the tooth).

Months follow up shows favourable healing (Figure 3d)

3. Case Report 3

33 years male patient reported to the Department of the Conservative Dentistry & Endodontics, GRIDS. Patient's chief complain was about pain in the lower right back region of the jaw. On clinical examination it has been revealed that Class 2 lesion was present mesially with respect to the lower right second premolar.

Radiographic examination showed unusual root canal anatomy with the abrupt loss of main canal which was dividing into multiple canals canal at the midroot level known as "Fast Break" appearance (Figure 5a).

With the evidence of existing symptoms the diagnosis established as the periapical abscess and root canal therapy

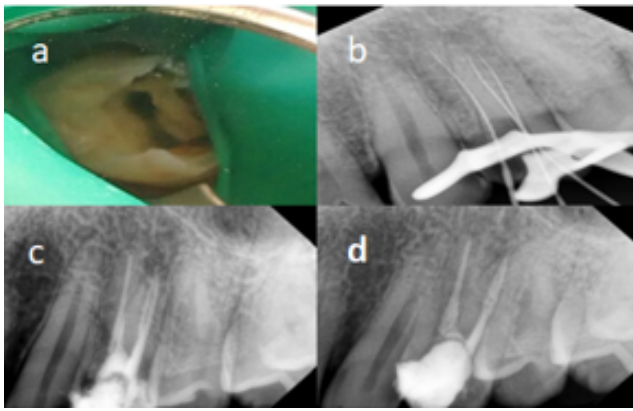


Fig. 3: a: Two orifices buccal & lingual, b: Three canals negotiated, c: Obturation, d: Three month follow up.

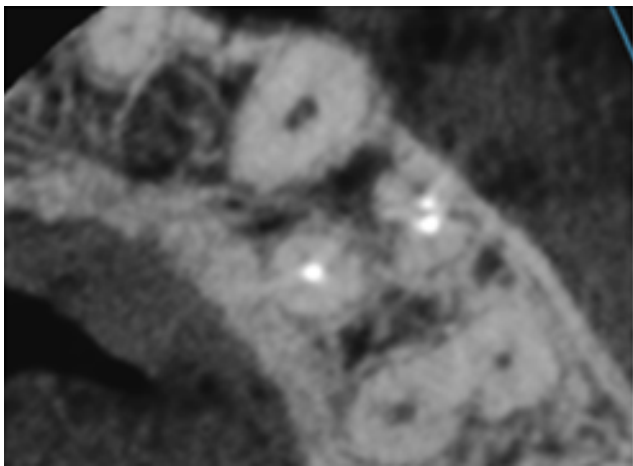


Fig. 4: Post op CBCT with fused roots and 2 buccal canals

was advised.

Root canal therapy initiated after careful administration of local anaesthesia. Upon gaining the access only single orifice was encountered (Figure 5b). Canal negotiation done using 10 K files. After some amount of efforts third canal was negotiated which was distally located using 10 K files (Figure 5c)

Cleaning and shaping done using K file (NITI Flex Dentsply Maillifer) using step back technique. Obturation done using cold lateral condensation technique (Figure 5d).

4. Case Report 4

48 years old female patient reported to the department of Conservative Dentistry and Endodontics, having complain of pain in the lower right back region. On clinical examination it has been revealed that the lower right second premolar tooth was having class 2 lesion on the distal aspect of the tooth. The tooth was tender on percussion. After

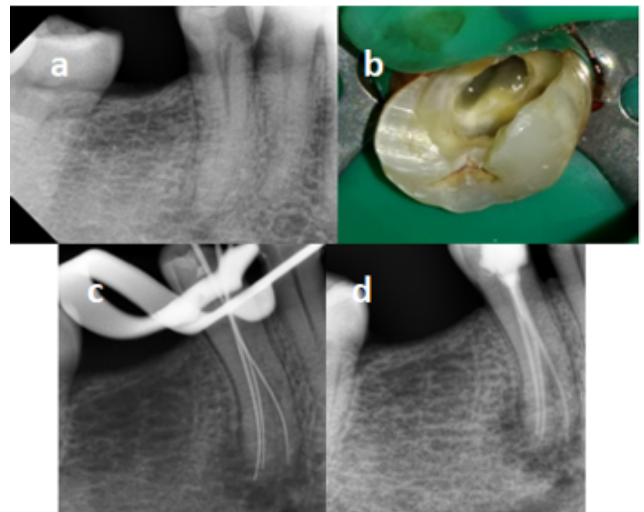


Fig. 5: a: Fast break appearance, b: single orifice, c: Third canal distally, d: Obturation

establishing the related diagnosis root canal therapy was planned for the tooth.

Access preparation done using #2 round bur. Upon access it demonstrated single opening. Tactile sensation felt very constricted canals. (Figure 6a)

Careful radiographic examination revealed presence of multiple canals. Sequential shaping done by first shaping 2 canals and then proceeding to third canal. After confirming master cone in each canal individually obturation was carried out using warm vertical compaction technique. (Figure 6b)

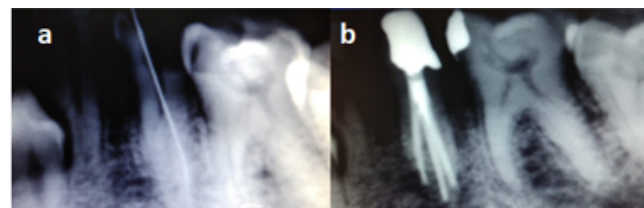


Fig. 6: a: Clinically tight canal, b: Obturated 3 canals

5. Discussion

Since 1870 the literature reveals a periodic renewal of interest in the root canal morphology of teeth in order to learn more about them or to search for different ways in which to improve endodontic techniques and ultimately success.⁸ The process of identifying and accessing root canals is particularly challenging in endodontic treatment of a tooth with atypical canal configuration.

Many investigators have worked on tooth morphology, topography, curvature, ramifications of the main root canal, diameters, localization and number of foramina and apical

deltas by using different methods.⁹ The maxillary first premolar has a highly variable canal and root morphology, frequently with separate canals and two foramina 72%.¹⁰ For a successful root canal treatment, it is essential to identify, clean and shape the root canal properly before placing a hermetic filling. The presence of an untreated canal inadequate debridement and incomplete obturation of the root canal system are common reasons for failure of endodontic treatment. Root canal orifices are the number one guide in determining the outline form of the access cavity. In the maxillary first premolar an ovoid outline form is recommended. No technological advances or innovations can fully compensate for a lack of understanding of the anatomical features of the pulp chamber, which along with the root canal space are always located in the cross sectional centre of the crown and root respectively.

The complex nature of root canal morphology of mandibular second premolar is always amazing in its unique ability of representing itself with some eye catching features. Underestimating the anatomy of this tooth can end up both the patient and the clinician with the failed treatment despite of fair attempts. Good quality radiographs taken at two different horizontal angulations are very helpful in providing clues about the number of root canals a tooth can have. The root canals may not be evident radiographically. There may be a sudden narrowing of the canal space as it divides further.¹¹

An abrupt loss of main canal always have this configuration of dividing into multiple canals. An optimum access cavity is absolutely necessary. Smaller K files are initially used as they get deviated buccally or lingually as the main canal divides at the midroot level. So a good tactile sense is important and the files can be precurved appropriately before negotiating the canals. Efforts should be made to locate the point where the root or the root canals divide.

Precurving the file at the apical third is the most important step in negotiations of such anatomies. Careful advancement of the precurved file and use of chelating agent is advised to refrain the clinician from the file separation.

In cases where aberrant root anatomy is evident radiographically and there are chances of finding additional canals the use of magnification and fiberoptic illumination becomes very important in locating and treating these additional canals. Recently, we can also take the help of microscope and dental CT scanning for better treatment of such anatomical complexity.⁸

6. Conclusion

Knowledge of the existence of these variation is important for both diagnostic and treatment standpoints. Thus it is essential to highlight the need to look for unusual morphology and additional roots and root canals so as to achieve a good endodontic outcome.

Over the past two decades, there have been a plethora of published in vitro studies and case reports depicting a

variety of canals configurations. It was seen that gender, race and ethnic origin all play role in determining the canal morphology and hence should be considered during the preoperative evaluation stage of root canal therapy.¹²

A periapical radiograph of the contra lateral side also showed more than one root canals in mandibular and maxillary premolar. Further study for the same is suggested.

7. Source of Funding

None.

8. Conflict of Interest

None.

References

1. Mariusz L, Krysof W, Ryta L, Mangorzata T. Root canal morphology of the first human maxillary premolar. *Durh Anthro J*. 2005;12:2-3.
2. Slowey RR. Root canal anatomy. Road map to successful endodontics. *Dent Clin North Am*. 1979;23:555-73.
3. Green D. Stereomicroscopic study of 700 root apices of maxillary and mandibular posterior teeth. *Oral Surg Oral Med Oral Pathol*. 1960;13:728-33.
4. Rahimi. A stereomicroscopy study of root apices of human maxillary central incisors and mandibular second premolars in an Iranian population. *J Oral Sci*. 2009;51(3):411-5.
5. Vertucci FJ. Root canal morphology of mandibular premolars. *J Am Dent Assoc*. 1978;97(1):47-50.
6. Zillich R, Dowson J. Root canal morphology of mandibular first and second premolars. *Oral Surg, Oral Med, Oral Pathol*. 1973;36(5):738-4.
7. Sert S, Bayirli G. Evaluation of the Root Canal Configurations of the Mandibular and Maxillary Permanent Teeth by Gender in the Turkish Population. *J Endod*. 2004;30(6):391-8.
8. Shah. Mandibular second premolar with two roots and two canals. *BUJOD*. 2014;4:77-81.
9. Pineda F, Kutler Y. Mesiodistal and Buccolingual roentgenographic investigation of 7275 root canals. *Oral Surg Oral Med Oral Pathol*. 1972;33:101-10.
10. Carns EJ, Skidmore AE. Configurations and deviations of root canals of maxillary first premolars. *Oral Surg, Oral Med, Oral Pathol*. 1973;36(6):880-6.
11. Slowey RR. Root canal anatomy. Road map to successful endodontics. *Dent Clin North Am*. 1979;23:555-73.
12. Vertucci FJ. Root canal morphology and its relationship to endodontic procedures. *Endod Top*. 2005;10(1):3-29.

Author biography

Shashin Shah HOD

Aadil Thimwala Post Graduate Student

Mihir Pandya Reader

Soham Patel Reader

Cite this article: Shah S, Thimwala A, Pandya M, Patel S. **The premolar miscellany- A case series of various aberrant root canal systems.** *IP Indian J Conserv Endod* 2020;5(3):127-130.