



Case Report

Radisection: an interdisciplinary approach for successful outcome

Nikita kapshe^{1,*}, Nikita Bhosale¹, Hemant Vagarali, Madhu Pujar¹, Sachin², Pallavi Gopashetti¹, Satyam Jaiswal¹

¹Dept. of Conservative and Endodontics, Maratha Mandal Dental College, Belgaum, Karnataka, India

²Dept. of Periodontics, Maratha Mandal Dental College, Belgaum, Karnataka, India



ARTICLE INFO

Article history:

Received 04-05-2020

Accepted 07-05-2020

Available online 25-05-2020

Keywords:

With its crown portion on the other

ABSTRACT

Compromised teeth are challenging to the dentist which complicate the treatment plan which affects the long-term prognosis. Maxillary molars showing untreatable endodontic failure, periodontal attachment loss, extensive carious involvement or fractures involving the furcation area are often difficult to manage. Treatment option for such multi-rooted teeth can be root resection, or extraction and prosthetic replacement. Root resection procedure offers an economically viable treatment option for the patients to preserve the natural tooth.

This article highlights 2 case reports of root resection in maxillary molar with different etiologies combined with the periodontal approach and prosthetic management with resultant successful oral rehabilitation.

© 2020 Published by Innovative Publication. This is an open access article under the CC BY-NC-ND license (<https://creativecommons.org/licenses/by/4.0/>)

1. Introduction

Root resection is a process for conserving a part of an ailing molar by elimination of one or more of its roots¹This process has been carried out in dental practice since the late 1800s.²

In the mandibular molars, root resection can be achieved by hemi sectioning the complete tooth into half and removing the injured root in conjunction with its crown portion. On the other side, in maxillary molars root resection is carried out by deletion of the diseased root only i.e.root amputation, with only rounding of the crown portion.¹

Resection of root can be advised because of multiple etiologies.

The literature mentions most commonly carried out resection procedures with mesiobuccal root in maxillary molars yet resection with palatal root becomes obligatory when the etiology is associated with that root and remains unresolved.

This case series presents root resections carried out with palatal and mesiobuccal root of maxillary molars owing to different etiologies.

2. Case 1

An old ,male patient aged 49 years old reported to our Department of Conservative dentistry and Endodontics with the chief complaint of excess pain and swelling in upper left back tooth region since 1 month which was associated with pus discharge and discomfort on chewing. Clinical examination revealed missing 26 and metal crown with respect to 27. Grade I Mobility and Grade III involvement of Furcation was present with 27 along with 15mm of pocket with the mid palatal surface. Also a sinus tract tracing lead to infection associated with palatal root of 27 [Figure 1c]. Radiographic examination revealed incomplete radio-opacity associated with all the root canals indicating improperly obturated tooth along with marked radio-opacity present in the apical third of the mesiobuccal canal which indicated file fracture as well as associated periapical lesion with all the roots.[Figure 1a]Considering the clinical and radiographic evidence a final diagnosis

* Corresponding author.

E-mail address: satyamj305@gmail.com (N. kapshe).

of primary endodontic and secondary periodontic lesion with 27 was given. During an attempt to re treat 27 another file separation took place at the apical third of palatal canal which on attempt to retrieve, resulted in file extrusion in to the periapical area[Figure 1b]. Therefore a revised treatment plan which included root resection of palatal root of 27 along with flap surgery followed by fixed partial denture from 25-27 was made. Root canal treatment was completed with the remaining roots followed by Phase I periodontal therapy[Figure 1d]. Following premedication and disinfection protocols 2% lignocaine hydrochloride (Lignox 2%, Indoco-Remedies Ltd., India) was administered. Full thickness mucoperiosteal flap was raised and a huge bony defect was seen surrounding the palatal root of 27[Figure 1e]. Curettage of the inflamed granulation tissue was carried out. With the high speed tapered fissure carbide bur directed at 90 degree to the long axis of the palatal root, approximately 7mm of the root end inclusive of the fractured file of approximately 4mm was resected. The sectioned area was evaluated, trimmed and filled with GIC (Fuji IX, GC, Europe)[Figure 1f,g]. The combination of Platelet Rich Fibrin and Decalcified Freeze Dried Bone Allograft was placed into the bony defect of 27 and the flap was approximated with simple interrupted sutures[fig h]and zinc oxide eugenol pack was given . After follow up for 1 month, patient was asymptomatic and radiograph revealed satisfactory periapical healing with decreased mobility. Hence a metal FPD was placed with 25-27[Figure 1k]. 12 months follow up radiograph revealed sound periapical structures with no clinical symptoms and sound prosthetic function.

3. Case 2

An old patient aged 57 year reported to our Department of Endodontics, with the principal complaint of severe and throbbing pain and also food lodgement in upper left posterior tooth region since last 2-3 months. Patient gave a history of pain due to food lodgement which was severe ,irregular and throbbing in nature with respect to the maxillary first molar (26). The patient's medical history was of no relevance. Intra oral examination of 26 had revealed generalized moderate periodontal pockets with no tooth mobility. On examination radiographically, periapical radiographs, revealed radiolucency on the mesioproximal aspect of 26 involving pulpal space, approaching furcation and extending on mesial root surface subgingivally[Figure 2 a]. Therefore depending upon clinical and radiographic evaluation it was found that the mesiobuccal root was non restorable and as palatal and distobuccal root showed adequate bone support and tooth had no mobility the treatment was decided as endodontic therapy followed by resection of mesio buccal root, retaining the disto buccal and palatal root. Treatment protocol and postoperative effects were explained thoroughly to the patient. A well informed

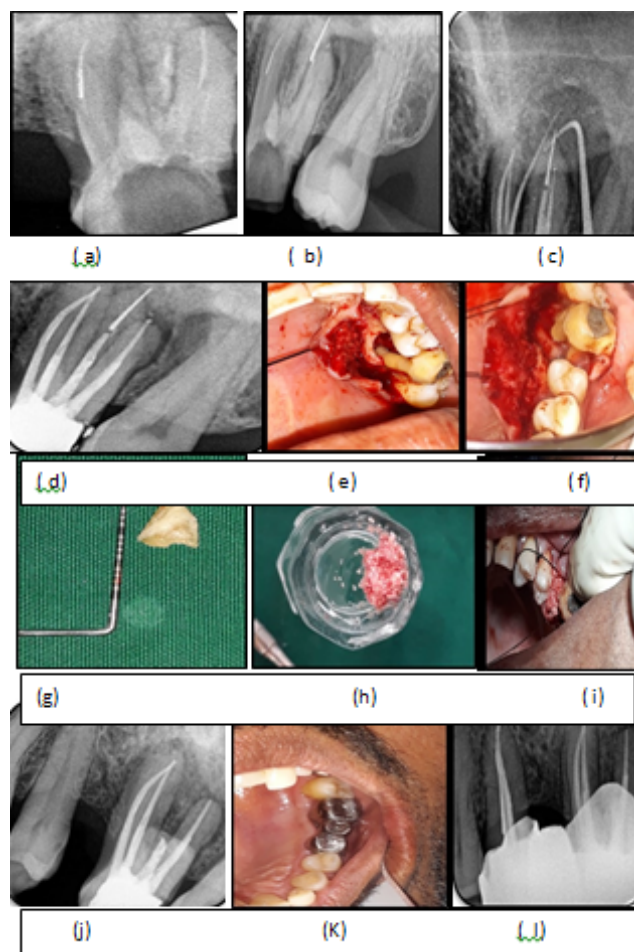


Fig. 1: a) preoperative radiograph.(b)file separation with palatal root (c). sinus tracing (d). obturation (e) flap reflection and debridement.(f) after root resection.(g) amputated root with file(h) DMBM+PRF(i) sticky bone.(j)after 3 months (k)crown placement.(l)after 18 months.

written consent was filled up and taken from patient and the patient was scheduled for a ensuing appointment. To commence with, a thorough phase I therapy was carried out and the surrounding tissue was assessed. Access opening was carried out and the endodontic treatment accomplished. Following premedication and disinfection protocols local anaesthesia was administered. A full-thickness mucoperiosteal flap was raised and the roots were exposed by removing a small amount of facial bone in order to assist root removal[Figure 2 b,c]. A nick was made with a high-speed, tapered fissure carbide bur directed just apically to the cemento enamel junction of the tooth. The mesiobuccal root piece was extracted from the socket, and furcation area was trimmed for removal of any bony spicules [Figure 2d].Subgingival caries excavation was done from the remaining portion of the tooth followed by restoration and sealing of the pulp chamber at the furcation area was done using Glass ionomer cement [Figure 2e]. Then root

planning was done for remaining roots and the socket was thoroughly irrigated with saline and the tooth was checked for a proper occlusion. The flap was repositioned into place and secured using 3-0 monofilament suture. The patient was given post-operative instructions and medications. Sutures were then removed after 7 days and healing was found to be satisfactory. The patient was recalled periodically and evaluated for prognosis.

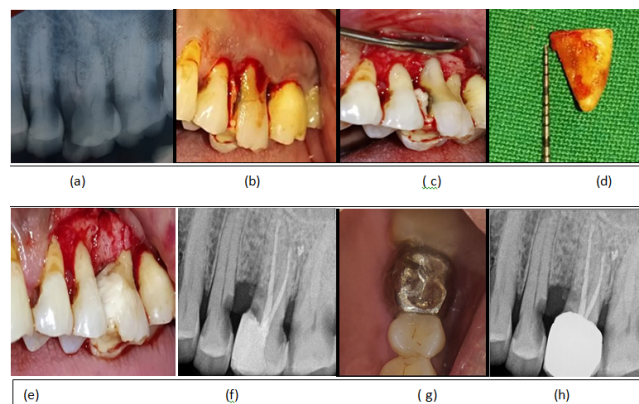


Fig. 2: (a) preoperative radiograph.(b)incisions placed.(c)subgingival caries location.(d) resected root piece.(e)ging restoration done.(f)one month follow up.(g)crown placement.(h)six months follow up.

4. Discussion

The upsurge want of the patients to preserve the dentition has enforced the dentists to save the teeth which are indicated for extraction. Tooth resection means the sectioning and removal of the tooth fragment or a root with or without crown portion.³

This procedure is a reasonable method which involves removal of a weakened, diseased root structure while conserving the stronger one, which if preserved together, would collectively fail.⁴

Root resection technique is used in the management of multirrooted teeth with multifaceted Grade II and Grade III furcation involvement ,subgingival caries extending on the root surface which are nonrestorable, file separation beyond apex and horizontal fracture or external root resorption associated with single root.

When the tooth in question is of a great strategic worth or when the complications cannot be corrected by therapeutic methods for such situations .Minsk and polson have suggested that root resection can be a priceless approach. Teeth in close proximity to anatomic landmarks such as inferior alveolar canal and maxillary sinus can be treated carefully by root resection procedure.⁵

Root resection requires a Multidisciplinary advancement which starts with endodontic treatment followed by periodontal surgery, a prosthetic reconstruction, and maintenance of oral hygiene leading to a triumphant

treatment outcome. Choice of the roots to be amputated, occlusal and endodontic considerations are significant factors which should be taken into account prior to deciding to start any of the resection procedures.⁶

This case report demonstrates a successful management of a retreatment case with a persistent periapical lesion secondary to an iatrogenic procedural error of file separation which made the elimination of bacteria from the canal difficult. Whereas the second case showed non restorable root caries on the mesial aspect of maxillary molar approaching furcation which was managed by resection. Root resection offered better results extending the lifespan of tooth.⁷

Babay& Almas (1996) have reported a 4-year survival rate of 93% in maxillary molars post root amputation and long-term survival of teeth after root amputation ranged from 87% to 95% (Buhler 1994, Hemptom& Leone 1997).⁸

The limitations of these procedures are pain and anxiety of surgical procedure, vulnerability of the root surface area to caries, progressive periodontal destruction and trauma from occlusion due to improper prosthetic design.⁶

5. Conclusion

Root resection is an economically feasible treatment plan equivalent to implant rehabilitation. Proper exhibition of this procedure leads to a successful and long-lasting outcome .

6. Source of Funding

None.

7. Conflict of Interest

None.

References

1. Aqrabawi J. Root Amputation: A Prudent Alternative to Tooth Extraction. *Adv Dent Oral Health*. 2016;2(2).
2. Nabhi K, Mehra P, Sharma B. Root Resection of Maxillary First Molar: A Case Report. *IOSR J Dent Med Sci*. 2017;16(4):103–7.
3. Javali MA, Safeena AH. Root resection of maxillary first molar: a case report. . *Heal talk*. 2012;4:20–1.
4. Choudhary A, Choudhary E. Management of Root Amputated Maxillary Molar Teeth: Endodontic And Prosthetic Considerations-A Case Report. *J Oral Health Res*. 2011;2(1):42.
5. Park SY, Shin SY, Yang SM, Kye SB. Factors influencing the outcome of root-resection therapy in molars: A 10-year retrospective study. . *J Periodonto*. 2009;80:32–40.
6. Rajesh H, Dharamsi A, Rajesh KS, Hegde S. Root resection: Apropos of 6 cases. *Arch Med Health Sci*. 2014;2:209.
7. Kahler B. Microsurgical endodontic retreatment of a maxillary molar with a separated file: a case report. *Aust Dent J*. 2011;56:76–81. Available from: <https://dx.doi.org/10.1111/j.1834-7819.2010.01281.x>.
8. Lin CC, Tsai YL, Li UM, Chang YC, Lin CP, Jeng JH. Horizontal/oblique root fractures in the palatal root of maxillary molars with associated periodontal destruction: case reports. *Int Endod J*. 2008;41(5):442–7.

Author biography

Nikita kapshe Post Graduate

Nikita Bhosale Post Graduate

Hemant Vagarali Professor

Madhu Pujar Professor and HOD

Sachin Professor

Pallavi Gopashetti Reader

Satyam Jaiswal Post Graduate

Cite this article: kapshe N, Bhosale N, Vagarali H, Pujar M, Sachin , Gopashetti P, Jaiswal S. **Radisection: an interdisciplinary approach for successful outcome.** *IP Indian J Conserv Endod* 2020;5(2):88-91.