



## Case Report

# Rehabilitation of mandibular defect with sectional cast partial denture with salivary reservoir using semi precision attachments: A case report

Mahesh Eraiah Gowda<sup>1,\*</sup>, Kirandeep Singh<sup>2</sup>, Rahul Bahri<sup>2</sup>, Nanda Kishore Sahoo<sup>3</sup>

<sup>1</sup>Dept. of Prosthodontics and Crown & Bridge, Command Military Dental Centre, Pune, Maharashtra, India

<sup>2</sup>Dept. of Dental Surgery and Oral Health Sciences, Armed Forces Medical College, Pune, Maharashtra, India

<sup>3</sup>Dept. of Oral and Maxillofacial Surgery, Command Military Dental Centre, Pune, Maharashtra, India



## ARTICLE INFO

### Article history:

Received 04-10-2020

Accepted 19-11-2020

Available online 02-12-2020

### Keywords:

Mandibular defect

Xerostomia

Salivary reservoir

Semi precision attachments

Cast partial denture

## ABSTRACT

**Introduction:** Tumors involving mandible are the most common cause of mandibulectomy due to their aggressive nature. Mandibulectomy is generally combined with adjunct treatment modalities like radiotherapy and chemotherapy to avoid high chances of recurrence. Many case reports of rehabilitation of mandibulectomy defects using poly methyl meth acrylate have been reported in the literature, but rehabilitation with cast partial denture along with salivary reservoir is scarce/ not reported.

The patient chief complaint was difficulty in chewing food and dryness of mouth. Intra oral examination revealed missing alveolar ridge with corresponding teeth following mandibulectomy along with dryness of mouth. The contralateral side had good occlusion with no deviation of the mandible on opening or closing. Following the surgery, for Chondrosarcoma, patient had reported to our department for rehabilitation. The mandibulectomy defect was Cantor and Curtis Type III defect with xerostomia.

**Conclusion:** The hemi mandibulectomy defect was rehabilitated with sectional cast partial denture using semi precision attachments along with salivary reservoir to improve form, function, esthetics and phonetics including clinical symptom of xerostomia, thereby improving quality of life of the patient.

© This is an open access article distributed under the terms of the Creative Commons Attribution License (<https://creativecommons.org/licenses/by/4.0/>) which permits unrestricted use, distribution, and reproduction in any medium, provided the original author and source are credited.

## 1. Introduction

Prosthodontic rehabilitation of residual mandibular defect following mandibulectomy is a challenge for prosthodontist to restore form, function, esthetics and phonetics. Mandibulectomy following tumor resection have high rates of recurrence and are treated with combined adjunct treatment modality.

Radiotherapy to head and neck have complications like xerostomia, mucositis, cervical dental caries, loss of taste sensations and osteoradionecrosis.<sup>1</sup> Patients having xerostomia complains of difficulty in speaking, swallowing and mastication.<sup>2</sup> It is the responsibility of the prosthodontist to rehabilitate patient to as near as normal.

This article highlights the rehabilitation of Class III mandibular defect created after surgical resection, with split cast partial denture incorporating salivary reservoir utilizing semi precision attachments.

## 2. Case Report

A 69 year old female reported with complaint of inability to chew food and difficulty in swallowing due to dry mouth since a year. History revealed patient underwent Right (Rt) hemimandibulectomy due to chondrosarcoma of mandible Rt side with PMMC (Pectoralis Major Myocutaneous) flap reconstruction, followed with radiation therapy 18 months ago.

Clinical examination revealed gross facial asymmetry on Rt side. Intra oral examination revealed missing alveolar ridge with scar in region of mandibular right central and lateral incisor teeth (Figure 1). Although mandibular

\* Corresponding author.

E-mail address: [gowdadent@outlook.com](mailto:gowdadent@outlook.com) (M. E. Gowda).

deviation is a common feature, this patient presented no deviation towards contralateral side with maximum intercuspation occlusion on the non resected side.

Radiographic examination revealed loss of mandibular continuity on Rt side with presence of only condylar and coronoid process on Rt side. It also revealed submerged non infected root stump of mandibular left central incisor (Figure 2).

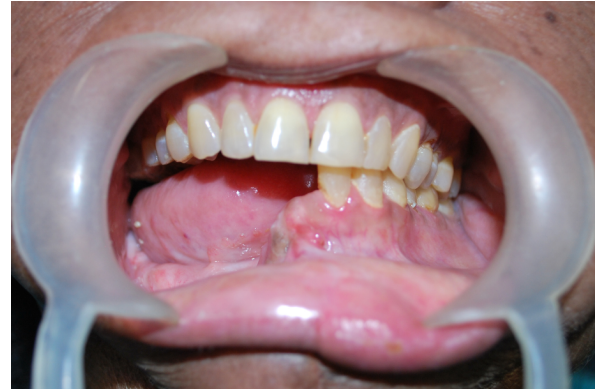The non infected root stump, was not extracted, to avoid further trauma to irradiated tissue. Patient was initially rehabilitated with two piece acrylic prosthesis with magnet retained salivary reservoir. The patient complained of difficulty in phonation along with lack of thermal perception. Patient also complained of discoloration, loose and bulky prosthesis. Hence it was decided to rehabilitate defect with two piece cast partial denture incorporating salivary reservoir using semi precision attachments.

Diagnostic impressions were made using irreversible hydrocolloid impression material (Zelgan; Dentsply) and casts were fabricated using Type III dental stone (Kalabahi; Kalstone). Surveying done on diagnostic mounting and mouth preparation carried out. Final impression was made using two step impression technique with putty and light body addition silicon elastomeric impression material (Coltene; Affinis). Surveying was re-done after retrieving the secondary cast. After block out, refractory cast was retrieved; wax pattern along with salivary reservoir of approx 2.5 ml was fabricated. The male components of semi precision attachment (CEKA; Preci-Ball) were attached to wax pattern in front and behind the reservoir using surveyor (Figure 3). Investing and casting was carried out as per standard prosthodontic protocols. The lid of the reservoir including the female components was fabricated in relation with male component. Casting was done again to fabricate second piece of the prosthesis. After metal framework try, border moulding was done using green stick impression compound (DPI; Pinnacle Tracing Sticks) and final impression was made using light body consistency of addition silicone impression material (Coltene; Affinis). Final cast was retrieved using altered cast technique (Figure 4).

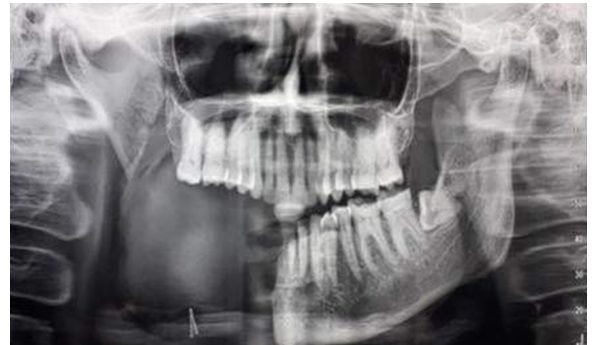Occlusal rims were fabricated on the lid of the reservoir. Jaw relations were recorded. Teeth arrangement and try-in were carried out. Prosthesis was acrylized using heat cure acrylic resin (DPI; Heat Cure Denture Base Material) (Figure 5). Final fit of male and female component of semi precision attachment was checked and silicone rings placed in female component. Two holes were made within lingual wall of salivary reservoir using 0.5mm bur to allow flow of artificial saliva (Figure 6).

The intaglio surface of the prosthesis was relined with soft liner (GC; Reline Soft) for additional comfort since there was no bony mandibular continuity (Figure 7). Prior to insertion fluoride application was done as prophylactic

measure for prevention of dental caries. Finished and polished cast partial prosthesis was delivered to the patient along with prescription of carboxy methyl cellulose (Wet Mouth, ICPA) salivary substitute (Figure 8). Patient was trained to fill salivary reservoir with salivary substitute before every meal as per comfort. Post insertion instructions were given to the patient.



**Fig. 1:** Pre operative defect

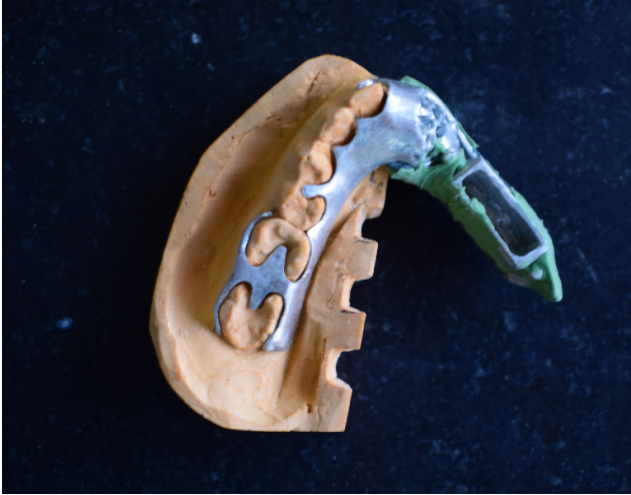


**Fig. 2:** OPG showing mandibular defect

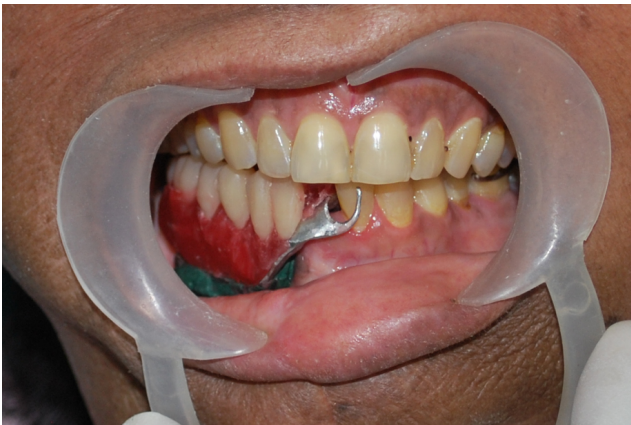

**Fig. 3:** Semi Precision Attachment

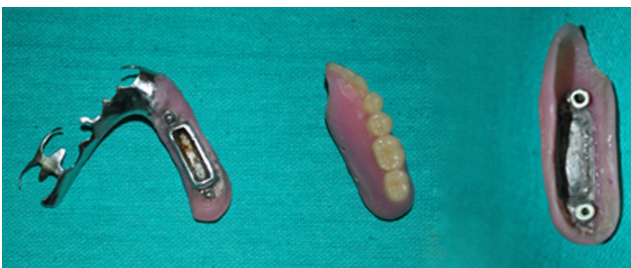



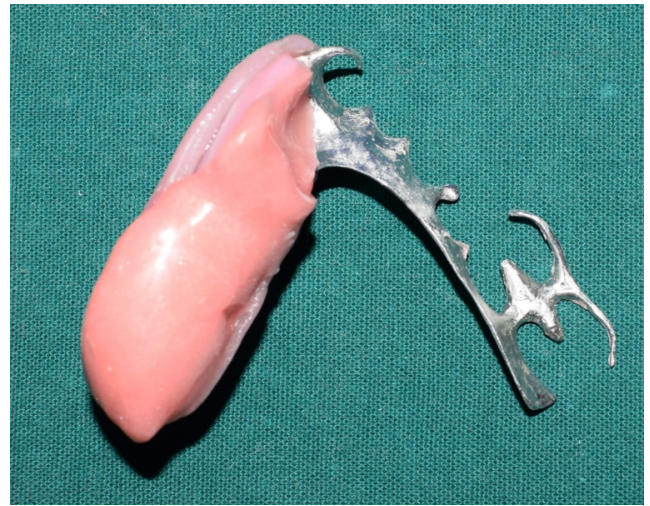
**Fig. 4:** Altered cast technique



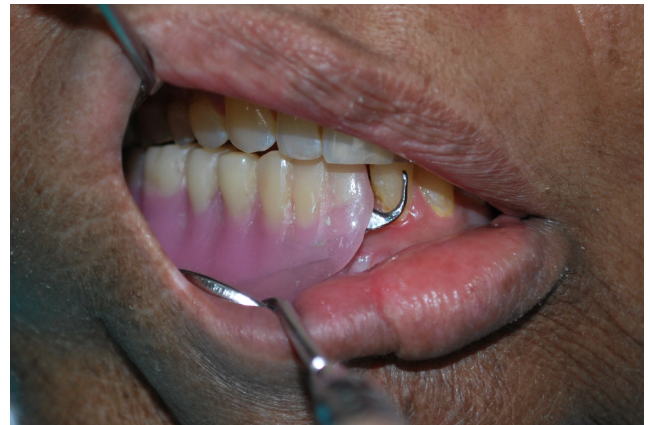**Fig. 5:** Try-in



**Fig. 6:** Finished prosthesis



**Fig. 7:** Intaglio Surface with soft liner



**Fig. 8:** Prosthesis In situ

### 3. Discussion

Rehabilitation of mandibular defect with salivary reservoir not only restores the form and function but also provides an advantage of reducing xerostomia.<sup>3</sup> Normal salivary flow in a healthy individual is 0.5-1.5 lts/day with a flow rate of 1-2 ml/min and salivary flow rate less than 0.1ml/min is diagnosed as Xerostomia.<sup>4</sup>

Radiotherapy leads to reduction in salivary flow rates to less than 0.1ml/min.<sup>5</sup> Among patients with radiotherapy, symptomatic treatment with commercially available salivary substitutes containing carboxy methyl cellulose, biotene and mucopolysaccherides are the only option available.<sup>6</sup>

Incorporation of salivary reservoir within the denture is known treatment modality and various fabrication techniques are available.<sup>7</sup> Prosthesis with incorporated salivary reservoir are generally fabricated in two pieces. Insufficient space due to mandibular deviation make prosthesis weak and prone to fracture.<sup>8</sup> Since there was no

deviation of mandible and adequate restorative space with maximum intercuspation was available, cast partial salivary reservoir was planned.

The advantages of using base metal alloys for fabrication of partial denture are their light weight, ability to transmit stimuli to the mucosa and better tissue acceptance. Also, the metal surface exhibit significantly less growth of candida when compared to acrylic resins due to high finish and non porous nature.<sup>9</sup>

The semi precision attachment were used to hold two pieces instead of magnets, since magnets are prone to corrosion.<sup>10</sup> Sustained release of saliva can be achieved with 0.2 mm hole in lingual wall of salivary reservoir by negative pressure in the oral cavity during swallowing. The prosthesis was lined with silicon liner in order to have better stability and tissue acceptability. The reservoir is cleaned daily by flushing water and with disinfectant solution.<sup>7</sup> Frequent recall visit is required to ensure patency of holes in the reservoir and to rule out any irritation to underlying mucosa.

#### 4. Conclusion

Prosthodontic rehabilitation of mandibulectomy patients with split cast partial denture improves the patient's function, esthetics and phonetics. Incorporation of salivary reservoir will provide an additional advantage of treating radiation induced xerostomia. Salivary substitutes not only improve the mastication and deglutition, aids in retention of denture in the oral cavity, along with feel good factor for the patient.

#### 5. Source of Funding

No financial support was received for the work within this manuscript.

#### 6. Conflict of Interest

The authors declare they have no conflict of interest.

#### References

1. Tribius S, Sommer J, Cet P. Xerostomia after radiotherapy. *Strahlentherapie und Onkologie*. 2013;189:216–22.
2. Humphrey SP, Williamson RT. A review of saliva: Normal composition, flow, and function. *J Prosthetic Dent*. 2001;85(2):162–9. doi:10.1067/mp.2001.113778.
3. Sinclair GF, Frost PM, Walter JD. New design for an artificial saliva reservoir for the mandibular complete denture. *J Prosthetic Dent*. 1996;75(3):276–80. doi:10.1016/s0022-3913(96)90484-9.
4. Iorgulescu G. Saliva between normal and pathological. Important factors in determining systemic and oral health. *J Med life*. 2009;2:303.
5. Franzén L, Funegard U, Ericson T, Henriksson R. Parotid gland function during and following radiotherapy of malignancies in the head and neck: A consecutive study of salivary flow and patient discomfort. *Eur J Cancer*. 1992;28:457–62.
6. Porter SR, Scully C, Hegarty AM. An update of the etiology and management of xerostomia. *Oral Surg, Oral Med, Oral Pathol, Oral Radiol, Endodontol*. 2004;97(1):28–46. doi:10.1016/j.tripleo.2003.07.010.
7. Arora V, Kumar D, Legha VS. Management of Xerostomia Patient with Salivary Reservoir Designed in Upper Complete Denture and Lower Cast Partial Denture. *J Contemp Dent*. 2014;4(1):56–9. doi:10.5005/jp-journals-10031-1069.
8. Gary FS, Peter MF, John W. D: A new design for an artificial saliva reservoir in mandibular complete denture. *J Prosthet Dent*. 1996;75:276–80.
9. Pryor WJ. J: Swaged denture bases. *J Am Dent Assoc*. 1928;15:1281–8.
10. Bhat VS, Shenoy KK, Premkumar P. Magnets in dentistry. *Arch Med Health Sci*. 2013;1(1):73–9.

#### Author biography

**Maresh Eraiah Gowda**, Professor

**Kirandeep Singh**, Resident

**Rahul Bahri**, Resident

**Nanda Kishore Sahoo**, Professor

**Cite this article:** Gowda ME, Singh K, Bahri R, Sahoo NK. Rehabilitation of mandibular defect with sectional cast partial denture with salivary reservoir using semi precision attachments: A case report. *IP Ann Prosthodont Restor Dent* 2020;6(4):216-219.