



## Review Article

## Corona virus disease COVID-19 and dentistry

Nitin Sharma<sup>1,\*</sup>, Archana Nagpal<sup>2</sup>, Tarush Thakur<sup>3</sup>, Aprajita Dogra<sup>3</sup><sup>1</sup>Dept. of Oral Health Sciences, Netaji Subhash Chandra Bose Zonal Hospital, Mandi, Himachal Pradesh, India<sup>2</sup>Dept. of Prosthodontics, Himachal Dental College, Sundar Nagar, Himachal Pradesh, India<sup>3</sup>Arch Dental Hospital 272/13, Sauli Khad, Mandi, Himachal Pradesh, India

## ARTICLE INFO

## Article history:

Received 19-08-2020

Accepted 22-08-2020

Available online 24-09-2020

## Keywords:

Coronavirus disease 2019

Dental emergency procedures

Infection

Severe acute respiratory syndrome2

Teledentistry

Transmission

## ABSTRACT

The COVID-19 coronavirus as infectious disease was established as pandemic by World Health Organization on 11<sup>th</sup> march 2020. The various hospitals and dental clinics were closed due to lockdown in various countries of the world resulted in depriving of dental care to the patients as only emergency services were provided during this phase. There was lack of universal guidelines to be followed as standard operating protocols in the initial phase which enhanced the risk of nosocomial novel CoV-19 infection to the patients and dental staff. In this review article the main emphasis are laid on the assimilation of the standard guidelines to be followed by every dental health professional for prevention of nosocomial COVID-19 transmission and proper management of patients in this phase of COVID-19 pandemic.

© 2020 Published by Innovative Publication. This is an open access article under the CC BY-NC license (<https://creativecommons.org/licenses/by-nc/4.0/>)

## 1. Introduction

The various epidemics occurred in past like H1N1, influenza, Ebola, SARS, Nipha and Zika had influenced the world with greater intensity were handled efficiently by the cautious scientific approaches.<sup>1</sup> On the day of 8<sup>th</sup> January, 2020 the official declaration of novel corona virus was made as COVID-19 by Center for Disease Control and prevention of China.<sup>2</sup> On the day of 30<sup>th</sup> January 2020 worldwide transmission of corona virus was reported by World Health Organization (WHO) as situation of emergency related to public health.<sup>3</sup> Previously corona virus was termed 2019-nCov on official basis as severe acute respiratory syndrome coronavirus-2 (SARS-CoV-2). On the day of 26<sup>th</sup> February 2020, COVID-19 was established within 34 countries world over along with 80,239 confirmed infected cases and death toll upto 2700.<sup>4</sup>

The word over spread of this corona virus has posed the greater threat of spread among the oral health professionals

and patients with higher risk of contracting infection or carrying disease in the community. As per the regulations of 'occupational safety and health administration' (OSHA), all dental professionals are categorized in category of very-high risk exposure due to their operational field as oral cavity.<sup>5</sup>

The most of the dental procedures are aerosol generating as they involve use of rotary hand piece and ultra sonic scalers so the thorough research should to be carried out for the knowledge of transmission of corona virus, clinical characteristic and testing modalities. This article is mainly based upon the researches to be followed for the regulations and recommendations included in the protocol by the dental professionals for preventing spread of corona virus to themselves and their patients.

## 1.1. Etiology of COVID-19

As mentioned in latest studies, related to SARS-CoV and 'Middle east respiratory syndrome coronavirus' (MERS-CoV), SARS-CoV-2 type is zoonotic virus with Chinese Horseshoe Bats (*Rhinolophus sinicus*) with most probably origin from Pangolins as the preferable intermediate host.<sup>6,7</sup>

\* Corresponding author.

E-mail address: [niti.sharma.ns80@gmail.com](mailto:niti.sharma.ns80@gmail.com) (N. Sharma).

## 1.2. Structural composition

The SARS-CoV-2 is 7<sup>th</sup> member in coronaviruses group, which infect human beings with similarity to betacoronaviruses, still different from ‘SARS-CoV’ and ‘MERS CoV’. This virus belong to subgenus sarbe-covirus, Orthocoronavirinae subfamily, with Chinese horse-shoe bats as common origin.<sup>8</sup> The 2019-nCoV consist of specific structure along with spiked protein in the outer membrane and also possess other components such as polyproteins, nucleoproteins, 3-chymotrypsin protease, RNA polymerase, helicase, protease similar to papain and other accessory proteins.<sup>8–10</sup> The binding of corona to host cells receptors is mediated by the S protein.<sup>11,12</sup> The 4 different amino acid are present in 2019-n Co Vans SARS CoV, whereas 2019-nCoV associate with human ACE-2, similar receptors in SARS CoV which bind to ACE2 receptors of human cells, also in cat, bat and pig; however not associated with cells without angiotensin-converting-enzyme 2.<sup>13–15</sup>

## 1.3. Routes of communication

The infections of SARS-CoV-2 mainly transmit by droplets oozed while respiration or with person to person contact hence infection can spread by coughing, sneezing by an infected patient by airborne route to the other non-infected patients in the close vicinity within the radius of approximately 6 feet.<sup>6</sup>

According to the researchers of United States fecal-oral route is also the one route of transmission of SARS-CoV-2.<sup>16</sup>

Steps of transmission of corona virus (Table 1):<sup>3</sup>

## 1.4. Incubation period

The average period of 5 to 6 days is considered as incubation period; however it has been estimated to be prolonged up to 14 days at present for keeping patient under medical supervision and quarantine of exposed individuals.<sup>17</sup>

## 1.5. Individuals with high risk of infection

It is revealed from the present studies that individuals of all ages are susceptible to these viral diseases. Although, the individuals in contact with COVID-19 affected persons have higher chance of being infected.<sup>1</sup>

Large number of patients tested positive for COVID-19 have good prognosis, whereas very low patients have reported with critical conditions, specifically involving those who are elderly or with underlying chronic diseases. On the day 1 of month of March 2020 79,968 cases were confirmed positive, 14,475 i.e.18.1% consist of patients with severe illness, and 2873 (3.5%) of deaths were reported in China by World health organization.<sup>18</sup>

The other complications involved include arrhythmia, nephritis, acute cardiac injury, secondary infection and liver

dysfunction.<sup>19</sup>

## 1.6. Symptoms

The infected patient have clinical symptoms such as dry-cough, fever, muscle pain, other symptoms which may appear include nausea, diarrhea, hyposmia i.e. loss of sense of smell, abnormal taste sensation i.e. dysguesia.<sup>20,21</sup> Patients undergone chest CT revealed pneumonia bilaterally along with opacity showing ground glass appearance multiple patchy shadows as a familiar pattern.<sup>22</sup> The COVID-19 infected geriatric patients suffering with other underlying diseases like diabetes, hypertension, respiratory diseases, cardiovascular disorders progressively developed ARDS, underwent shock, metabolic and coagulation dysfunction further leading to death.<sup>19</sup>

## 1.7. Diagnosis and treatment

Information i.e. travel history to infected areas 14 days prior to symptom origin, radiographic imaging i.e. CT, laboratory tests ‘reverse-transcriptase polymerase chain-reaction’ (RT-PCR) is established upon oro-pharyngeal and naso-pharyngeal swabs as specimens are the basis for diagnosis of COVID-19.<sup>23</sup> Presently the only protocol followed for controlling COVID-19 infection include early-diagnosis, isolation and supportive regime.<sup>24</sup> Some clinical studies revealed medications as interventions include Lopinavir and Remdesivir.<sup>25</sup>

## 2. Results of coronavirus pandemic on dental practice

Threat of nosocomial infection in dental operator: The frequent use of rotary instruments like air rotar handpiece and scalers in dental operator specially in case of infected patient with symptoms of cough and sneeze lead to spread of salivary and blood secretions in form of aerosols in the adjoining areas of the operating field. The machinery and dental equipments become contaminated in such situation and hence infection spread through breach of sharp instruments or directly by intercommunication within the mucosa and the infected hands of the operator.<sup>26</sup>

### 2.1. Considerations for dental procedures in coronavirus infection period

The dental professionals including dental doctors, hygienists, assistants and other personals should enhance their skills and knowledge concerning disinfection, patient follow up as suggested by the apex bodies time to time. The salivary epithelial cells potentially get infected with SARS-CoV and act as main infection source.<sup>27</sup>

The closure of dental practice during lockdowns can however reduce the chance of cross infection but the urgent patients requiring urgent treatment must be provided dental care.

**Table 1:**

1.	Imported cases	Individuals infected from outside nations
2.	Transmission at local level	Infected Individuals arrived from outside spread infection to their contacts
3.	Transmission at community level	Infected individuals without restricted movements (quarantine) transmit infection to unknown individuals
4.	Epidemic	The building of chain of infection resulting into massive spread of the infected cases

Hence standard instructions regarding dental procedures should be followed world over during COVID-19 pandemic.

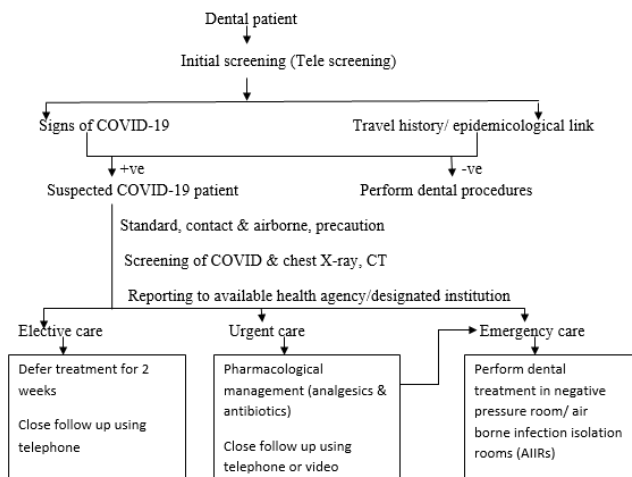
### 2.2. Management of dental patients for prevention of nosocomial infection

Dental care can be classified as shown in table 2. According to ADA<sup>28</sup>

### 2.3. Teledentistry and its application in current COVID-19 pandemic

‘Teledentistry (as the part of telehealth system along with telemedicine) is remote facilitating of dental health care, guidance, education or treatment with utilization of information-technology rather than by physical appearance or contact of operator and the patient’.<sup>29</sup>

Interactive tracking of the COVID-19 patient can be done as shown in the figure 1 (Figure 1).<sup>30</sup>

**Fig. 1:**

### 2.4. Parts of Teledentistry includes

1. Teleconsultation: In this procedure the patient or the local health care provider seeks consultation with dental specialist via the telephonic mode.<sup>31</sup>
2. Telediagnosis: This method utilizes the technology for exchanging images and data for proper diagnosis

of the oral lesions.<sup>32,33</sup> The various devices like smart phones, MeMoSA (mobile mouth screening anywhere), Cell scope device, WhatsApp have used for teleconsultation.<sup>34–38</sup>

3. Telerriage: It involves safe, suitable and timely deposition of symptoms of patient with smart phone by a specialist. It is utilized for remote assessment of children in school and to separate those who require treatment without their unnecessary visit to dental offices.<sup>39</sup>

4. Telemonitoring: This technique reduces the visit of patient to dentist as replaced by virtual visits for consistent assessment of treatment results.<sup>31</sup>

Assessment of dental patient: The following Table 3 . Reveals questions asked from patient on arrival to the dental office for patient assessment.

Emergency pharmacological management: The following Table 4. indicates primary and secondary management in emergency conditions during COVID-19 pandemic.

### 2.5. Standard precautions to be followed for disease transmission and logistics to be used

Dental professionals should follow standard precautions to protect themselves from COVID infection which includes hand hygiene (hand washing with water and soap upto 20 sec or utilization of hand-sanitizer with composition of 60% alcohol), utilization of PPEs, sharp safety, respiratory hygiene, sterile instruments and equipments, disinfection of the operating fields. Transmission based precaution includes patient isolation, ventilation, use of N-95 masks and deferring of non urgent procedures. Dentist should wear surgical mask, eye wear, face shields, for protection from droplet spattering. Negative – pressure rooms ‘Airborne Infection Isolation Rooms’ (AIIRs) set up should be established for treatment of COVID-19 infected patients in case of dire emergencies. The other additional methods to be followed in dental practice for protection from COVID as precautionary measures include use of .01% NaOCl which inactivates viral agents aspirated via water lines.<sup>46</sup> The filtration of air can be done via high efficiency aerosol arrestor filters establishment in the dental clinics.<sup>47</sup>

**Table 2:**

Dental emergencies	Urgent procedures	Additional urgent procedures
1.Uncontrolled bleeding 2.Cellulitis or soft tissue infection with intra-oral and extra-oral swelling leading to compromised air way 3.Facial trauma, resulting in a compromised airway	1.Acute dental pain of pulpal origin 2.Pericoronitis or pain from 3 <sup>rd</sup> molar 3.Surgical post-operative osteitis, alteration of dressings in case of dry-socket 4.Space infections leading to pain or trauma to soft tissue 5.Dental trauma resulting in luxation or avulsion 6.Tooth fracture resulting in pain 7.Dental treatment as a prerequisite for critical medical procedures 8.Cementation of FPD if temporary restoration is broken or lost 9.Biopsy performed on abnormal tissue	1.Substantial tooth caries or faulty restorations resulting in pain 2.Temporary restorations should be done when required 3.Removal of sutures 4.Adjustment of prostheses in case of patient on radiation therapy 5.Replacement of temporary restoration on access openings 6.Orthodontic wire or appliance piercing oral mucosa should be adjusted

**Table 3:** Date: Name: Date of birth:

Yes	No	Screening questions for COVID-19
		In past 14 days have you or any household member travelled in areas of COVID-19 infection?
		In past 14 days have you or any household member had any contact with known COVID-19 patient?
		Have you or household member have history of exposure to COVID-19 biologic material?
		Have you had any history of fever in last 14 days?
		Have you had any symptom of cough, breathlessness, diarrhea, body pain, alteration of smell or taste sensation in last 14 days?
		Urgent dental need question? Do you have uncontrolled tooth pain, infection, swelling, bleeding or trauma to your mouth?

**Table 4:**

Diagnosis	Primary management	Secondary management
Symptomatic irreversible pulpitis Symptomatic apical periodontitis	Pain management: 1 <sup>st</sup> line: Ibuprofen 600 mg + Acetoaminophen 325-500mg <sup>40,41</sup> 2 <sup>nd</sup> line: Dexamethasone 0.07-0.09mg/kg <sup>42</sup>	Full pulpotomy <sup>43</sup>
Acute apical abscess	Incision and drainage Augmentin 500mg b.i.dx5days/Clindamycin 300mgq.i.dx5 days <sup>44</sup> Ibuprofen 600 mg + Acetoaminophen 325-500mg <sup>40,41</sup>	Call Oral & Maxillofacial surgeon
Avulsion/luxation	If tooth is replanted follow pain management-dependent on age 1 <sup>st</sup> line: Ibuprofen 600 mg + Acetoaminophen 325-500mg <sup>40,41</sup>	If tooth is not replanted , replant and follow IADTguidelines <sup>45</sup>
Tooth fracture resulting in pain	Pain management: Ibuprofen 600 mg + Acetoaminophen 325-500mg <sup>40,41</sup>	Vital pulp therapy <sup>43</sup>
Trauma involving facial bones Cellulitis or diffuse soft tissue bacterial infection which compromises airway	Call Oral & Maxillofacial surgeon Call Oral & Maxillofacial surgeon	

### 3. Conclusion

The main duty of all the dental professionals in COVID-19 pandemic is the protection of themselves and their patients from the transmission of the infection after following all the recommendations and standard guidelines issued by various health authorities time to time, however educating the patient and making the appropriate clinical decisions for patient benefit during this pandemic is a challenging task for all the dental professionals. Our review article will definitely be helpful for the dental clinicians for making appropriate decisions while treating their patients during this COVID-19 pandemic phase.

### 4. Source of Funding

None.

### 5. Conflict of Interest

None.

### References

- Meng L, Hua F, Bian Z. Coronavirus Disease 2019 (COVID-19): Emerging and Future Challenges for Dental and Oral Medicine. *J Dent Res.* 2020;99(5):481–7.
- Li Q, Guan X, Wu P, Wang X, Zhou L, Tong Y, et al. Early transmission dynamics in Wuhan, China, of novel coronavirus-infected pneumonia. *N Engl J Med.* 2020;.

3. Mahase E. China coronavirus: WHO declares international emergency as death toll exceeds 200. *BMJ*. 2020;368:408.
4. World Health Organization. Coronavirus Disease 2019 (COVID-19): Situation report. 2019; Available from: <https://www.who.int/docs/default-source/coronaviruse/situation>.
5. Centers for disease control and prevention, interim infection prevention and guidance for dental settings during the COVID-19 response. Atlanta, GA, USA; 2019. Available from: <https://www.cdc.gov/coronavirus/2019-ncov/hcp/dental-settings.html>.
6. Chan JF. A familial cluster of pneumonia associated with the 2019 novel coronavirus indicating person-to-person transmission: A study of a familial cluster. *Lancet*. 2020;395:514–23.
7. Lu R. Genomic characterization and epidemiology of 2019 novel coronavirus: Implications for virus origins and receptor binding. *Lancet*. 2020;395:565–74.
8. Li F. Structure, function and evolution of coronavirus spike proteins. *Annu Rev Virol*. 2016;3:237–61.
9. Wu F. A new coronavirus associated with human respiratory disease in China. *Nat*. 2020;579:265–91.
10. Zhou P. A pneumonia outbreak associated with a new coronavirus of probable bat origin. *Nat*. 2020;579:270–3.
11. Hantak MP, Qing E, Earnest JT, Gallagher T. Tetraspanins: Architects of Viral Entry and Exit Platforms. *J Virol*. 2018;93(6):1429–46.
12. Belouzard S, Millet JK, Licitra BN, Whittaker GR. Mechanisms of Coronavirus Cell Entry Mediated by the Viral Spike Protein. *Viruses*. 2012;4(6):1011–33.
13. Wan Y, Shang J, Graham R, Baric RS, Li F. Receptor Recognition by the Novel Coronavirus from Wuhan: An Analysis Based on Decade-Long Structural Studies of SARS Coronavirus. *J Virol*. 2020;94(7):1–9.
14. Chai X, Hu L, Zhang Y, Han W, Lu Z, Ke A, et al. Specific ACE2 Expression in Cholangiocytes May Cause Liver Damage After 2019-nCoV Infection. 2020; Available from: <https://www.biorxiv.org/content/10.1101/2020.02.03.931766v1>.
15. Fan C, Li K, Ding Y, Lu WL, Wang J. ACE2 Expression in kidney and testis may cause kidney and testis damage after 2019-nCoV infection. Available from: <https://www.medrxiv.org/content/10.1101>.
16. Holshue ML, DeBolt C, Lindquist S, Lofy KH, Wiesman J, Bruce H, et al. First Case of 2019 Novel Coronavirus in the United States. *N Engl J Med*. 2020;382(10):929–36.
17. Backer JA, Klinkenberg D, Wallinga J. Incubation period of 2019 novel coronavirus infections among travelers from Wuhan, China. *Euro Surveill*. 2020;25(5):20–8.
18. WHO Coronavirus disease Situation Reports;2020.
19. Huang C. Clinical features of patients infected with novel coronavirus in Wuhan, China. *Lancet*. 2020;395:497–506.
20. Chen H. Clinical characteristics and intrauterine vertical transmission potential of COVID-19 infection in nine pregnant women: a retrospective review of medical records. *Lancet*. 2020;p. 30360–30363.
21. Chen N. Epidemiological and clinical characteristics of 99 cases of 2019 novel coronavirus pneumonia in Wuhan, China: a descriptive study. *Lancet*. 10223;395:507–13. doi:2020.
22. Guan WJ. Clinical characteristics of 2019 novel coronavirus infection in China; 2020.
23. Wong JG. Psychological responses to the SARS outbreak in healthcare students in Hong Kong. *Med Teach*. 2004;26(7):657–9.
24. Wang D. Clinical characteristics of 138 hospitalized patients with 2019 novel coronavirus-infected pneumonia in Wuhan, China. *JAMA*. 2020;.
25. Rio CD, Malani PN. 2019 Novel Coronavirus—Important Information for Clinicians. *JAMA*. 2020;323(11):1039.
26. Kohn WG. Centers for Disease Control and Prevention. Guidelines for infection control in dental health-care settings-2003. *MMWR Recomm Rep*. 2003;52:1–61.
27. Liu L. Epithelial cells lining salivary gland ducts are early target cells of severe acute respiratory syndrome coronavirus infection in the upper respiratory tracts of rhesus macaques. *J Virol*. 2011;85:4025–30.
28. Mihailovic B, Miladinovic M, Vujicic B. Telemedicine in dentistry (teledentistry). In: Roelofs TA, editor. *Advances in Telemedicine: Applications in various Medical Disciplines and Geographical Areas*; 2011. p. 215–30.
29. Khan SA, Omar H. Teledentistry in Practice: Literature Review. *Teledent e-Health*. 2013;19(7):565–7.
30. Ather A, Patel B, Ruparel NB, Diogenes A, Hargreaves KM. Coronavirus Disease 19 (COVID-19): Implications for Clinical Dental Care. *J Endod*. 2020;46(5):584–95.
31. Maino R, Ghanim A. Teledentistry: A systematic review of the literature. *J Teledent Telecare*. 2013;19:179–83.
32. Kaliyadan F, Ramsey ML. *Teledermatology*. StatPearls, Treasure Island (FL). . StatPearls Publishing; 2020.
33. Lee JJ, English JC. Teledermatology: A Review and Update. *Am J Clin Dermatol*. 2018;19(2):253–60.
34. Alshaya MS, Assery MK, Pani SC. Reliability of mobile phoneteledentistry in dental diagnosis and treatment planning in mixed dentition. *J Teledent*. 2020;26:45–52.
35. Kohara EK. Is it feasible to use smartphone images to perform telediagnosis of different stages of occlusal caries lesions? *Plos One*. 2018;13:202116.
36. Haron N. m-Health for early detection of oral cancer in low-and middle-income countries. *Teledent J e Health*. 2020;26:278–85.
37. Skandarajah A, Sunny SP, Gurpur P, Reber CD, D'Ambrosio MV, Raghavan N, et al. Mobile microscopy as a screening tool for oral cancer in India: A pilot study. *PLOS ONE*. 2017;12(11):e0188440.
38. Machado RA, de Souza NL, Oliveira RM, Júnior HM, Bonan PRF. Social media and telemedicine for oral diagnosis and counselling in the COVID-19 era. *Oral Oncology*. 2020;105:104685–104685. Available from: <https://dx.doi.org/10.1016/j.oraloncology.2020.104685>. doi:10.1016/j.oraloncology.2020.104685.
39. Estai M, Kanagasingam Y, Mehdizadeh M, Vignarajan J, Norman R, Huang B, et al. Teledentistry as a novel pathway to improve dental health in school children: a research protocol for a randomised controlled trial. *BMC Oral Health*. 2020;20(1):11.
40. Watts K, Balzer S, Drum M, Nusstein J, Reader A, Fowler S, et al. Ibuprofen and Acetaminophen Versus Intranasal Ketorolac (Sprix) in an Untreated Endodontic Pain Model: A Randomized, Double-blind Investigation. *J Endod*. 2019;45(2):94–8.
41. Smith EA, Marshall JG, Selph SS, Barker DR, Sedgley CM. Nonsteroidal Anti-inflammatory Drugs for Managing Postoperative Endodontic Pain in Patients Who Present with Preoperative Pain: A Systematic Review and Meta-analysis. *J Endod*. 2017;43(1):7–15.
42. Liesinger A, Marshall FJ, Marshall JG. Effect of variable doses of dexamethasone on posttreatment endodontic pain. *J Endod*. 1993;19(1):35–9.
43. Eren B, Onay EO, Ungor M. Assessment of alternative emergency treatments for symptomatic irreversible pulpitis: a randomized clinical trial. *Int Endod J*. 2018;51(3):e227–37.
44. Baumgartner JC, Xia T. Antibiotic Susceptibility of Bacteria Associated with Endodontic Abscesses. *J Endod*. 2003;29(1):44–7.
45. Diangelis AJ, Andreasen JO, Ebeleseder KA. Guidelines for management of traumatic dental injuries: 1. Fractures and luxations of permanent teeth. *Pediatr Dent*. 2017;39:401–11.
46. Ceisel RJ, Ostek EM, Turner DW, Spear PG. Evaluating chemical inactivation of viral agents in handpiece splatter. *J Am Dent Assoc*. 1995;126(2):197–202.
47. Yadav N, Agarwal B, Maheshwari C. Role of high-efficiency particulate arrester filters in control of air borne infections in dental clinics. *SRM J Res Dent Sci*. 2015;6:240–2.

## Author biography

**Nitin Sharma** Medical Officer Dental

**Archana Nagpal** Professor and Head

**Tarush Thakur** Private Practitioner

**Aprajita Dogra** Private Practitioner

**Cite this article:** Sharma N, Nagpal A, Thakur T, Dogra A. **Corona virus disease COVID-19 and dentistry.** *IP Ann Prosthodont Restor Dent* 2020;6(3):124-129.