



Case Report

Fixed functional appliances (Forsus) an effective solution to noncompliant patients: A case report of two cases

Ashish Kamboj^{1,*}, Atul Bali², SS Chopra¹, Pulkit Lakhani³, Apoorva Sharma⁴

¹Dept. of Dental Surgery, Armed Forces Medical College, Pune, Maharashtra, India

²Dept. of Orthodontics, Army Dental Centre (R&R), Delhi Cantt., New Delhi, India

³Dept. of Orthodontics, Surendra Dental College, Sriganganagar, Rajasthan, India

⁴Dept. of Orthodontics, Rajasthan Dental College, Jaipur, Rajasthan, India



ARTICLE INFO

Article history:

Received 08-03-2021

Accepted 17-03-2021

Available online 27-03-2021

Keywords:

Retroclination

Forsus FRD

ABSTRACT

Mandibular retrusion is the most prevailing characteristic feature of Class II malocclusion. Removable Functional appliances and Fixed Functional Appliances (FFA) have been utilized for correction of Class II malocclusions in growing patients.

This paper discusses the management of two young patients with Angles Class II Division 2 malocclusion with minimal growth remaining and with mandibular retrognathism who were treated with a two-phase therapy. The first phase involved alignment of arches with fixed Pre Adjusted Appliance (0.018" Roth). This was followed by a second phase involving application of Forsus fixed functional appliance for 6 months that resulted in unlocking of the mandible to Class I molar and canine relationship.

Fixed Functional Appliances in general and the Forsus FRD in particular when used in conjunction with full bonded fixed appliance greatly facilitates the correction of Class II Division 2 malocclusions and the duration of the treatment is also reduced.

© This is an open access article distributed under the terms of the Creative Commons Attribution License (<https://creativecommons.org/licenses/by/4.0/>) which permits unrestricted use, distribution, and reproduction in any medium, provided the original author and source are credited.

1. Introduction

Class II malocclusion is one of the most frequent problems encountered in orthodontics and it occurs in about one third of the population.¹ This malocclusion is described as a distal relationship of the mandible to the maxilla with a combination of different dental and skeletal components which can affect facial aesthetics and functional status adversely.²

Angle further divided the malocclusion into Division 1 and Division 2 depending upon the incisor relationship. Division 2 is characterised by distocclusion, increased overbite, labioversion of maxillary lateral incisors, retroclination of the maxillary central incisors and a more normal lip function. The facial skeleton is not retrognathic like Division 1 malocclusion.³ The deepbite which occurs

in Class II Division 2 patients is because of Infra-occlusion of molars and lack of effective occlusal stops for the eruption of lower incisors leads to an increased overbite. These patients are also characterised by more acute crown root angulation (Collum angle) as a result of high lower lip line causing deflection of the crown to the tooth relative to the root after eruption.^{4,5}

Removable or fixed functional appliances can be used to correct Class II malocclusions depending on the existing antero-posterior discrepancy, cooperation, and growth status of the patient. Patients who have completed their growth and those with Class II mandibular retrusion are mostly treated with fixed functional appliances which require minimal patient co-operation.^{6,7} A number of Class II correctors have been introduced in the recent past that reduce or minimize the need for patient compliance.

The aim of this paper is to project and discuss two successful cases of Class II Division 2 malocclusion treated

* Corresponding author.

E-mail address: aashishkamboj@gmail.com (A. Kamboj).

with Forsus Hybrid Fixed functional appliance.

2. Case 1

A 15 years old girl reported with the chief complaint of irregular and backwardly positioned upper front teeth. Extraoral clinical examination indicated straight profile with prominent chin, decreased lower anterior facial height, and deep mentolabial sulcus. The intraoral examination showed Class II molar and canine relationships in both right and left segments with overjet (1 mm) with retroclined centrals & right lateral Incisor and 100% deep bite.

Examination of the lateral cephalometric radiograph (Table 1) indicated skeletal Class II malocclusion (ANB: 5 degree) with normally positioned maxilla, retrognathic mandible and horizontal growth pattern.

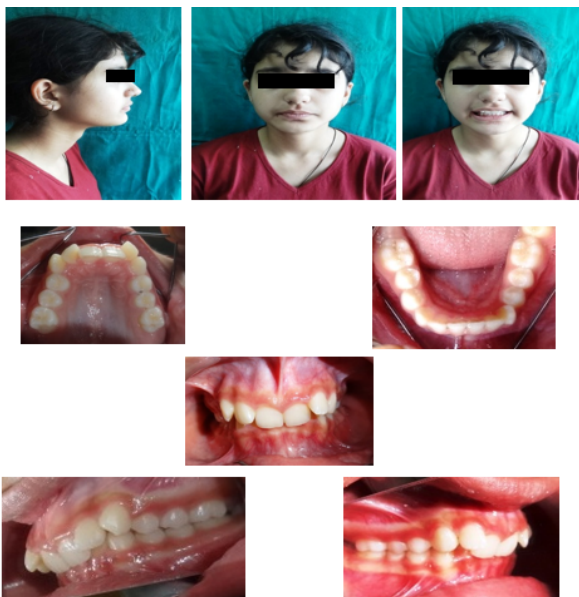

Fig. 1: Case-1 Pre treatment

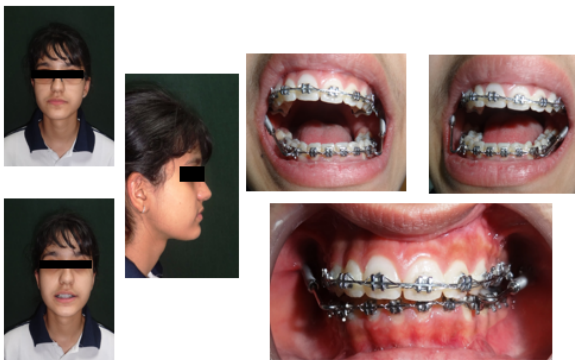

Fig. 2: Forsus in situ

2.1. Treatment plan

Phase I Fixed mechanotherapy with 0.018 " ROTH PEA Non extraction treatment plan **Phase II** – Mandibular growth modulation with hybrid fixed functional appliance (FORSUS FRD) followed by retention.

2.2. Treatment results

Pre-treatment & Post-treatment Cephalometric measurements are given in Table 1. The results indicated improvement in both skeletal and dental parameters. At the end of treatment an ideal overjet & overbite were achieved.

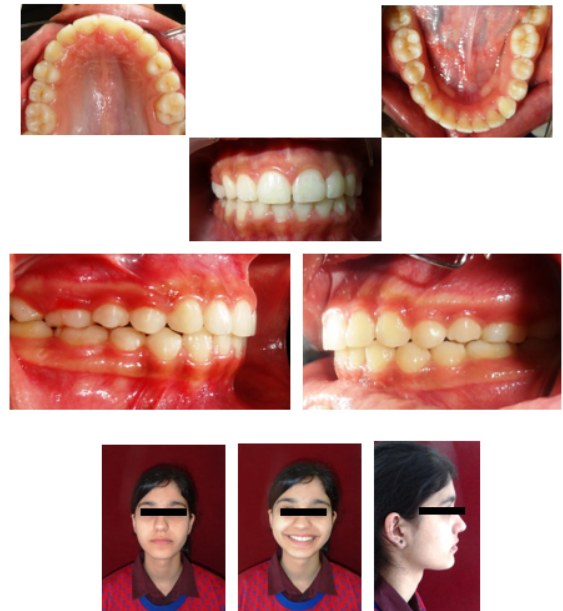

Fig. 3: Case-1 PostTreatment

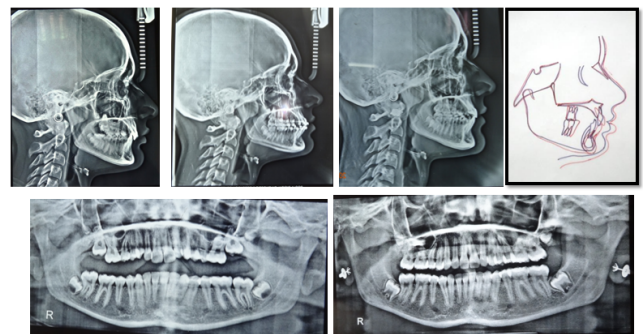


Fig. 4: Pre & Post treatment radiographs and superimposition

Cephalometric superimposition indicated downward and forward movement of the mandibular dentoalveolar arch and restraint of the maxillary dentoalveolar segment. ANB angle decreased from 5 degrees to 2 degrees with SNA of 79° and an SNB angle of 77 degree and Wits from +3 to -1mm.

Cephalometric measurements indicated that mandibular incisors were proclined from IMPA of 89 degree to 110 degree.

3. Case 2

A 15 years old boy reported with the chief complaint of unsightly appearance and irregular upper front teeth. Extraoral clinical examination revealed convex profile with prominent chin, slightly decreased lower anterior facial height, and deep mentolabial sulcus. The intraoral examination showed retroclined central incisors Class II molar and canine relationships in both right and left buccal segments with an overjet of 1 mm and 100% deep bite.

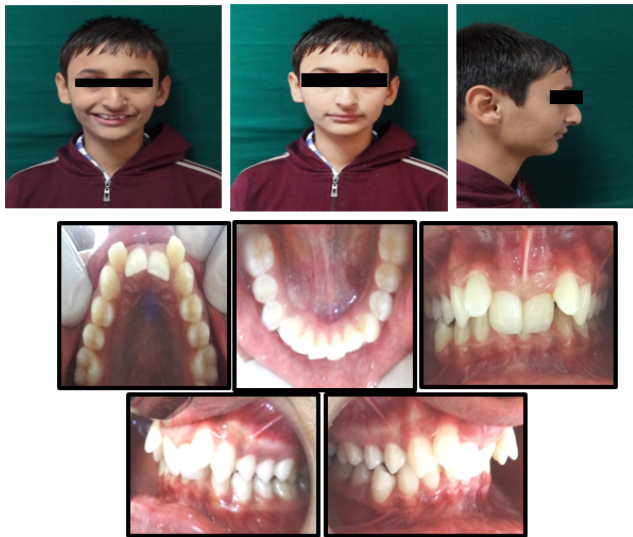

Fig. 5: Case-2 Pre treatment

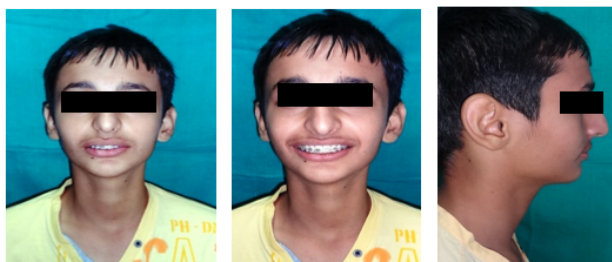
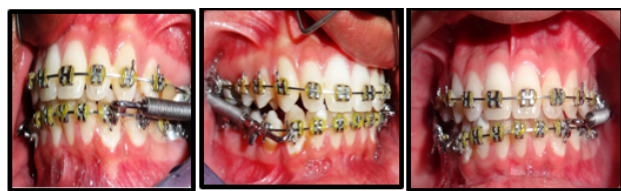
Fig. 6: Forsus in situ

Examination of the lateral cephalometric radiograph (Table 2) indicated skeletal Class II malocclusion and

horizontal growth pattern.

3.1. Treatment plan

Phase I leveling and alignment Phase II Similar mechanics as in case 1 were carried out in this case also with Forsus Fatigue Resistant Device in situ for 06 months and the total treatment time for the case was 24 months.

3.2. Treatment results

Cephalometric measurements at the pre-treatment, post-treatment periods are given in Table 2. The results indicated improvement in both skeletal and dental parameters. At the end of treatment, ideal overjet and overbite were established and there was improvement in profile

End treatment intraoral examination revealed that teeth were well aligned in Angles Class I occlusion.

Cephalometric measurements indicated that maxillary incisors were labially inclined (U1-SN: 97° to 105°), and mandibular incisors were proclined from IMPA of 81° to 95°

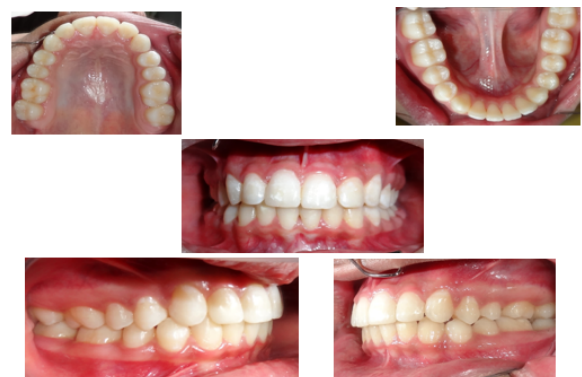

Fig. 7: Case-2 Post treatment

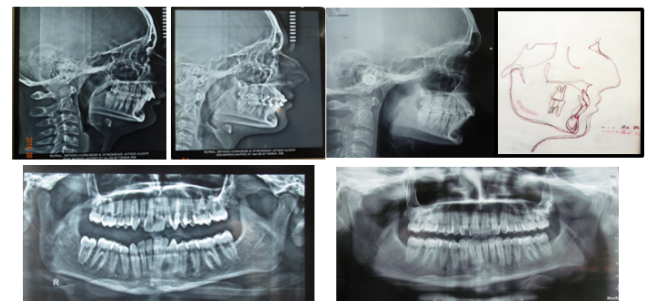


Fig. 8: Pre & Post treatment radiographs and superimposition

Table 1:

Cephalometric Value	Pre-treatment	Post-treatment
SNA	79 deg	79 deg
SNB	74 deg	77 deg
ANB	5 deg	2 deg
WITS	+ 3 mm	-1 mm
IMPA	89 deg	110 deg
(U1-SN)	95 deg	112 deg
(U1-NA)	21 deg & -4mm	23 deg & 3mm
(U1-NB)	26 deg & 1 mm	29 deg & 8mm
GO GN TO SN	22 deg	28 deg

Table 2:

Cephalometric Value	Pre-treatment	Post-treatment
SNA	80 deg	80 deg
SNB	75 deg	77 deg
ANB	5 deg	2 deg
WITS	+ 2 mm	0 mm
0mm(females)		
IMPA	81 deg	95 deg
(U1-SN)	97 deg	105 deg
(U1-NA)	17 deg & 1 mm	23 deg & 3mm
(L1-NB)	18 deg & 1 mm	26 deg & 5mm
GO GN TO SN)	25 deg	28 deg

4. Discussion

Fixed Functional Appliances offer an effective solution to treat young adult patients with Class II Div 2 malocclusions post their peak velocity growth but who still have a small amount of residual growth left.

Emil Herbst was the first to use fixed functional appliance to treat malocclusion as early as 1905.⁸ Hans Pancherz has been credited with the reintroduction of the Herbst Appliance in the 1970's and he has published a voluminous literature on the long term skeletal, dentoalvolar and TMJ changes brought about by the Herbst appliance.^{9,10}

One of the major disadvantages of the Herbst appliance is that the appliance is so designed to hold the mandible in the postural forward position and once the appliance is fitted in the patient's mouth, the patient is unable to close in the centric relation.

The Jasper Jumper is a fixed functional device which consists of a spring which is contained in a vinyl coated tube however frequent fractures and fatigue were major drawback of these flexible fixed functional appliances which lead to the introduction of Hybrid Fixed Functional appliances.

The Forsus Fatigue resistant device is a hybrid fixed functional appliance supplied in five different lengths 25,29 32,35 and 38mm. Sood S¹¹ in his master thesis studied the cephalometric findings in a group of seven patients and concluded that the Forsus FRD leads to marked

improvement in profile, overjet and overbite in treated subjects. The study showed that there are statistically significant changes in mandibular length, improvement in ANB angle and significant increase in the IMPA.

Sood et al¹² while evaluating muscle response during treatment of Class II Div 1 subjects with Forsus Fatigue resistant device concluded that though the Class II correction occurs in 3 months it is advisable to give the appliance at least six months for allowing adequate neuromuscular adaptation to occur for long term stability of the result.

In the above mentioned two cases as the patients had some residual growth remaining (CVMI stage CS5), therefore it was decided to treat both patients with non-extraction orthodontic mechanics.

Forsus FRD appliance is usually recommended for the Class II malocclusions especially in patients with mandibular dentoalveolar retrusion. This appliance can lead to mandibular growth and favourable dentoalveolar changes in patients at or before the peak phase of pubertal growth.^{13,14} On the other hand, mostly dental changes are encountered for the patients at post-pubertal period.¹⁵

In both cases treatment with Forsus FRD lead to correction of the Class II Div 2 malocclusion to a Class I occlusion. The treatment lead to correction of both skeletal and dentoalveolar parameters however in both cases there was significant improvement in the ANB angle and WITS value (Tables 1 and 2), the most probable reason for this could have been unlocking of the mandible and its forward displacement after correction of the retroclination of the maxillary incisors.

The dentoalveolar changes were evident in both maxillary and mandibular arches (Tables 1 and 2). Maxillary incisors and first molars demonstrated distal movement and intrusion. Mandibular first molars showed mesial movement and extrusion, and lower incisors exhibited proclination.

The correction of the overjet was achieved by the forward movement of the mandibular dentition and proclination of the mandibular incisors as well as headgear like effect on the maxillary incisors. The correction of overbite was achieved by proclination of retroclined maxillary incisors and extrusion of mandibular molars and proclination of the lower incisors.

5. Conclusion

Thus to conclude Fixed Functional Appliances in general and the Forsus FRD in particular when used in conjunction with full bonded fixed appliance facilitate the correction of Class II Div 2 malocclusion and the duration of the treatment is also reduced. The improvement is mostly contributed by skeletal changes that include an headgear like effect on the maxilla and distalisation of the maxillary molars, mesialisation of the mandibular molars and proclination of mandibular incisors.

The most likely reason for correction of the cephalometric parameters such as ANB angle and Wits is the forward posturing of the mandible due to unlocking of the lower jaw which occurs due to proclination of the retroclined maxillary incisors.

6. Source of Funding

No financial support was received for the work within this manuscript.

7. Conflict of Interests

The author declares that they do not have any conflict of interests

References

1. Proffit WR, Fields HW, Moray LJ. Prevalence of malocclusion and orthodontic treatment need in the United States: estimates from the NHANES-III survey. *Int J Adult Orthod Orthognathic Surg.* 1998;13(2):97–106.
2. Alarashi M, Franchi L, Marinelli A, Defraia E. Morphometric analysis of the transverse dentoskeletal features of class II malocclusion in the mixed dentition. *Angle Orthodontist.* 2003;73(1):21–5.
3. Angle EH. Treatment of malocclusion of teeth and fractures of maxillae. In: 7th Edn. Philadelphia. SS white manufacturing Co; 1990.
4. Delivanis HP, Kufnec MM. Variation in morphology of the maxillary central incisors found in class II, division 2 malocclusions. *Am J Orthod.* 1980;78(4):438–43.
5. Srinivasan B, Kailasam V, Chitharanjan A, Ramalingam A. Relationship between crown-root angulation (collum angle) of maxillary central incisors in Class II, division 2 malocclusion and lower lip line. *Orthodontics (Chic).* 2013;14(1):e66–e74. doi:10.11607/ortho.841.
6. Franchi L, Alvetto L, Giuntini V, Masucci C, Defraia E, Baccetti T, et al. Effectiveness of comprehensive fixed appliance treatment used with the Forsus Fatigue Resistant Device in Class II patients. *Angle Orthodontist.* 2011;81(4):678–83. doi:10.2319/102710-629.1.
7. Zymperdikas VF, Koretsi V, Papageorgiou SN, Papadopoulos MA. Treatment effects of fixed functional appliances in patients with Class II malocclusion: a systematic review and meta-analysis. *Eur J Orthod.* 2016;38(2):113–26. doi:10.1093/ejo/cjv034.
8. Dreissigjähre HE. Erfahrungen mit dem Retentions Scharnier. *Zahnärztl Rundschau.* 1934;43:1611–6.
9. Panchez H. Treatment of Class II malocclusions by bite jumping with Herbst appliance: a cephalometric investigation. *AJO.* 1979;76(4):423–42.
10. Panchez H. The mechanism of Class II Correction in Herbst appliance treatment: A cephalometric investigation. *AJO.* 1982;82(2):104–13.
11. Sankalp S. Orthodontic thesis. All India Institute of Medical Sciences. New Delhi; 2006.
12. Sood S, Kharbada OP, Duggal R, Sood M, Gulati S. Muscle response during treatment of Class II Div 1 malocclusion with Forsus Fatigue resistant device. *J clin Pediatr dent.* 2011;35(3):331–8.
13. Bilgic, Hamamci O, Basaran G. Comparison of the effects of fixed and removable functional appliances on the skeletal and dentoalveolar structures. *Australian Orthodontic Journal.* 2011;27(2):110–116.
14. Mahamad IK, Neela PK, Mascarenhas R, Husain A. A comparison of Twin-block and Forsus (FRD) functional appliance-a cephalometric study. *Int J Orthod;*23(3):49–58.
15. Upadhyay M, Yadav S, Nagaraj K, Uribe F, Nanda R. Mini-implants vs fixed functional appliances for treatment of young adult Class II female patients. *Angle Orthodontist.* 2012;82(2):294–303. doi:10.2319/042811-302.1.

Author biography

Ashish Kamboj, Assistant Professor

Atul Bali, Assistant Professor

SS Chopra, Professor

Pulkit Lakhani, Assistant Professor

Apoorva Sharma, Assistant Professor

Cite this article: Kamboj A, Bali A, Chopra SS, Lakhani P, Sharma A. Fixed functional appliances (Forsus) an effective solution to noncompliant patients: A case report of two cases. *IP Indian J Orthod Dentofacial Res* 2021;7(1):85-89.