



Case Report

CAP splint: An armour to safeguard developing dentition in paediatric mandibular fractures- A case series

Meenakshi Mahendra Singh^{1,*}, Shagun Rajpal¹, Neha Priya¹, Mohd Ghaus Ali¹, Sana Akhtar¹

¹Dept. of Pedodontic and Preventive Dentistry, Kothiwal Dental College and Research Centre, Moradabad, Uttar Pradesh, India



ARTICLE INFO

Article history:

Received 09-02-2021

Accepted 13-03-2021

Available online 27-03-2021

Keywords:

Mandibular fractures

Condylar neck

Cap splints

Morbidity

ABSTRACT

Mandible Fractures account for 5% of all facial fractures. The most common of mandible fractures are those in the condylar region followed by angle and then by body fractures. A good thing about Mandibular Fractures in children in comparison to adults is that their embedded tooth buds hold the mandible fragments like a glue. Also, the condylar neck which is short and thick tends to resist the fracture therefore the majority of mandible fractures in children are of un-displaced type. The purpose of the present case series is to demonstrate a conservative and effective treatment modality for the pediatric mandibular fractures with cap splints, which limited the discomfort and morbidity while taking care of the anatomical, physiological, and psychological complexity of developing jaw in children.

© This is an open access article distributed under the terms of the Creative Commons Attribution License (<https://creativecommons.org/licenses/by/4.0/>) which permits unrestricted use, distribution, and reproduction in any medium, provided the original author and source are credited.

1. Introduction

Facial trauma in children can often be challenging to manage with long-term consequences involved and the psychological impact. The most common mandibular fracture site in children are subcondylar, and the angle followed by parasymphysis region while the body fracture are comparatively rare.^{1,2} The high tooth to bone ratio predisposes the mandible to fracture compared to the midface.¹⁻³ The traditional treatment methods of open reduction with the internal fixation have little applicability in children.^{1,2,4}

The different techniques that are available for managing paediatric mandible fractures:

1. Circumferential Wiring
2. Cap Splint
3. Open Reduction
4. Resorbable Plates
5. Orthodontic Resin
6. Modified Orthodontic Brackets

* Corresponding author.

E-mail address: demeenakshi.m.singh@gmail.com (M. M. Singh).

The use of cap splints for treating pediatric mandibular fractures is a versatile technique as they:

1. Re-establish function and esthetics with limited morbidity;
2. Does not hinder jaw growth and developing dentition; and
3. Can be used for wider age of patients.¹⁻⁷

The purpose of the present case series is to demonstrate a conservative and effective treatment modality for the pediatric mandibular fractures with cap splints, which limited the discomfort and morbidity.

2. Case Series

2.1. Case 1

A 4-year-old female child presented with multiple maxillofacial laceration wounds with the history of road side accident a day ago. There was no history of convulsions/vomiting/nasal or ear bleed and loss of consciousness. Extra oral examination revealed bruises on perioral region with open mouth appearance. Intra oral examination revealed

mobility elicited on lower border of mandible. Derangement of occlusion could be appreciated. Tenderness could be appreciated along the lower border of the mandible over the same area. Deranged occlusion, the mobility of the fractured fragments, and restricted mouth opening was present. The computed tomographic (CT) findings revealed the right parasymphysial fracture. There was no clinical or radiographic evidence of the fracture in any other region. On the basis of CT scan findings and the clinical examination, a diagnosis was made as unilateral right parasymphysial fracture of the mandible.

A treatment plan was made to reduce and immobilize the fracture segments using closed cap splint and circummandibular wiring.

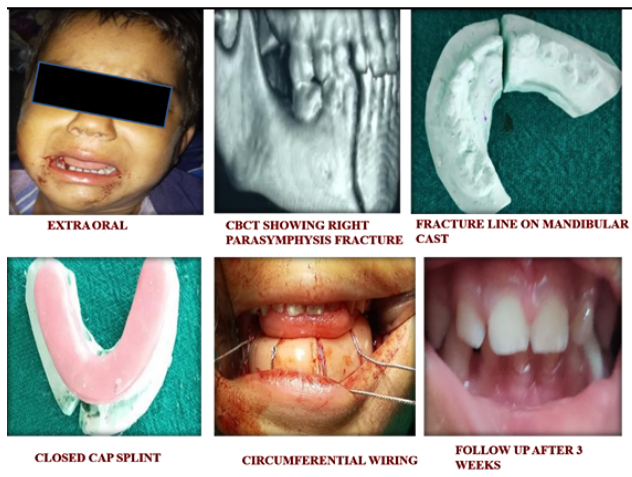


Fig. 1: Case 1 showing right parasymphysial fracture and its management using closed cap splint circumferential wiring.

2.2. Case 2

A 2.5-years-old male child presented with chin lacerations and pain in lower jaw due collision with bicycle a week ago. Extraoral examination revealed lacerated chin and intraoral examination revealed step defect in occlusion between 71 and 81. The panoramic radiograph(OPG) findings revealed the right mandibular body fracture. A treatment plan was made to reduce and immobilize the fracture segments using open cap splint and circummandibular wiring.

2.3. Case 3

A 4-years-old male child presented with the chief complaint of pain in the left mandibular region while chewing food. Patient had a history of road traffic accident (collision with motorcycle) 1 week back. Extraoral examination showed lacerations and bruise on left corner of lip. Intraoral examination revealed asymmetry of the arch in the 73 and 74 region. The skull posteroanterior view (PA view) revealed the left mandibular body fracture. A treatment plan

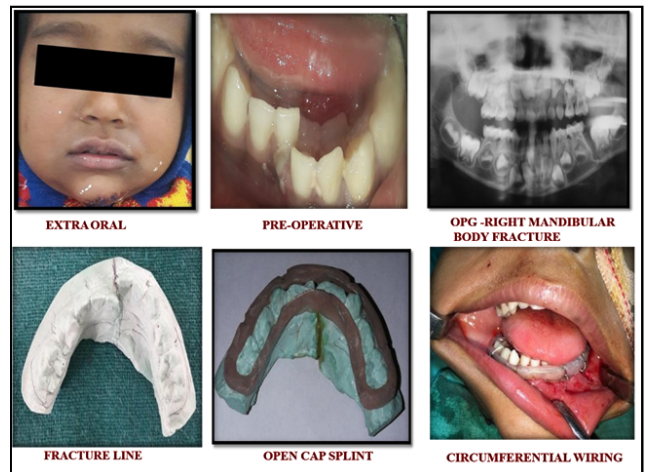


Fig. 2: Case 2 showing right mandibular body fracture and its management using open cap splint with circumferential wiring.

was made to reduce and immobilize the fracture segments using closed cap splint and circummandibular wiring.

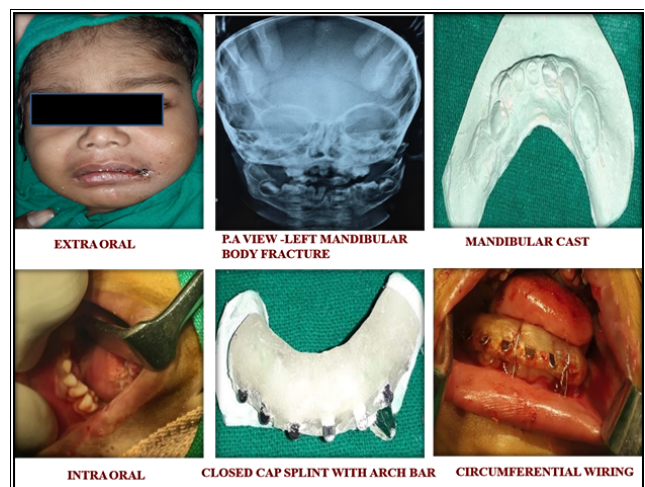


Fig. 3: Case 3 showing left mandibular body fracture and its management using closed cap splint with circumferential wiring.

2.4. Case 4

An 8-years-old female child reported with pain in lower jaw due to falling off from the building a week ago of reporting to the department. There was no history of bleeding. Extraoral examination revealed bilateral periorbital ecchymosis, lip and chin lacerations. Intraoral examination revealed step defect in the occlusion between 72 and 73. Open bite on right side could be well appreciated. The cone beam computed tomographic (CBCT) findings revealed the right mandibular body fracture. A treatment plan was made to reduce and immobilize the fracture segments using closed cap splint and circummandibular

wiring.

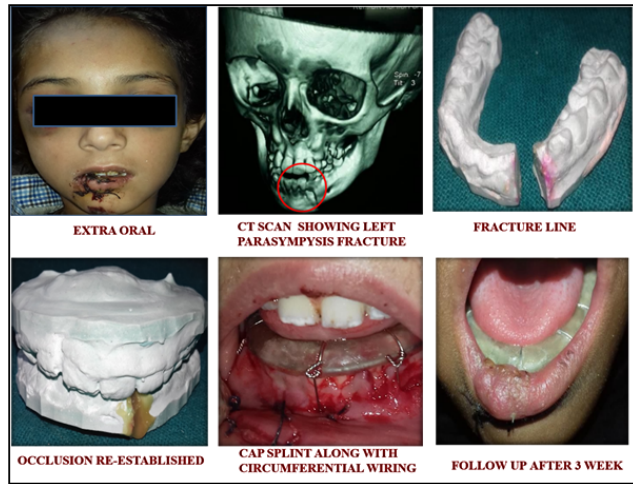

Fig. 4: Case 4 showing closed reduction and stabilization by means of closed cap splint with circum-mandibular wiring under G.A

2.5. Case 5

A 6-years old male child reported to the department with the chief complaint of pain in lower jaw due to collision with a motorcycle two days back. Extra oral examination revealed swelling on right cheek. Intra oral examination revealed mobility on lower border of mandible of right side. Derangement of occlusion was also seen. The cone beam computed tomographic (CBCT) findings revealed right mandibular body fracture. A treatment plan was made to reduce and immobilize the fracture segments using closed cap splint and circummandibular wiring under general anaesthesia.

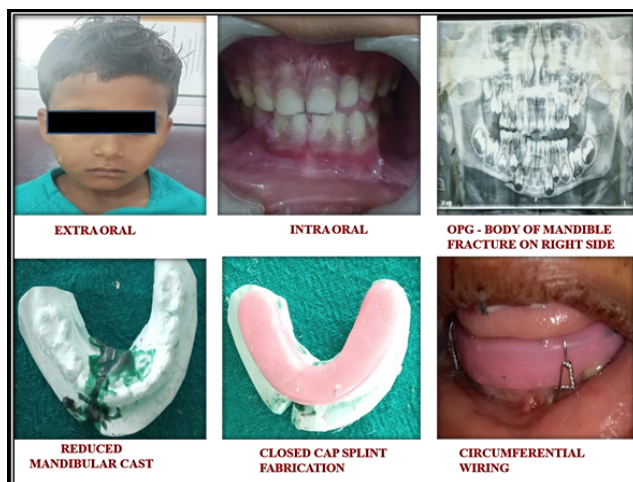

Fig. 5: Case 5 showing closed reduction and stabilization by means of closed cap splint with circum-mandibular wiring under G.A

2.6. Case 6

A 2 year-old girl reported to the department with swelling on left side of face and pain in same region. Patient parent gave a history of fall from terrace two days back. There was no history of bleeding from ear and nose. Extra oral examination revealed facial swelling, lacerations on cheek, left side periorbital ecchymosis. Intra oral examination showed step defect between 71 and 72 along with tenderness. The computed tomography (CT scan) revealed the left mandibular parasymphseal fracture. A treatment plan was made to reduce and immobilize the fracture segments using closed cap splint and circummandibular wiring under general anaesthesia.

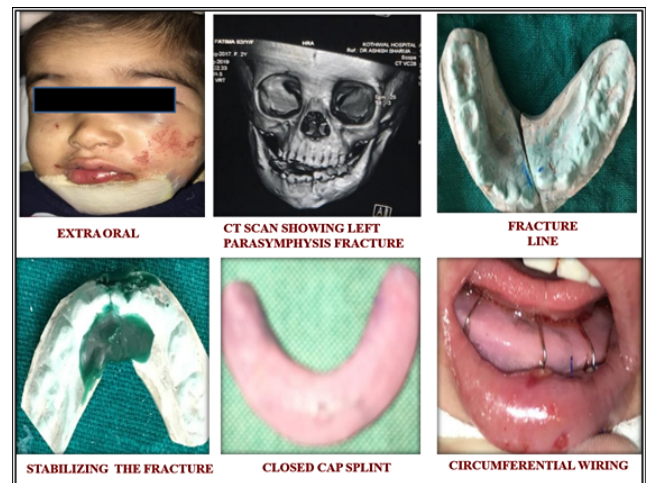


Fig. 6: Case 6 showing closed reduction and stabilization by means of closed cap splint with circum-mandibular wiring under G.A.

3. Discussion

The incidence of facial fractures is lower in paediatric population than in adult population and represents 1-14.7% of the facial fractures in general population. In minimal to moderately displaced paediatric mandibular fractures circumferential wiring with acrylic splints is a definitive treatment modality. The primary concern during treatment planning for pediatric maxillofacial injuries is to prevent injury to the developing dentition.

The management of the pediatric patients with maxillofacial injury should take into consideration:

1. The differences in anatomy and physiology,
2. Particular stage in growth and development,
3. Degree of compliance,
4. The complexity and any concomitant injury,
5. Anatomic sites injured,
6. Time elapsed since injury, and
7. The surgical approach being contemplated.^{1-4,6-8}

The available treatment options for management of the jaw fracture are closed reduction with intermaxillary fixation; open reduction with intra-osseous wires; and open reduction with mini-plates and screws for internal rigid fixation.^{4,6,9} But in children, due to incomplete ossification of the jawbones and the presence of underlying erupting teeth, open reduction with miniplate fixation of the jaw fracture is not usually considered except for highly displaced fractures. However, resorbable plates eliminate the need for the second procedure for the removal of miniplate, but the risk of damage to the tooth buds does exist.^{3,10} Mandibular fractures, which occur during mixed dentition can be associated with subsequently failed eruption of the permanent teeth when fracture line is reduced using an open surgical approach.^{3,9}

Acrylic splints may be labiolingual, cap, intermaxillary, lingual or open cap splints. Labiolingual as well as cap types for the deciduous and mixed dentition. The intermaxillary type is indicated for the loss of multiple teeth. The lingual type for the predicted intraversion of bone fragments. The open cap splint allows early jaw movement which is highly desirable in cases of concomitant subcondylar fracture and hence prevents the development of temporomandibular joint ankylosis.

3.1. Methodology (fabrication of cap splint)

A treatment plan was made to reduce and immobilize the fracture segments using cap splint (closed or open as per case requirement) (Case1-6) and circummandibular wiring. Upper and lower alginate impressions were made under field block local anesthesia. Preoperatively, dental stone cast was poured; fracture line simulated on the cast by cutting with saw; occlusion adjusted and stabilized with wax and plaster of Paris base. A cap splint reinforced with 19G stainless steel (SS) wire was fabricated on the mandibular cast using clear acrylic. The fracture was reduced under general anesthesia and immobilized with the help of open cap splint as seen prepared on the cast. In the submandibular region, stab incisions were made with the help of no. 11 B.P. blade with respect to the deciduous molar region. Mandibular bone awl was passed through the submandibular incision to pass through intraorally on the buccal side of the mandible and splint. A 26G flexible wire was passed through the eyelet of the awl and secured with two turns. The awl was retrieved back upto the lower border of the mandible and guided intraorally on the lingual side of the mandible and splint. The wire was unwinded, and bone awl was removed. The both ends of the wire, that is, buccal and the lingual parts were tied together over the splint after sawing the wire to avoid any soft tissue between the lower border of the mandible and the wire. The same procedure was repeated for following cases (Figure1-7). The patient was advised to be on liquid and soft diet along with the antibiotics and analgesic medications. Oral hygiene instructions were

given which included the supervised brushing; oral rinsing after every meals; and oral irrigation with saline using syringe and blunt needle twice daily by parents (parents were taught the technique how to use for the oral irrigation). The cap splint was removed after 3 weeks. Occlusion was satisfactory, and no other complication was noted except mild inflammation of soft tissue.

4. Conclusion

A conservative approach is a better choice for minimally displaced fractures. The present case series shows that cap splint is a promising fixation technique in terms of occlusion guided fracture reduction, maximum stability during healing period, ease of application and removal, reduced operation time, minimal trauma for adjacent anatomic structures, ease of maintenance of oral hygiene, and comfort for young patients.

5. Source of Funding

None.

6. Conflicts of interest

There are no conflicts of interest.

References

- Baumann A, Troulis MJ, Kaban LB. Facial trauma II: Dentoalveolar injuries and mandibular fractures. *Pediatric Oral and Maxillofacial Surgery*. Philadelphia: Saunders; 2004. p. 445–61.
- Myall RWT, Dawson KH, Egbert MA. Maxillofacial injuries in children. *Fonseca Oral and Maxillofacial Surgery*. vol. 3. Philadelphia: WB Saunders Co; 2000. p. 431–5.
- Kale TP, Urologin SB, Kapoor A, Lingaraj JB, Kotrashetti SM. Open cap splint with circummandibular wiring for management of pediatric mandibular parasymphysis/symphysis fracture as a definitive treatment modality; a case series. *Dent Traumatol*. 2013;29:410–5.
- Zimmermann CE, Troulis MJ, Kaban LB. Pediatric facial fractures: recent advances in prevention, diagnosis and management. *Int J Oral Maxillofac Surg*. 2005;34(8):823–33. doi:10.1016/j.ijom.2005.06.015.
- Das UM, Nagarathna C, Viswanath D, Keerthi R, Gadicherla P. Management of facial trauma in children: A case report. *J Indian Soc Pedod Prev Dent*. 2006;24(3):161–3. doi:10.4103/0970-4388.27900.
- John B, John RR, Stalin A, Elango I. Management of mandibular body fractures in pediatric patients: A case report with review of literature. *Contemp Clin Dent*. 2010;1:291–6.
- Ferreira PC, Amarante JM, Silva PN, Rodrigues JM, Choupina MP, Silva AC, et al. Retrospective study of 1251 maxillofacial fractures in children and adolescents. *Plast Reconstr Surg*. 2005;115:1500–8.
- Haug RH, Foss J. Maxillofacial injuries in the pediatric patient. *Oral Surg Oral Med Oral Pathol Oral Radiol Endod*. 2000;90:126–34. doi:10.1067/moe.2000.107974.
- Aizenbud D, Hazan-Molina H, Emodi O, Rachmiel A. The management of mandibular body fractures in young children. *Dent Traumatol*. 2009;25(6):565–70. doi:10.1111/j.1600-9657.2009.00815.x.
- Vellore KP, Gadipelly S, Dutta B, Reddy VB, Ram S, Parsa A, et al. Circummandibular Wiring of Symphysis Fracture in a Five-Year-Old Child. *Case Rep Dent*. 2013;2013. doi:10.1155/2013/930789.

Author biography

Meenakshi Mahendra Singh, Post Graduate Student

Shagun Rajpal, Post Graduate Student

Neha Priya, Post Graduate Student

Mohd Ghaus Ali, Post Graduate Student

Sana Akhtar, Post Graduate Student

Cite this article: Singh MM, Rajpal S, Priya N, Ali MG, Akhtar S. CAP splint: An armour to safeguard developing dentition in paediatric mandibular fractures- A case series. *IP Indian J Orthod Dentofacial Res* 2021;7(1):77-81.