



Case Report

Orthodontic extrusion a simplistic approach- Case study

Neha Aggarwal¹, Karan Bansal^{2,*}, B P Bansal¹

¹Private Practitioner, Bathinda, Punjab, India

²Adesh Institute of Dental Sciences and Research, Bathinda, Punjab, India



ARTICLE INFO

Article history:

Received 14-08-2020

Accepted 22-08-2020

Available online 04-09-2020

Keywords:

Traumatic injuries

Anterior teeth

Multidimensional approach

Rehabilitation difficulties

Orthodontic extrusion

ABSTRACT

Management of patients with traumatic injuries to the teeth is an essential part of the general dentistry. Anterior teeth with intrusion/ fractures that extend subgingivally require a compounded treatment strategy that acknowledges biological, esthetic and functional components. Treatment of such teeth often requires a multi-dimensional approach. However, teeth with intrusion or crown-root fractures with placement below the gingival attachment or alveolar bone crest present rehabilitation difficulty. This case report presents a 10-year-old male who reported with intruded upper right central incisor causing recurrent lip injury. This case report presents an intruded maxillary central incisors tooth and its management using orthodontic extrusion and maintaining the healthy periodontal tissue and alveolar bone.

© 2020 Published by Innovative Publication. This is an open access article under the CC BY-NC license (<https://creativecommons.org/licenses/by-nc/4.0/>)

1. Introduction

To restore the form and function of a malaligned or rotated anterior tooth, the dentist faces a great challenge. The gingival display of the upper anterior teeth contributes to the micro esthetic pattern of the smile, thus its management is of paramount importance.¹

With the dental implants emerging in the current time, tooth extraction remains the commonest treatment modality. But nevertheless it should be considered as the last option of treatment and every possible attempt should be made to preserve and restore the natural tooth structure. Such treatment regimen involves an interdisciplinary approach including endodontics, periodontal crown lengthening and orthodontic extrusion followed by prosthetic rehabilitation.²

Rotation of the tooth can usually be described as any obvious (about 20°) mesiolingual or distobuccal intra-alveolar displacement of tooth around its longitudinal axis. The prevalence of tooth rotation in Indian population is approximately around 2-5%.

The etiology of the rotation of permanent teeth can be divided into following two groups:

1.1. Pre-eruptive causes

These include traumatic injury to the pre-maxillary region in early childhood displacing and misaligning the developing tooth bud. Sometimes due to the presence of an adjacent pathological condition such as cyst, tumor, odontoma, supernumerary tooth (extra tooth), tooth eruption can be arrested or retarded. Mesiodens (type of supernumerary tooth) can even cause ectopic tooth eruption, displacement or rotation of a central incisor in about 28-63% of cases.

1.2. Post-eruptive causes

In this habitual, mechanical, local and environmental are the causative factors. In a maloccluded dentition with severe crowding, rotated teeth are commonly present, but in cases of presence of abundance of space, rotations can also occur. Environmental factors such as amount of space available for tooth alignment, path of tooth eruption and functional effects created by tongue musculature and lips should also be included in the etiology of tooth rotations, along with

* Corresponding author.

E-mail address: bansalfamilydentals@gmail.com (K. Bansal).

other factors involved in the origin of tooth malpositions³

The treatment of rotated maxillary anterior permanent teeth can be performed by several methods. The preferred treatment of rotated teeth is by use of a fixed orthodontic appliance. Sometimes teeth with a slight rotation, correction can be done with a removable orthodontic appliance such as an appliance with a labial bow and palatal spring.

Adjunctly, for extrusion of rotated teeth, Periodontal crown lengthening is done for the removal of supporting crestal alveolar bone while orthodontic intervention forcibly extrudes the tooth. Both these procedures expose sufficient coronal tooth structure for proper functional and esthetic prosthetic restoration. Sometimes crown lengthening may expose excess of the root structure and therefore in turn might compromise the esthetics.^{4,5}

In this case report, rotated tooth which had intruded or displaced into the alveolar bone, is treated with fixed orthodontics.

2. Case Report

A 10 year-old male reported to the department of pediatric and preventive dentistry with the chief complaint of ulceration on the inner side of the upper lip. Intra oral examination revealed a malposed right upper central incisor, placed high in the labial vestibule. The tooth was severely malaligned with the crown rotation of more than 90 degrees from normal. The palatal surface was facing labially and the root development was in the palatal plane. Considering the unfavourable position of the tooth, Orthodontic extrusion was the treatment planned. Banding of left and right maxillary permanent first molars was done. Bonding was done with 0.012" NiTi wire. Patient was followed up after every one month for 3 months.

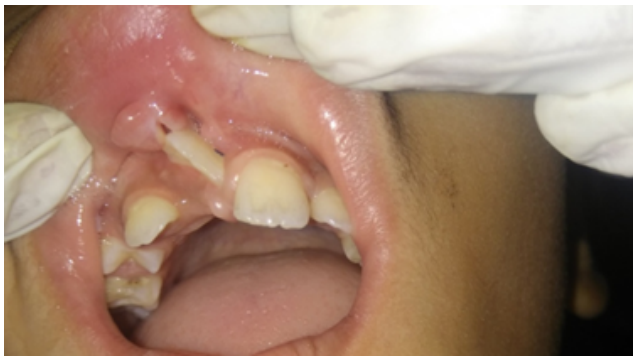

Fig. 1: Preoperative

3. Discussion

Tooth rotation can be defined as an observable mesiolingual or distolingual intra-alveolar displacement of the tooth around its longitudinal axis.

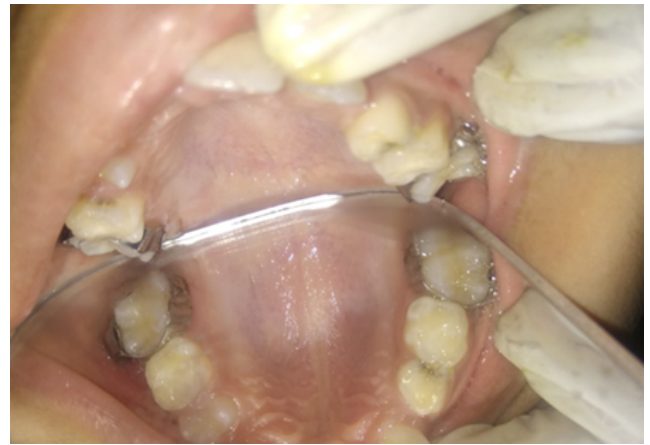


Fig. 2: Intraoperative Banding of teeth

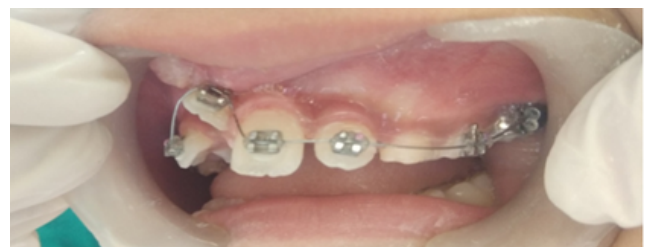

Fig. 3: Intraoperative bonding of anterior teeth.

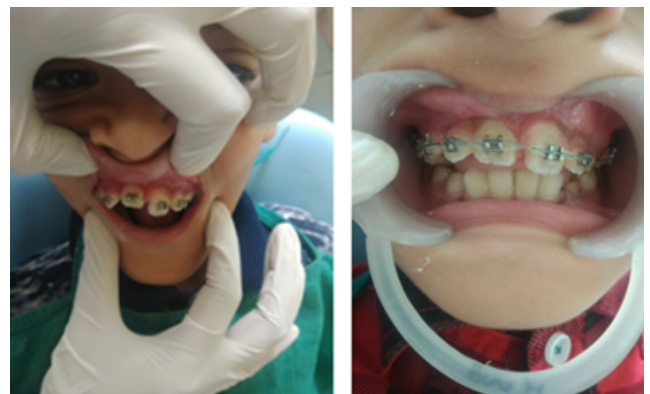

Fig. 4: Postoperative after 1 month.

Very few studies on tooth rotation have revealed about the amount or magnitude and direction of the rotations. Gupta et al. in his study classified the rotation of teeth into three groups: $<45^\circ$, $45-90^\circ$ and $>90^\circ$. He found that rotations were the most common (10.24%) abnormality among the entire sample size and further concluded that the bulk of the tooth rotations were between 45° and 90° , followed by $<45^\circ$ rotations. The most commonly rotated teeth found were the mandibular second premolars, then followed by mandibular first premolars and maxillary central incisors with almost similar prevalence.⁵

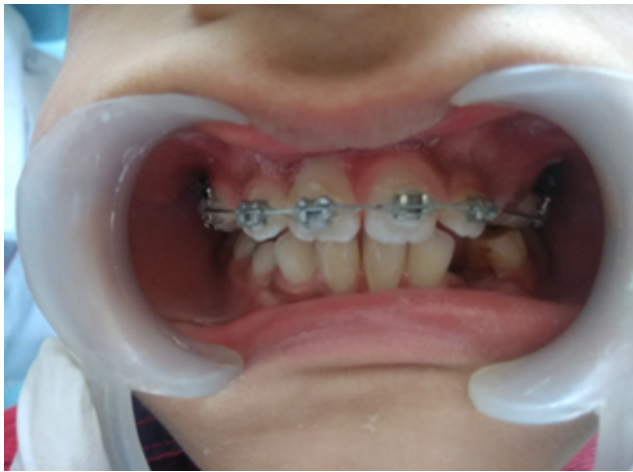

Fig. 5: Postoperative after 2 months.

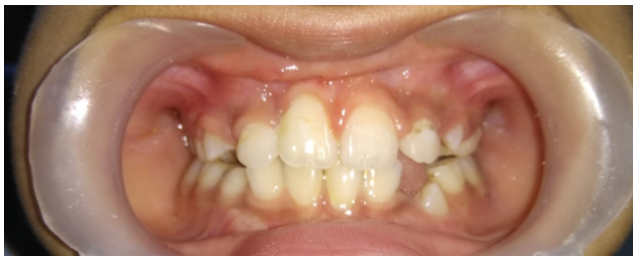

Fig. 6: Postoperative after 3 months.

In orthodontic extrusion, tooth movement is based on the principal of applying the tractional forces in all the regions of the periodontal ligament in order to stimulate marginal apposition of the underlying crestal bone.⁶ As the gingival tissue is attached to the root by a connective tissue, so during the extrusion procedure, the gingiva follows the vertical movement of the root.⁷ Similarly, the alveolus is attached to the root by the periodontal ligament, which is in turn pulled along by the movement of the root.^{8,9}

Variable magnitude of forces are required for the extrusion process. For instance, in order to extrude the fine root of a lower incisor, a 15 gram force and for a molar, a 60 gram forces are sufficient. It is recommended that the maximum force required for a slow movement should not be more than 30 grams whereas rapid movements are achieved with forces more than 50 grams.¹⁰ [Bondemark L].

For rapid orthodontic extrusion, longer retention periods are needed to stabilize the tooth so as to remodel and adapt the periodontium with the new position acquired by the tooth. Ulusoy et al. and Fidel et al. described techniques for extrusion using bonded brackets on the adjacent teeth.^{11,12} However, with bonded brackets, the anterior teeth should be aligned. Furthermore, reciprocating forces of intrusion might act on the adjacent teeth. In the present case, rotated tooth accompanied with intrusion is treated using bonded brackets.

Murali et al. suggested a lingual bracket system using STb brackets.¹³ The similar forces of intrusion are manifested here. Heda et al. also suggested a related technique using a bonded stainless steel wire.¹⁴ In this technique, vertical steps were given to prevent the rolling of the wire. Furthermore, in the present case there was no need for aligning the anterior teeth as the rigid wire was bonded chair side directly and here Begg brackets were used as attachments.

4. Conclusion

A multi-disciplinary approach is required for the alignment of tooth intruded at a subgingival level because the margin of restoration should ideally be supragingival. In this clinical report, a treatment modality for forced tooth eruption which minimizes treatment time and increases ease of use was deployed. This technique for forced eruption was also aimed to have a better esthetic result and patient appreciation.

References

1. Delivanis P, Delivanis H, Kuftevec MM. Endodontic-orthodontic management of fractured anterior teeth. *J Am Dent Assoc.* 1978;97(3):483–5.
2. Johnson RH. Lengthening clinical crowns. *J Am Dent Assoc.* 1990;121:473–6.
3. Ivey DW, Calhoun RL, Kemp WB, Dorfman HS, Wheless JE. Orthodontic extrusion: Its use in restorative dentistry. *J Prosthetic Dent.* 1980;43(4):401–7.
4. Fournier A. Orthodontic management of subgingivally fractured teeth. *J Clin Orthod.* 1981;15:502–3.
5. Gupta SK, Saxena P, Jain S, Jain D. Prevalence and distribution of selected developmental dental anomalies in an Indian population. *J Oral Sci.* 2011;53(2):231–8.
6. Bach N, Baylard JF, Voyer R. Orthodontic extrusion: Periodontal considerations and applications. *J Can Dent Assoc.* 2004;70:775–80.
7. Bielicka B, Bartkowiak M, Urban E, Tomasz M. Holistic approach in the management of subgingivally fractured premolar tooth: Case report. *Dent Med Probl.* 2008;45:211–4.
8. Minsk L. Orthodontic tooth extrusion as an adjunct to periodontal therapy. *Compend Contin Educ Dent.* 2000;21:768–70.
9. Reitan K. Clinical and histologic observations on tooth movement during and after orthodontic treatment. *Am J Orthod.* 1967;53(10):721–45.
10. Bondemark L, Kurol J, Hallonsten AL, Andreassen JO. Attractive magnets for orthodontic extrusion of crown-root fractured teeth. *Am J Orthod Dentofac Orthop.* 1997;112(2):187–93.
11. Ulusoy A. Indirect composite restoration of a crown fracture. *J Dent Child.* 2012;79(2).
12. Fidel SR, Fidel-Junior RAS, Sassone LM, Murad CF, Fidel RAS. Clinical management of a complicated crown-root fracture: a case report. *Braz Dent J.* 2011;22(3):258–62.
13. Murali RV, Rajashekhar L, Rajalingam S. Extrusion of fractured anterior tooth - An invisible approach. *Indian J Multidiscip Dent.* 2011;1.
14. Heda CB, Heda AA, Kulkarni SS. A multi-disciplinary approach in the management of a traumatized tooth with complicated crown-root fracture: A case report. *J Indian Soc Pedod Prev Dent.* 2006;24(4):197–200.

Author biography

Neha Aggarwal Private Practitioner

Karan Bansal Senior Lecturer

B P Bansal Private practitioners

Cite this article: Aggarwal N, Bansal K, Bansal BP. **Orthodontic extrusion a simplistic approach- Case study.** *IP Indian J Orthod Dentofacial Res* 2020;6(3):177-180.