



## Original Research Article

## Role of flexible bronchoscopy in ICU setting – 3 year study

S Veni Krishna<sup>1</sup>, Mathew Ninan<sup>2,\*</sup>, J Balachandran<sup>1</sup><sup>1</sup>Dept. of Pulmonary Medicine, Travancore Medical College, Kollam, Kerala, India<sup>2</sup>Dept. of Pulmonary Medicine, Pushpagiri Medical College, Thiruvalla, Kerala, India

## ARTICLE INFO

## Article history:

Received 29-07-2020

Accepted 10-08-2020

Available online 16-09-2020

## Keywords:

Bronchoscopy

Critical care

Broncho alveolar lavage

## ABSTRACT

**Background:** Flexible bronchoscopy (FB) is a powerful investigatory tool in patients with respiratory diseases. FB helps in direct visualisation of the upper and lower airways and has role in management of various pulmonary disorders. Its utility in critical care is increasing owing to its diagnostic and therapeutic role. This study aimed at understanding the clinical profile of critically ill ICU patients who required bronchoscopy during ICU stay. Data included demographics, indications, complications and microbiological isolates.

**Materials and Methods :** This is a retrospective observational study conducted in 53 patients admitted at multidisciplinary ICU of a tertiary care teaching hospital, who required ICU bronchoscopy as an investigatory tool. Bronchoscopy was performed by consultants of Department of pulmonary medicine who are trained in performing flexible bronchoscopy.

**Results:** There were total 53 patients who required ICU bronchoscopy. Mean age of the study population was 58.08 years with standard deviation of 13.16. Maximum age of study subject was 82 years and minimum age was 21 yrs. Out of 53 subjects 35 were males (66%) and 18 were females (34%). 62.3% of subjects were on mechanical ventilator during procedure. There were complications like hypoxemia, bleeding, hypotension with zero mortality. BAL was the commonest procedure performed. There was no statistical correlation between the indication and complications, and also no correlation between age and the complication.

**Statistical Analysis.** Data was entered into Microsoft excel sheet and data analysed using Statistical Package for Social sciences (SPSS) version 16. Descriptive statistics such as frequency, percentage, mean and standard deviations were used. Quantitative data are expressed as mean  $\pm$  SD, whereas qualitative data are expressed as numbers and percentages (%). Chi square test was used to find the statistical significance and  $p < 0.05$  was considered as statistically significant.

**Conclusion:** Improved knowledge and awareness of the anatomy and procedure skills make FB a safe procedure even in high risk patients. This article highlights safety and benefits of FB in critically ill patients.

© 2020 Published by Innovative Publication. This is an open access article under the CC BY-NC license (<https://creativecommons.org/licenses/by-nc/4.0/>)

## 1. Introduction

Flexible bronchoscopy (FB) is an important diagnostic tool in respiratory medicine.<sup>1</sup> Its use in critical care is also increasing owing to its diagnostic and therapeutic benefits.<sup>1</sup> This study looks into the common indications of FB in intensive care unit (ICU) and the complications encountered in adult critical care patients.

FB is an invasive procedure done for evaluation of respiratory diseases. Various procedures can be done via FB which includes exploration of tracheobronchial tree, broncho alveolar lavage (BAL), brushing, and forceps sampling. Indications of each procedures depends on primary diagnosis.<sup>2</sup> Forceps biopsy can be trans bronchial lung biopsy or endobronchial biopsy. Indications for FB in ICU includes removal of mucous plugs, blood clots, management of massive hemoptysis and for obtaining samples for microbiological samplings. In pneumonia, BAL

\* Corresponding author.

E-mail address: [mathewninan@gmail.com](mailto:mathewninan@gmail.com) (M. Ninan).

is the commonly performed FB procedure. During FB partial obstruction in the airways results in increased airway resistance and thereby causes gas exchange abnormalities. Further bronchoalveolar lavage (BAL) during FB results in partial flooding of the alveoli with washing out of the surfactant and thus increasing atelectasis. These will result in gas exchange abnormalities and respiratory distress even in healthy subjects. These effects are maximised when the procedure is performed in critically ill patients. In spite of all these FB is a relatively safe procedure in critically ill patients. In experienced hands with good awareness of anatomy of bronchial tree, bronchoscopy can be performed safely in high risk critical patients.<sup>3,4</sup>

This study highlights the importance of FB in critical care settings and also focus on its indications and complications associated with the procedure.

## 2. Objectives of study

1. To study the clinical profile of ICU bronchoscopy patients.
2. To study the complications associated with ICU bronchoscopy.

## 3. Materials and Methods

### 3.1. Study Design

This is a retrospective observational study.

### 3.2. Study Setting

Multidisciplinary ICU of tertiary care teaching hospital, which works as a closed unit with certified critical care physicians. Bronchoscopy will be performed by consultants of Department of pulmonary medicine who are trained in performing flexible bronchoscopy.

### 3.3. Study Period

1st April 2017 till 1st of Feb 2020

### 3.4. Study subjects

This study was carried out in patients admitted in ICU who underwent FB during ICU stay. Data was collected from inpatient files and computerized database. Data consisted of clinical profile, age, gender, mode of ventilation during FB, indications of FB, results and complications related to the procedure.

### 3.5. Procedures

All procedures were performed according to the Pulmonology manual. This included sedation as per intensivist decision, examination of the upper airway and tracheobronchial tree, bronchial lavage, bronchial brushing

(protected specimen brushing), bronchoalveolar lavage (BAL), forceps sampling as required. A 6.4 mm outer diameter flexible bronchoscope (Pentax) was used for procedure.

BAL was the technique used to collect samples for quantitative cultures when FB indication was suspicion of lower respiratory tract infection. A positive BAL culture was that determined a change in antimicrobial therapy and was defined as useful in cases of pneumonia.<sup>5</sup>

Complications of FB procedure included bleeding from tracheobronchial tree, hypotension (defined for BP less than 90/60mmHg during or immediately after procedure), hypoxemia (when oxygen saturation of less than 90% from baseline during or immediately after procedure).

### 3.6. Statistical Analysis

Data was entered into Microsoft excel sheet and data analysed using Statistical Package for Social sciences (SPSS) version 16. Descriptive statistics such as frequency, percentage, mean and standard deviations were used. Quantitative data are expressed as mean  $\pm$  SD, whereas qualitative data are expressed as numbers and percentages (%). Chi square test was used to find the statistical significance and  $p < 0.05$  was considered as statistically significant.

## 4. Results

Total of 250 patients were admitted under ICU during the above study period. Out of which 53 patients underwent flexible bronchoscopy in ICU. Of 53 patients, 51 were admitted with medical causes and rest 2 were surgical cases. All bronchoscopies were performed by a pulmonologist. And all cases were supervised and sedation given by the critical care team.

Mean age of the study population was 58.08 years with standard deviation of 13.16. Maximum age of study subject was 82 years and minimum age was 21 years (Table 1). Out of 53 subjects 35 were males (66%) and 18 were females (34%).

Majority of ICU patients were on mechanical ventilator at the time of procedure. So, bronchoscopy can be done in critically ill mechanically ventilated patient (Table 2). For 30 mechanically ventilated subjects, FB was done via endotracheal tube. Rest 3 patients (5.7%) it was done through tracheostomy tube.

Indications of bronchoscopy were listed under various causes which included collapse, consolidation, mass lesions, hemoptysis and diffuse parenchymal lung disease (Table 3). Among the 36 cases of consolidation, FB was done to obtain BAL for microbiological sampling. Out of which 30 positive cultures were available.

Among FB procedures, BAL was the commonly performed FB procedure. It was performed on all 51

subjects. BAL aids in obtaining samples for microbiological diagnosis. Mucous plug removal which was done in 45.3 % of cases offered therapeutic benefit also to the patient. (Figure 1)

Common microbiological organisms isolated are listed under Table 4. BAL culture was negative for pathogens in 13 subjects. In 2 cases, there were mixed growth of mycobacterium tuberculosis with klebsiella Pneumonia and Acinetobacter baumannii with klebsiella.

There was no statistical correlation between age and complications and also no correlation between indications of FB and the complications (Table 5)

**Table 1:** Age wise distribution of cases

Age Group	Frequency(n=53)	Percentage
20-40	6	11.3
40-60	16	30.2
>60	31	58.5

**Table 2:** Mode of ventilation in study subjects

Mode of ventilation	Number of subjects(percentage)
Mechanical ventilation	33(62.3%)
Oxygen via face mask/ nasal prongs	13(24.5%)
Noninvasive ventilation	7(13.2%)

**Table 3:** Indications for FB in study subjects

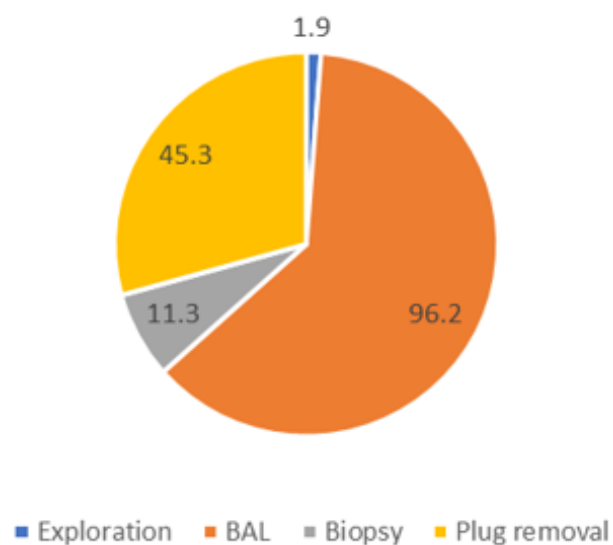
Indications	Frequency (n=53)	Percentage
Collapse	24	45.3
Consolidation	36	67.9
Hemoptysis	8	15.1
Interstitial lung disease	1	1.9
Lung mass	2	3.8
Bronchiectasis	4	7.5

**Table 4:** Pathogens isolated in BAL positive cases

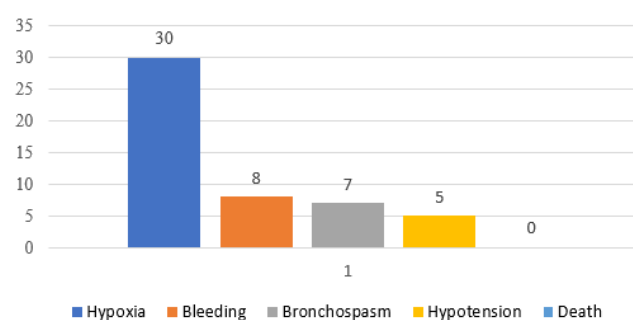
Pathogen	Frequency (n=51)	Percentage
Pseudomonas aeruginosa	10	19.6
Klebsiella Pneumonia	14	27.5
AcinetobacterBaumannii	8	15.7
Mycobacterium Tuberculosis	5	9.8
Aspergillus	4	7.8

## 5. Discussion

Flexible bronchoscopy (FB) is a widely used invasive procedure for pulmonary diseases. FB has become an unavoidable tool in ICU setting due to diagnostic and



**Fig. 1:** Flexible bronchoscopy procedures done in subjects in percentage.



**Fig. 2:** Complications associated with Flexible bronchoscopy

therapeutic utility. Benefit and safety of bronchoscopy are the two main factors which contributed to its increasing use in intensive care units. Patients in ICU not only suffer from their critical care illness but also are prone to develop secondary processes like nosocomial infections, lung collapse.<sup>6</sup> Pneumonia is the second most common nosocomial infection in critically ill patient.<sup>5,7</sup> Its incidence ranges from 5% to 67% depending on case mix and diagnostic criteria used.<sup>8</sup>

The common indications for ICU FB in other studies included Pneumonia (immunocompromised host, nosocomial or ventilator associated pneumonia, severe community acquired), Diffuse or focal lung disease (infiltrates or mass lesions) Airway trauma (intubation injury, blunt thoracic injury, postoperative), Atelectasis (roentgeno graphic), excess airway secretions, aspiration pneumonia, and massive haemoptysis.<sup>9</sup> In our present study, consolidation was the commonest indication for FB. This was followed by collapse, where mucous plug removal

**Table 5:** Correlation between age and complications & indications and complications.

Age group	Complications		Chi square value	p value
	Yes	No		
<b>20-40</b>	5(12.8%)	1(7.1%)	0.492	0.782
<b>40-60</b>	11(28.2%)	5(35.7%)		
<b>&gt;60</b>	23(59.0%)	8(57.1%)		
<b>Collapse</b>			2.144	0.143
Yes	20(51.3%)	4(28.6%)		
No	19(48.7%)	10(71.4%)		
<b>Consolidation</b>			0.990	0.320
Yes	25(64.1%)	11(78.6%)		
No	14(35.9%)	3(21.4%)		
<b>Mass</b>			0.595	0.441
Yes	1(2.6%)	1(7.1%)		
No	38(97.4%)	13(92.9%)		
<b>Bronchiectasis</b>			1.553	0.213
Yes	4(10.3%)	0(0.0%)		
No	35(89.7%)	14(100%)		
<b>DPLD</b>			0.366	0.545
Yes	1(2.6%)	0(0.0%)		
No	38(97.4%)	14(100%)		
<b>Hemoptysis</b>			0.939	0.333
Yes	7(17.9%)	1(7.1%)		
No	32(82.1%)	13(92.9%)		

resulted in therapeutic benefit also. Hence therapeutic benefit was achieved in 45.3% of collapse cases in our study, which was again similar to the study by Tai et al and Turner et al which showed 47% and 75% of therapeutic benefits.<sup>9-11</sup>

62.3% of subjects (33 patients) were on mechanical ventilation and FB was safely performed with no major complications. This was almost similar with other studies which highlighted that 65% and 79% of FB in ICUs were performed on patients on mechanical ventilation.<sup>9,11,12</sup> FB is mainly used in ventilated patients for BAL for microbiological analysis. In mechanically ventilated patients FB was performed via endotracheal tube in majority of cases. Internal diameter of ETT should be at least 2mm larger than the bronchoscope diameter.

The risk of major complications with FB in ICU is 0.08% to 2% and mortality risk is extremely low (0.01% to 0.05%).<sup>13-15</sup> Our study also reported zero mortality in all FB cases. Bleeding from tracheobronchial tree was another commonly encountered complication, which can be minimal to significant bleed. A significant bleed is defined as blood loss of more than 50ml. Present study showed bleeding from TB tree in 17.9% of subjects but none had significant loss. These data highlights the fact that FB is a safe and yielding test in critically ill patients.

Owing to the gas exchange abnormalities caused during FB, it is advisable to avoid FB in extreme situations like acute myocardial infarction, very severe refractory hypoxemia, intense hemodynamic instability and uncontrollable arrhythmias. Even in these extremely high risk

candidates need for FB can be decided based on risk benefit ratio like in cases of whole lung collapse, where in FB will be highly beneficial.<sup>16</sup>

Other minor complications included transient bronchospasm due to airway irritation. This was mainly encountered in prior airway disease patients. Patients also experienced post bronchoscopy fever, which was selflimited. In our study it was noted in 10% of patients. Another study by Du Rand et al also reported 9 to 16% fever following bronchoscopy.<sup>17</sup> Reason for fever was related to transient bacteremia and from release of inflammatory mediators.

Previously open lung biopsies were considered as the initial diagnostic procedure of choice for patients with AIDS (acquired immunodeficiency syndrome) or organ transplants and diffuse pulmonary infiltrates in immunocompromised patients.<sup>18,19</sup> Now it has been replaced completely by FB as diagnostic yields of BAL for *Pneumocystis carinii* is close to 100%, and for other pathogens it ranges from 60% to 85%. Flexible bronchoscopy has been also found beneficial in other situations like difficult intubation cases and for visual control during percutaneous tracheostomy done bedside in ICU.

Major limitation of present study is that it was entirely conducted at a single tertiary care facility. Ideally, this study should be expanded to a multicentre analysis and should include data from the general population. Another limitation of the study was the lower number of cases involved, which makes the generalization difficult.

## 6. Conclusion

This study concluded that FB in ICU provides valuable diagnostic information and more importantly has therapeutic utility. Now FB is an inevitable part in everyday life of a pulmonologist as well as critical care physicians. Safety and benefit are the hallmark in its widespread use. It can be performed in almost all critically ill patients with clinical indications. FB should be performed only by experienced bronchoscopists. It is recommended that guidelines must be formulated regarding ICU bronchoscopy to derive maximal benefits and minimise the risk to the patients.

## 7. Acknowledgement

None.

## 8. Source of Funding

None.

## 9. Conflict of Interest

None.

## References

1. Jolliet P, Chevrolet JC. Bronchoscopy in the intensive care unit. *Intensive Care Med*. 1992;18(3):160–9.
2. Kabadayi S. Bronchoscopy in critical care Education. *Br J Anaesth*. 2017;17(2):48–56.
3. Mehta AC, Tai D, Khan SU. Bronchoscopy: Common problems and solutions. *Mediguide Pulm Med*. 1996;3:1–7.
4. Castro FRD, Violan JS. Flexible bronchoscopy in mechanically ventilated patients. *J Bronchol*. 1996;3:64–8.
5. Richards JR, Edward. Nosocomial infections in medical Intensive care units in US. *Crit Care Med*. 1999;27:887–92.
6. Steven M, Truwit JD. Ventilator - Associated pneumonia: Diagnosis, treatment and Prevention. *Clin Microbiol Rev*. 2006;19(4):637–57.
7. Torres A, Michael S. International ERS/ESICM/ESCMID/ALAT guidelines for the management of hospital-acquired pneumonia and

- ventilator-associated pneumonia. *Eur Respir J*. 2017;50:1700582.
8. Barbier F, Andremont A, Wolff M, Bouadma L. Hospital-acquired pneumonia and ventilator-associated pneumonia. *Curr Opin Pulm Med*. 2013;19(3):216–28.
9. Tai D. Bronchoscopy in the Intensive Care Unit (ICU). *Ann Acad Med*. 1998;27:529–52.
10. Turner JS, Willcox PA, Hayhurst MD, Potgieter PD. Fiberoptic bronchoscopy in the intensive care unit—A prospective study of 147 procedures in 107 patients. *Crit Care Med*. 1994;22(2):259–64.
11. Olopade CO, Prakash UBS. Bronchoscopy in the Critical-Care Unit. *Mayo Clin Proce*. 1989;64(10):1255–63.
12. Lindholm CE, Ollmann B, Snyder J, Millen E, Grenvik A. Flexible fiberoptic bronchoscopy in critical care medicine. *Crit Care Med*. 1974;2(5):250–61.
13. Castro FRD, Violan JS. Flexible bronchoscopy in mechanically ventilated patients. *J Bronchol*. 1996;3:64–8.
14. Dellinger RP, Bandi V. Fiberoptic Bronchoscopy in The Intensive Care Unit. *Crit Care Clin*. 1992;8(4):755–72.
15. Silver MR, Balk RA. Bronchoscopic Procedures in the Intensive Care Unit. *Crit Care Clin*. 1995;11(1):97–109.
16. Stevens RP, Lillington GA, Parsons GH. Fiberoptic bronchoscopy in the intensive care unit. *Heart Lung*. 1981;10:1037–45.
17. Blaikley DR. Summary of the British thoracic society guidelines for diagnostic flexible bronchoscopy in adults. *Thorax*. 2013;68:786–7.
18. Baselski VS, Wunderinkrg. Bronchoscopic diagnosis of pneumonia. *Clin Microbiol Rev*. 1994;7:533–58.
19. Dunagan DP, Baker AM, Haponik EF, Hurd DD. Bronchoscopic Evaluation of Pulmonary Infiltrates Following Bone Marrow Transplantation. *Chest*. 1997;111(1):135–41.

## Author biography

**S Veni Krishna** Assistant Professor

**Mathew Ninan** Associate Professor

**J Balachandran** Professor

**Cite this article:** Krishna SV, Ninan M, Balachandran J. **Role of flexible bronchoscopy in ICU setting – 3 year study.** *IP Indian J Immunol Respir Med* 2020;5(3):185-189.