



Case Report

Management of tracheo-bronchial foreign bodies at a tertiary care hospital in Eastern part of India

Chinmaya Sundar Ray¹, Krishna Arpita Sahoo^{2,*}

¹Dept. of ENT, P.R.M Medical College, Baripada, Odisha, India

²Dept. of ENT, S.C.B Medical College, Cuttack, Odisha, India



ARTICLE INFO

Article history:

Received 05-05-2020

Accepted 15-05-2020

Available online 15-06-2020

Keywords:

Foreign body aspiration

Rigid bronchoscopy

Trachea

Bronchus.

ABSTRACT

Introduction: Accidental Foreign body aspiration is common in children presenting to emergency outpatient department. Early diagnosis from clinical and radiological investigations is pivotal for successful removal of aspirated foreign body. We here report 35 cases of foreign body aspiration with respect to clinical features, type and location of foreign body, complications during bronchoscopy.

Aims & Objectives : To evaluate the clinical presentation, diagnosis & management of tracheo-bronchial foreign bodies in a tertiary care hospital

Materials & Methods: This was a retrospective study of 35 cases of foreign body removal done between January 2018 to January 2020. We included those cases that had history of aspiration, sudden onset of breathlessness or choking sensation in a healthy person, recurrent respiratory infections with clinical or radiological evidence, and suspicion of foreign body. Every case was documented with respect to age, sex, nature, site of foreign body lodgement, duration between inhalation or symptoms and admission in a hospital, clinical symptoms and signs, chest radiography findings, results and complications of bronchoscopy.

Results: The most common age group was between 1-6 years. Most of the patients attended hospital after 7 days of aspiration without any emergencies. History of aspiration and respiratory distress were the common presentation. Fever was present in those who presented late to the emergency department. About 25 cases (71.4%) had diminished or absent breath sounds followed by 12 cases (50%) of stridor, 15 cases (42.8%) diminished percussion notes. The common radiographic finding is obstructive emphysema and commonest site was right bronchus. Most of the foreign bodies were vegetative in nature.

Conclusion: Early investigation with bronchoscopy is warranted when a strong clinical suspicion exists for foreign body aspiration, since bronchoscopy helps to resolve the symptoms quickly and prevent further complications

© 2020 Published by Innovative Publication. This is an open access article under the CC BY-NC license (<https://creativecommons.org/licenses/by-nc/4.0/>)

1. Introduction

Aspiration of foreign body is common in children below 3 years of age (79%),¹ with a higher incidence in boys (63%).² Sometimes, FBA can be a significant cause of mortality in children younger than 6 years.³ This higher incidence in children has also been confirmed in a retrospective Brazilian study.⁴ Accidental foreign body aspiration is a very frequently occurring situation

in paediatric age which may produce a great variety of symptoms of varying severity, or it even can be asymptomatic.

Around 40 % of patients present with breathlessness, coughing, wheezing, choking and decreased air inflow^{1,5,6}. Some patients may present with fever, cyanosis, stridor, atelectasis, chronic coughing, recurrent pneumonia, and even death².

Diagnosis of FBA begins with patient history and clinical signs and can be strengthened by radiographic findings. The most common indicators are air trapping,

* Corresponding author.

E-mail address: drkrishna52@gmail.com (K. A. Sahoo).

signs of infection, atelectasis, or radioopaque foreign body⁷. However, these findings can also occur in a patient without FBA. In addition, 24% of the patients with an endoscopically confirmed foreign body do not present with any abnormality at radiography. Radiology of thorax is used to find the location of foreign body. Hence, it is essential to perform bronchoscopy in children with all those clinical symptoms and signs, regardless of radiographic findings⁸. Multidisciplinary team work is essential for early and successful removal of foreign body. We report 35 cases of accidental vegetative and metallic foreign body aspiration.

2. Materials and Methods

This was a retrospective analysis of 35 cases of foreign body removal done between January 2018 to January 2020. The present study was approved by the ethical committee of this institution. We included those cases that had history of aspiration, sudden onset of breathlessness or choking sensation in a healthy person, recurrent respiratory infections with clinical or radiological evidence, and suspicion of foreign body. Patients with bronchial asthma, acute laryngo-tracheobronchitis, COPD, bronchiectasis were excluded from the study. Informed consent was taken from each and every patient.

Every case was documented with respect to age, sex, nature, site of foreign body lodgement, duration between inhalation or symptoms and admission in a hospital, clinical symptoms and signs, chest radiography findings, results and complications of bronchoscopy. Rigid bronchoscopy was performed after thorough clinical evaluation and radiography. In some patients with chronic or subtle symptoms with no history of foreign body aspiration, or patients with symptoms unresponsive to bronchodilator therapy, or history consistent with aspiration but no physical or x-ray signs, flexible bronchoscopy was performed to rule out any other lung pathology.

Foreign body removal was done using rigid bronchoscope under general anaesthesia, with induction by propofol, relaxation and apnoea with scoline, oxygenation with jet ventilation. Continuous monitoring of electrocardiogram, blood pressure, oxygen saturation by pulse oxymetry and precordial stethoscope auscultation was done. On visualization of the foreign body it was grasped with adequate forceps for each case and removed.

The bronchoscope was reintroduced for removal of any remaining fragments, aspiration of secretions and evaluation of any mucosal oedema or any injury. Intravenous steroids along with antibiotics were administered to decrease post-operative sub-glotticoedema. In few cases of vegetative foreign bodies tracheostomy was done as they get swelled up due to their hygroscopic action and successful decannulation was done on fifth post-operative day. Chest x-ray is repeated after 48 hours. Most of our patients were discharged on fifth post-operative day.

3. Results

35 patients of different age groups who underwent bronchoscopy for removal of foreign bodies in the airways were evaluated. The period of study was 2 years. The most common age group was between 1-6 years. Males have outnumbered females. (Table 1) Most of the patients attended hospital after 7 days of aspiration without any emergencies. 8 patients came immediately after aspiration with a positive history of aspiration of foreign bodies by parents and relatives. (Table 2) History of aspiration and respiratory distress were the common presentation. Fever was present in those who presented late to the emergency department. (Table 3) About 25 cases (71.4%) had diminished or absent breath sounds followed by 12 cases (50%) of stridor, 15 cases (42.8%) diminished percussion notes. (Table 4)

Asymptomatic and clinically stable patients can present immediately after a choking event and with normal imaging. Inspiratory and expiratory or decubitus films of the chest may be helpful in establishing the diagnosis of FBA. (Figures 11, 12, 13 and 14) The common radiographic finding is obstructive emphysema. Other features are hyperinflated lung of the opposite side, Atelectasis, consolidation or a contralateral mediastinal shift. The commonest site of foreign body is right bronchus followed by left bronchus. (Tables 5 and 6) Most of the foreign bodies are vegetative in nature. (Figures 1, 2, 3, 4, 5, 6, 7, 8, 9 and 10) They have to be removed under general anaesthesia using rigid bronchoscopes. (Figure 15) The commonest foreign body to be removed was a groundnut. (Table 7)

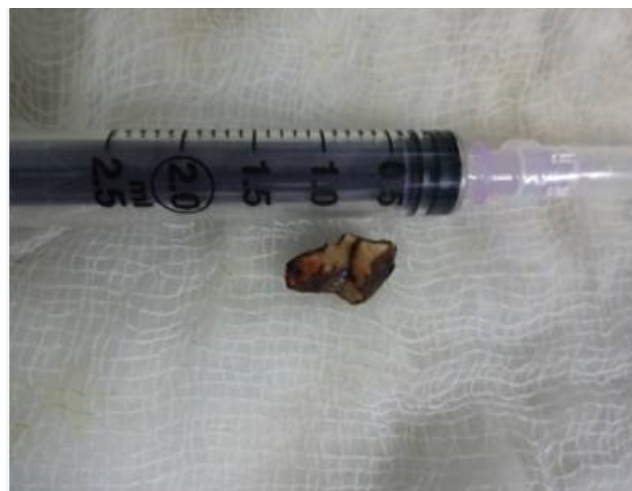

Fig. 1: Betel nut

3.1. Complications

In 35 cases, it was possible to remove the foreign bodies successfully. In 3 cases bronchoscopy related complications such as laryngospasm with bradycardia, laryngospasm with

Table 1: Age and Gender distribution

Age (Years)	No. of patients	Percentage (%)
0-2	16	46
2-4	8	23
4-5	5	14
5-15	3	8.5
>15	3	8.5
Total	35	100 %
Gender (Male/Female)	19 / 10	65.5 / 34.5

Table 2: Time taken between aspiration and removal of foreign body

Days	No. of patients	Present study (%)	Srppnath et al (%) ⁹
0-1	8	23	14
1-7	14	40	28
7-14	7	20	32
15-30	5	14	25
>30	1	3	1

Table 3: Symptoms presented by the patient

Symptoms	No. of Patients	Present study (%)	Rajasekaran et al (%) ⁵
History of aspiration	30	86	62
Breathlessness	24	69	68
Wheezing	12	34	54
Cough	26	74	72

Table 4: Presenting signs

Signs	No. of patients	Present study (%)	Naragund et al (%) ¹⁰
Diminished breath sounds	25	71.4	72.7
Decreased percussion note & Crepitation	15	42.8	45.5
Stridor	22	62.9	50
Rhonchi	14	40	54.5

Table 5: Radiological findings

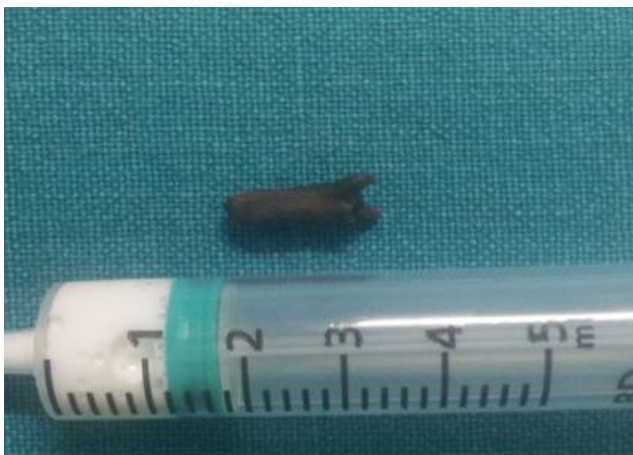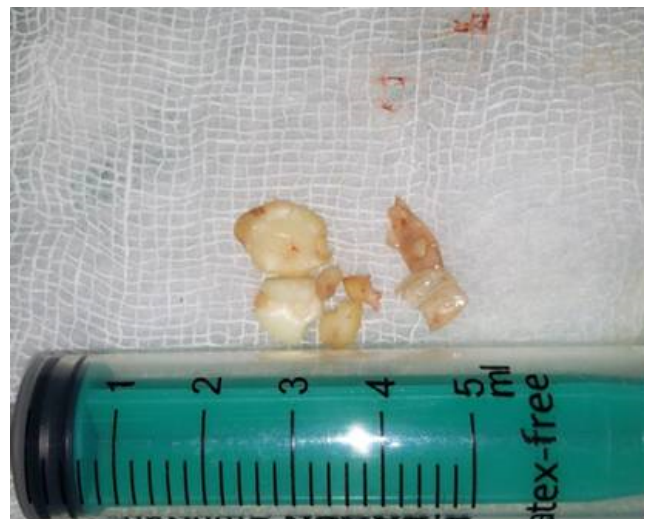
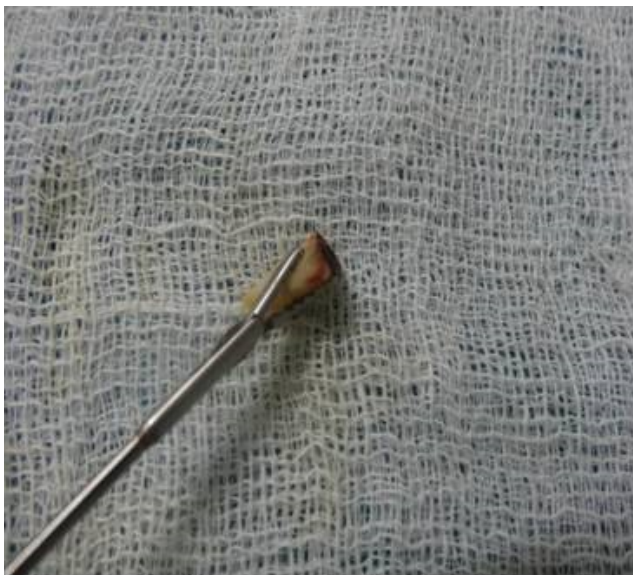Chest Radiology	No. of patients	Present study (%)	Rajasekaran et al (%) ⁵
Obstructive emphysema	18	51	58
Consolidation	7	20	6
Collapse	2	5	8
Bronchopneumonia	4	12	14
Normal X-ray	4	12	10

Table 6: Location of foreignbody

Site of foreign body	No. of patients	Present Study (%)	Srppnath et al ⁹
Right bronchus	17	49	46
Left bronchus	14	40	46
Subglottis	2	6	2
Trachea	2	6	6

Table 7: Types of foreignbody removed by bronchoscopy

Nature of foreignbody	No. of patients
Ground nut	8
Cashewnut	1
Betelnut	6
Plastic pencap/ part	4
Tamarind seed	3
PVC Tracheostomy tube	2
Custard apple seed	2
Yellow dal gram	1
Coconut Kernel	3
Clove	1
Whistle	1
Board pin	2
Metallic screw	1
Total	35

**Fig. 2:** Clove**Fig. 4:** Groundnut**Fig. 3:** Cocconut Kernel

desaturation and pneumothorax was seen respectively. Patients were kept in ICU under keen observation and were then discharged.

4. Discussion

The clinical presentation of patient depends on type of foreign body, site of lodgement, size of foreign body, duration since hospital admission¹¹. Children below 2 years are more commonly affected. This age group is mostly affected because of predisposing factors like the smaller diameter of airway, the tendency to put objects into the mouth, immature dentition, immature swallowing coordination and activity while eating¹². In older children, anatomic abnormalities and neurologic disorders predispose to FBA¹³. It was found that in a study by Srppnath and VinayMahendrakarout of 225 patients, 50 cases (64%) of foreign body aspiration were found in children below

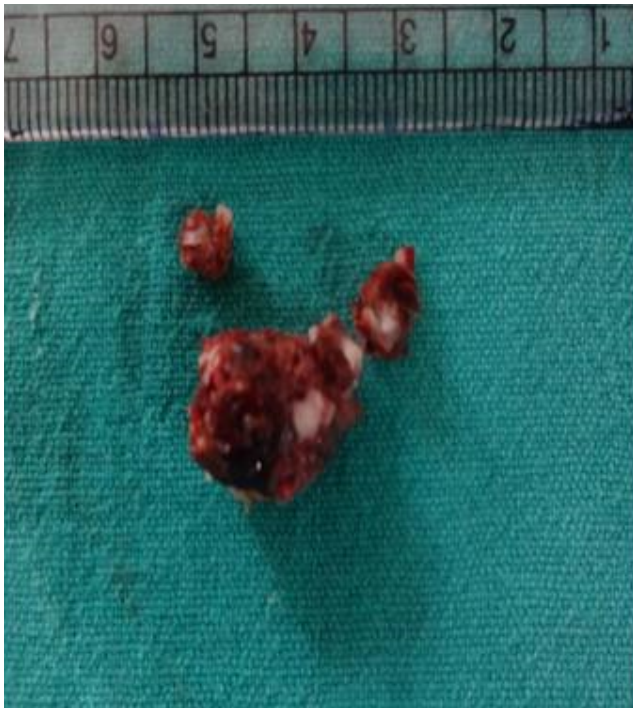

Fig. 5: Tamarind

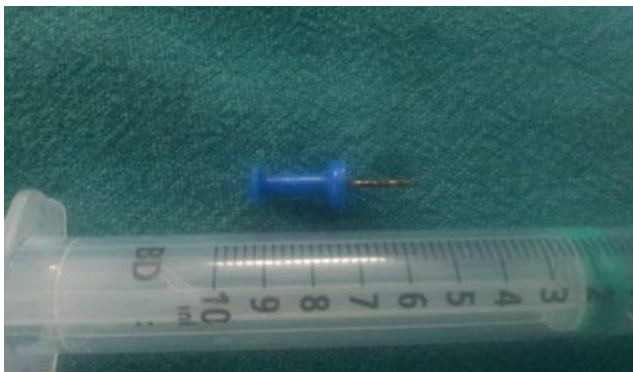

Fig. 6: Board Pin

2 years of age group with 93 cases (20%) in the age group of 2-4 years⁹. The male: female ratio was 1.9:1.

It was observed that 23% of patients presented to ENT OPD within 24 hours of aspiration and maximum no. of patients (40%) consulted after one week with delayed symptoms of respiratory tract infections, fever, Pneumonia, respiratory distress. Most of the paediatric patients seek treatment in paediatric department. Misdiagnosis, lack of suspicion by the parents, fatigability of cough reflex after an acute choking episode, delayed respiratory symptoms are the factors causing a delay in proper treatment^{4,14}. 30 (86 %) out of 35 cases had positive history of foreign body aspiration. But the study done by Rothmann and Boeckman¹⁵ shows that out of 225 cases, 168 (74.9%)

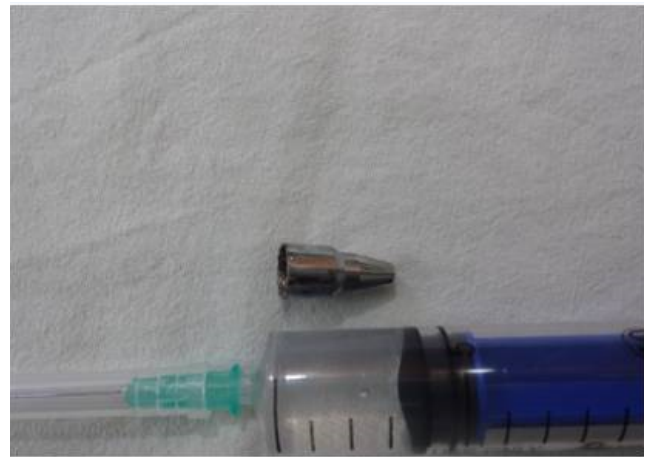


Fig. 7: Pen part




Fig. 8: Plastic part of pen

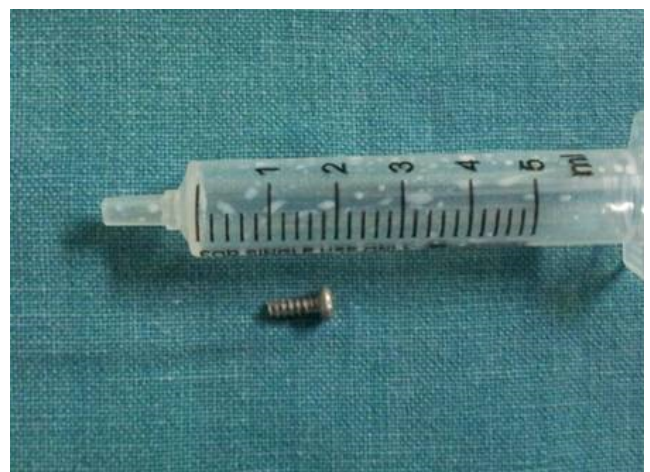

Fig. 9: Screw

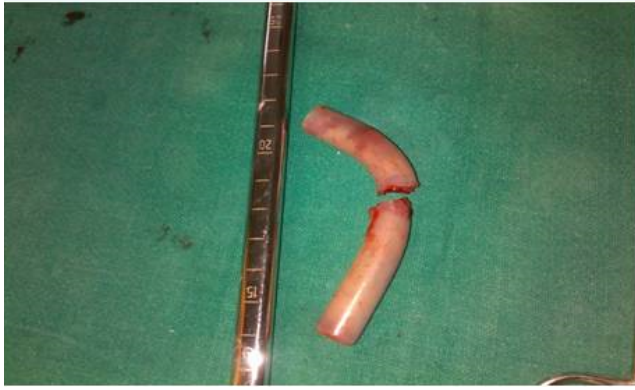

Fig. 10: Broken PVC Tracheostomy tube

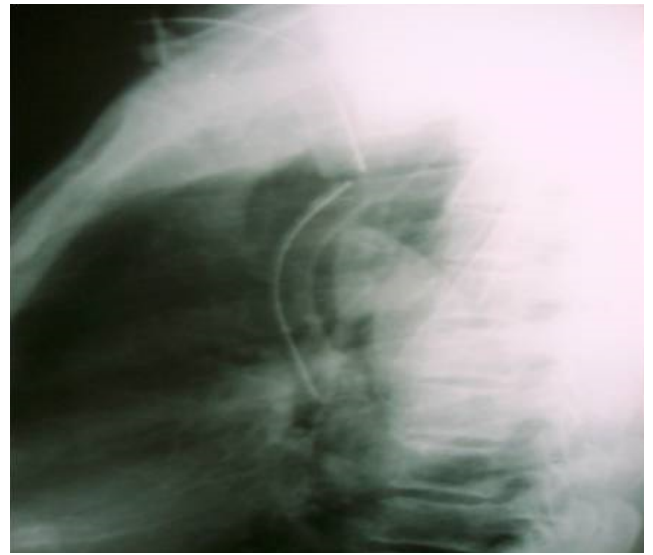


Fig. 12: Xray lateral view of chest showing broken tracheostomy tube

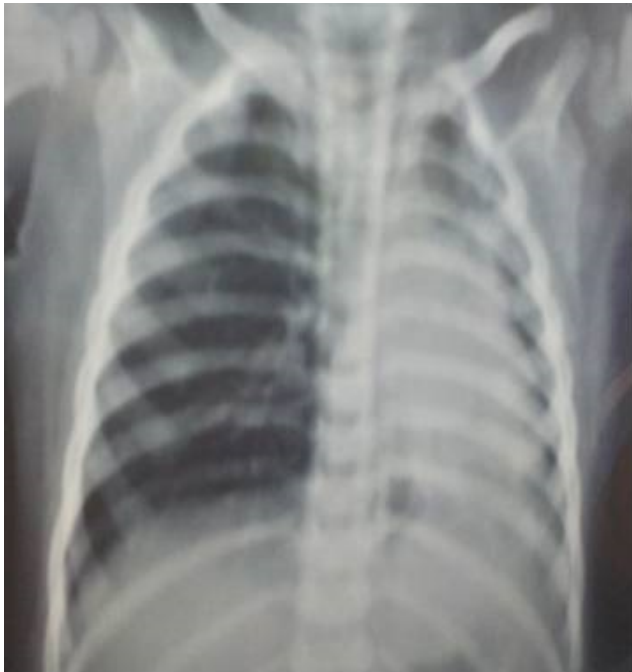

Fig. 11: Lung collapse

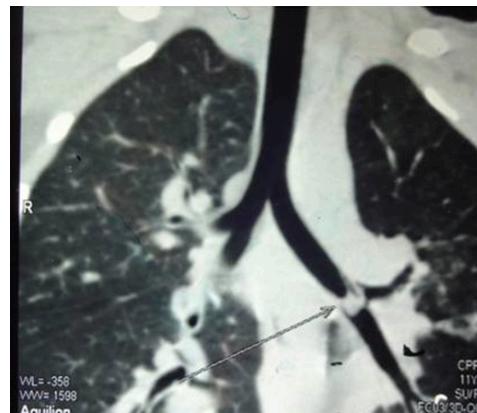


Fig. 13: Foreign body in left bronchus

cases had history of accidental aspiration. Most of children below 4 years are vulnerable and usually do not give a history of aspiration. Vegetative foreign bodies predominate among infants and toddlers, whereas in older children metallic foreign bodies, plastics are more common¹⁶. Most objects aspirated by children are radiolucent, whereas only 18% to 20% of aspirated foreign bodies are radiopaque. Plastic pieces account for 5% to 15% of FBA and tend to remain in place longer because they are inert and radiolucent^{13,15,16}.

A suspicion of foreign body aspiration is therein those patients who have chronic breathing symptoms. Computed tomography of the chest helps in localisation of radiolucent foreign bodies, location and size of the foreign body, lung pathology, and granulation. Rigid bronchoscopy is the

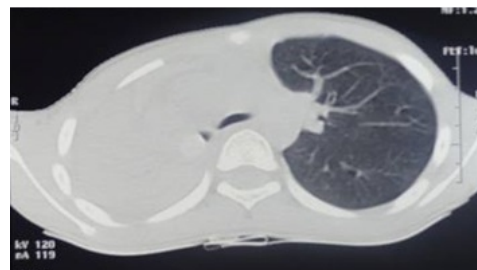


Fig. 14: Collapse of right lung

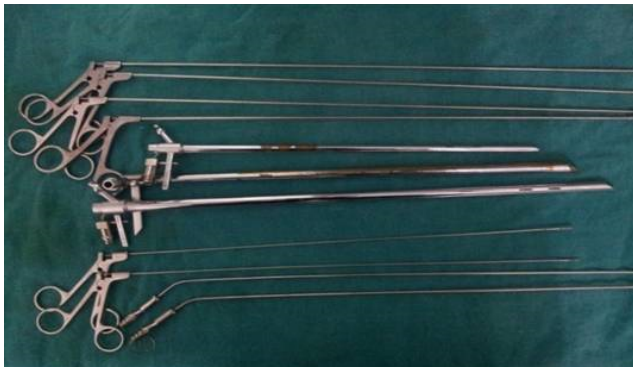

Fig. 15: Bronchoscopy set

gold standard for the safe removal of a foreign body in bronchus^{13,17,18}.

Bronchoscope is again re-inserted to look for any remnants of foreign body and suctioning the trachea-bronchial secretions. The bronchoscope is connected to anaesthetic gas supply in one arm and the other is connected to light source and fibre-optic cable. This enables the anaesthetist and surgeons not to hurry and allow smooth passage of bronchoscope. There are three methods of anaesthesia for bronchoscopy^{9,19}.

1. Anaesthesia with Spontaneous Respiration: After giving topical anaesthesia to larynx and trachea, halothane without muscle relaxant is used.
2. Anaesthesia with Apnoea and Oxygen Insufflation: For short bronchoscopic procedures complete/relaxation can be maintained by intermittent doses of suxamethonium and insufflating oxygen at the rate of 6-10 Ltr/min, into the trachea through a small nasotracheal catheter placed with its tip close to the carina.
3. Anaesthesia with apnoea using Venturi Type injector for positive pressure ventilation: In this procedure, a small tube is attached to the bronchoscope and oxygen under pressure is injected intermittently. Adequate ventilation can be maintained for almost unlimited time in the apnoeic, relaxed patient by this method producing good condition for bronchoscopy without rise in PCO₂ or fall in oxygen tension.

Bronchoscopy is done under general anaesthesia with induction by pentathol, relaxation and apnoea with scoline, Oxygenation with facemask. This is followed by introduction of bronchoscope and maintenance of oxygen with jet ventilation with repeat dose of scoline if necessary. Once the foreign body is localised, forceps like crocodile, alligator, and serrated, cupped, peanut are used for extracting the foreign body.²⁰ The foreign bodies in subglottis have to be removed at the earliest as it causes respiratory emergency. In two of our cases, broken PVC tracheostomy tubes were removed from the trachea

through the stomal opening. Post-operatively antibiotics, analgesics, oxygenation and steroids were administered to treat subglottic edema.

5. Conclusions

Foreign body aspiration is a challenge for otolaryngologists because of high incidence of mortality. Otolaryngologists should proceed for bronchoscopy once foreign body aspiration is suspected. Sander's technique of jet ventilation is the best method of anaesthesia. Parents should be educated about the risks of particular food types and should minimize the availability of small pieces of articles and toys around toddlers.

6. Acknowledgement

None.

7. Source of Funding

None.

8. Conflict of Interest

None.

References

1. Black RE, Johnson DG, Matlak ME. Bronchoscopic removal of aspirated foreign bodies in children. *J Pediatr Surg*. 1994;29(5):682–4.
2. Laks Y, Barzilay Z. Foreign body aspiration in childhood. *Pediatr Emerg Care*. 1988;4:1026.
3. Geensh, Er. J - aspiration accidents. In: mcintirems, ed. - handbook on accident prevention. Maryland, Harper and Row. 1980;p. 49–52.
4. Cataneo AJM, Reibschid SM, Ruiz RL, Ferrari GF. Foreign Body in the Tracheobronchial Tree. *Clin Pediatr (Phila)*. 1997;36(12):701–6.
5. Rajasekaran S, Krishnamoorthy, Chandran B, Anbalagan S, Kumar PS, Vikramvj. Management of foreign bodies in children-retrospective study series of 50 case. *Otolaryngol Online J*. 2013;3(3).
6. Júnior RRT, Barbas SV, Fernandes JM, Mendes MJ, Fiks IN, Ribeiro CS, et al. Foreign-body aspiration in adults. *Rev Hosp Clin Fac Med S Paulo*. 1991;46:193–5.
7. Svedström E, Puhakka H, Kero P. How accurate is chest radiography in the diagnosis of tracheobronchial foreign bodies in children? *Pediatr Radiol*. 1989;19(8):520–2.
8. Zerella JT, Dimler M, McGill LC, Pippus KJ. Foreign body aspiration in children: Value of radiography and complications of bronchoscopy. *J Pediatr Surg*. 1998;33(11):1651–4.
9. Srpnnath J, Mahendrakar V. Management of trachea bronchial foreign bodies-retrospective analysis. *Indian J Otolaryngol Head Neck Surg*. 2002;54(2):127–31.
10. Naragund AI, Mudhol RS, Harugop AS. Tracheo-bronchial foreign body aspiration in children: a one year descriptive study. *Indian J Otolaryngol Head Neck Surg*. 2014;66:180–5.
11. Darrow DH, Holinger LD. Foreign bodies of the larynx, trachea and bronchi. In: CD B, SE S, CM A, EM A, ML C, JE D, et al., editors. Paediatric otolaryngology. WB Saunders Company; 2002. p. 1543–57.
12. Tan HKK, Brown K, McGill T, Kenna MA, Lund DP, Healy GB, et al. Airway foreign bodies (FB): a 10-year review. *Int J Pediatr Otorhinolaryngol*. 2000;56(2):91–9.
13. Digoy GP. Diagnosis and Management of Upper Aerodigestive Tract Foreign Bodies. *Otolaryngol Clin North Am*. 2008;41(3):485–96.

14. Kaur K, Sonkhya N, Bapna AS. Foreign bodies in the tracheobronchial tree: a prospective study of 50 cases. *Indian J Otolaryngol Head Neck Surg.* 2002;54(2):30–4.
15. Rothmann BF, Boeckman CR. Foreign Bodies in the Larynx and Tracheobronchial Tree in Children. *Ann Otol.* 1980;89:434–6.
16. Karakoç F, Karadağ B, Akbenlioğlu C, Ersu R, Yıldızeli B, Yüksel M, et al.. Foreign body aspiration: What is the outcome? Wiley; 2002. Available from: <https://dx.doi.org/10.1002/ppul.10094>. doi:10.1002/ppul.10094.
17. Srivastava G. Airway foreign bodies in children. *Clin Pediatr Emerg Med.* 2010;11(2):67–72.
18. Hui H, Na L, Zhijun CJ, Fugao ZG, Yan S, Niankai ZK, et al. Therapeutic experience from 1428 patients with pediatric tracheobronchial foreign body. *J Pediatr Surg.* 2008;43(4):718–21.
19. Dail DH. Bronchial and transbronchial diseases. New York: Springer-Verlag; 1994. p. 79–85.
20. Martinot A. Indications for flexible versus rigid bronchoscopy in children with suspected foreign-body aspiration. *Am J Respir Crit Care Med.* 1997;155:1676–9.

Author biography

Chinmaya Sundar Ray Associate Professor

Krishna Arpita Sahoo Assistant Professor

Cite this article: Ray CS, Sahoo KA. **Management of tracheo-bronchial foreign bodies at a tertiary care hospital in Eastern part of India.** *IP Indian J Immunol Respir Med* 2020;5(2):119-126.