



Short Communication

When doom is vincible but imperceptible

Debabrata Chakraborty^{1,*}, Sandip Pal²¹Dept. of Neurology, Apollo Gleneagles Hospitals, Kolkata, West Bengal, India²Dept. of Neurology, Medical College Kolkata, Kolkata, West Bengal, India

ARTICLE INFO

Article history:

Received 30-01-2021

Accepted 15-02-2021

Available online 12-03-2021

Keywords:

Kunjala Kriya

Subdural hemorrhage

Burr-Hole Surgery

ABSTRACT

An eighty-year-old gentleman without any comorbidity or significant medical illness had presented with headache of recent onset. A detail clinical evaluation and imaging (MRI of brain) ruled out secondary cause of headache. A month later, he presented to emergency with altered sensorium and quadriparesis. Repeat brain imaging revealed bilateral subdural hemorrhage requiring emergent surgery. He was back to normalcy within few days postoperatively. A confession was obtained about his daily habit of induced vomiting after drinking large amount of water (kunjala kriya).

The repeated habit of induced vomiting might have been responsible for the slowly evolving subdural hemorrhage. Interestingly, though he had significant clinical symptoms at the initial presentation, he had normal initial MRI of brain (the more sensitive imaging modality). Our case highlights the interesting neurophysiology of subdural hemorrhage and the importance of close monitoring of elderly patients of recent onset headache.

© This is an open access article distributed under the terms of the Creative Commons Attribution License (<https://creativecommons.org/licenses/by/4.0/>) which permits unrestricted use, distribution, and reproduction in any medium, provided the original author and source are credited.

Sir,

An eighty-year-old gentleman without any known comorbidities, complained of new onset dull aching, continuous, moderate grade holo-cranial headache. Within few days of the onset of headache, he attended OPD with one episode of early morning postural dizziness and syncope. His clinical examination was within normal limits. The blood parameters (including inflammatory markers), detail cardiac and neurological evaluation were unremarkable (MRI with MRA of brain and cervical spine were non-contributory). Although, there was no history of recent systemic illness or injury, he confessed about habit of induced vomiting after drinking four liters of water every morning (Kunjala Kriya) for years.

He had no further dizziness or syncope once we stopped his habit of induced vomiting. However, continued to have mild heaviness of head even with symptomatic treatment and we planned for a close watch and regular follow up.

* Corresponding author.

E-mail address: drdchakraborty1980@gmail.com (D. Chakraborty).

Three weeks later, he attended ER with acute onset retention of urine and altered sensorium. He was mildly drowsy with quadriparesis, had stable vitals and preserved brain-stem reflexes. His blood parameters including coagulation parameters were normal. An urgent MRI of brain revealed bilateral acute on chronic subdural hemorrhage (SDH), right more than left with significant mass effect and midline shift [Figure 1].

An emergent burr-hole drainage of SDH was performed and he was back to normal within three days. There was no complain of headache, postural dizziness, or syncope henceforth. The new onset of the symptoms in this elderly gentleman and complete resolution post-surgery, proved that it was due to the gradually developed bilateral SDH.

It is known that CT scan of head may not detect a subdural effusion that precedes chronic SDH immediately after injury but becomes apparent one-seven days later.¹ Still, we had no evidence of effusion or bleed in a more sensitive imaging modality (MRI of brain) done even after ten days of symptom onset.

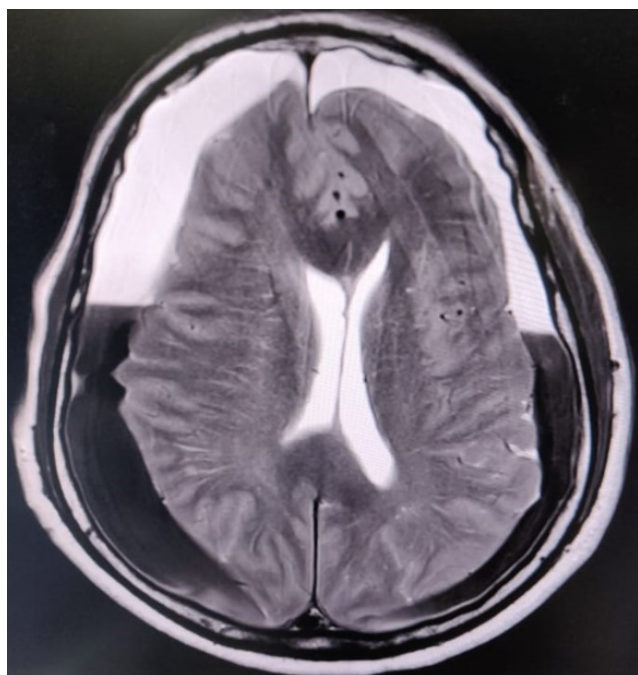


Fig. 1: Repeat MRI of brain (initial MRI was normal) after a month of symptom onset revealed bilateral acute on chronic subdural hematoma with significant mass effect and midline shift.

Though a forgotten trauma is a quite common cause of SDH in elderly, the etiology in our case is most likely the habit of induced vomiting. A forceful exhalation against closed glottis increases intrathoracic pressure thereby decreasing central venous outflow.² The sudden and sustained pressure is transmitted through fragile bridging veins in these susceptible individuals resulting in subdural hemorrhage.² The physiology of chronic subdural

hematoma is complex³ and in early stage even MRI of brain may miss the evidence of blood and patient may land up in a life-threatening situation.

Acknowledgement

We acknowledge the faith patient and his family kept on us during difficult times.

Conflict of Interest

None.

References

1. Stiell IG, Wells GA, Vandemheen K, Clement C, Lesiuk H, Laupacis A, et al. The Canadian CT Head Rule for patients with minor head injury. *Lancet*. 2001;357(9266):1391-6. doi:10.1016/s0140-6736(00)04561-x.
2. Haykowsky M, Eves N, DE RW, Findlay M. Resistance Exercise, the Valsalva Maneuver, and Cerebrovascular Transmural Pressure. *Med Sci Sports Exerc*. 2003;35(1):65-8. doi:10.1097/00005768-200301000-00011.
3. Edlmann E, Giorgi-Coll S, Whitfield PC, Carpenter KLH, Hutchinson PJ. Pathophysiology of chronic subdural haematoma: inflammation, angiogenesis and implications for pharmacotherapy. *J Neuroinflammation*. 2017;14(1):108. doi:10.1186/s12974-017-0881-y.

Author biography

Debabrata Chakraborty, Consultant

Sandip Pal, Professor

Cite this article: Chakraborty D, Pal S. When doom is vincible but imperceptible. *IP Indian J Neurosci* 2021;7(1):97-98.