



Case Report

Anti-NMDAR encephalitis presenting with early and prominent orolingual dyskinesia and its association with ovarian serous cystadenoma- case report

Sudhakar Pandey^{1,*}, Nomal Chandra Borah¹, Shabnam A. Ahmed¹, Manjari Dwivedi²

¹Dept. of Neurology, GNRC Hospitals, Dispur, Guwahati, Assam, India

²Dept. of Endocrinology, Gauhati Medical College, Guwahati, Assam, India



ARTICLE INFO

Article history:

Received 28-07-2020

Accepted 26-09-2020

Available online 30-11-2020

Keywords:

AntiNMDAR encephalitis

Intravenous immunoglobulin (IVIG)

Serous cystadenoma of ovary

ABSTRACT

Autoimmune encephalitis is relatively a new entity. Anti-N-methyl-D-aspartate receptor (anti-NMDAR) encephalitis is one of the most common and well studied autoimmune encephalitis. We report a case of anti-NMDAR encephalitis presenting initially with orolingual dyskinesia and its association with large ovarian serous cystadenoma. She was given complete course of intravenous immunoglobulin (2GM/KG) as well as removal of the tumor. Histopathology of the cystic lesion revealed serous cystadenoma of the ovary. The patient is now on regular follow up and is doing well. To best of our knowledge, this is the first case in literature showing association of anti-NMDAR encephalitis with serous cystadenoma of ovary and orolingual dyskinesia as initial clinical presentation.

© This is an open access article distributed under the terms of the Creative Commons Attribution License (<https://creativecommons.org/licenses/by/4.0/>) which permits unrestricted use, distribution, and reproduction in any medium, provided the original author and source are credited.

1. Introduction

Autoimmune encephalitis is relatively a new entity. Anti-N-methyl-D-aspartate receptor (anti-NMDAR) encephalitis is one of the most common and well-studied autoimmune encephalitis.^{1,2} First case of anti-NMDAR encephalitis was published in 2007 by Dr. Joseph Dalmau of University of Pennsylvania.³ It was reported in a young female with ovarian teratoma. She had shown good response to first line immuno-therapy (intravenous methylprednisolone and intravenous immunoglobulin (IVIG) along with tumor removal. Since then variable number of cases have been published in literature with different clinical presentation and variable outcome profile.^{1,2} Orolingual dyskinesia is often seen in these patients during the course of illness, but initial presentation with orolingual dyskinesia is a rare phenomenon and has not been reported in literature till now. Further evaluation of this case showed it's association with serous cystadenoma of ovary. To best of our knowledge, this has also not been reported in literature.³ Hence, we wish

to report this case of anti-NMDAR encephalitis with initial manifestation of orolingual dyskinesia followed by other manifestations of the disease and its association with serous cystadenoma of ovary. To best of our knowledge, this is the first case report in literature and has not been published earlier.

2. Case Report

A 18 years old female presented to us with the subacute onset of abnormal involuntary orolingual movements associated with forgetfulness. It was later followed by low grade fever and neuropsychiatric manifestations in the form of disinhibition and agitation. It was also associated with abnormal cry and episodic fearfulness and multiple episodes of seizure. On examination, her blood pressure was 130/80 mmHg, pulse rate was 82/ minute, spo2 was 96 % at room air and she was febrile. Her Glasgow Coma Scale (GCS) was E3V4M5 (GCS score -12/15), pupils were reacting to light and bilateral symmetrical, neck rigidity and kernig's sign was absent and no obvious cranial nerve deficit was detected at the time of examination. She was moving all

* Corresponding author.

E-mail address: drsudhakarpandey2781@gmail.com (S. Pandey).

4 limbs and there was no focal neurological deficit. She had significant autonomic instability and had fluctuations in her blood pressure with variable pulse rate. Elective endotracheal intubation was done to prevent aspiration pneumonitis due to excessive oral and nasal secretions during the course of hospital stay.

Considering the possibility of autoimmune encephalitis on the basis of above symptoms and signs, she was investigated with routine blood investigations, cerebrospinal fluid (CSF) study, magnetic resonance imaging (MRI) brain with gadolinium contrast (GAD) and CSF NMDAR antibody. Routine blood investigations were within normal limit except deranged liver enzymes (aspartate aminotransferase (AST) – 88 IU/ L, alanine aminotransferase (ALT) -102 IU/L). MRI brain showed medial temporal lobe signal changes without any contrast enhancement (Figures 1 and 2) and CSF study showed positive anti-NMDAR IgG antibody.

Patient was started with intravenous methylprednisolone 500 milligram /day for 5 days followed by IVIG (2gm/kg) in next 5 days duration. Patient showed significant improvement in her clinical signs and symptoms. Later patient was kept on weekly IVIG (0.4 gm /kg) therapy along with other supportive treatment. Malignancy screening showed large right ovarian cyst with nonvisualization of right ovary (Figure 3). There was no evidence of ovarian teratoma in imaging, the most common associated tumor with anti-NMDAR encephalitis. Patient was later operated for ovarian cystic lesion and the histopathology revealed following features; cyst wall lined with cuboidal to tall columnar epithelial cells with cilia, and stroma with spindle cells. These features were suggestive of serous cystadenoma of ovary without any evidence of teratoma (Figures 4 and 5). The patient is on regular follow up and is currently asymptomatic.

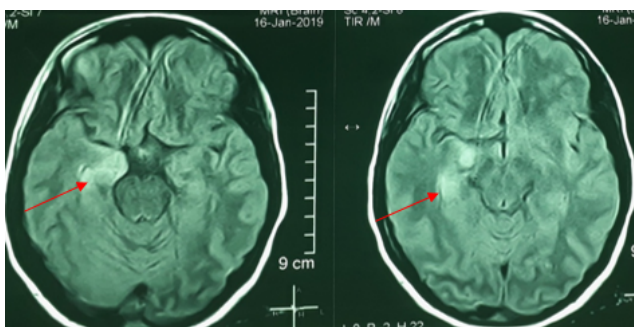


Fig. 1: Axial section of MRI Brain (fluid-attenuated inversion recovery (FLAIR)).

3. Discussion

Anti-NMDAR encephalitis is one of the most common autoimmune encephalitis.^{1,2} It commonly affects young

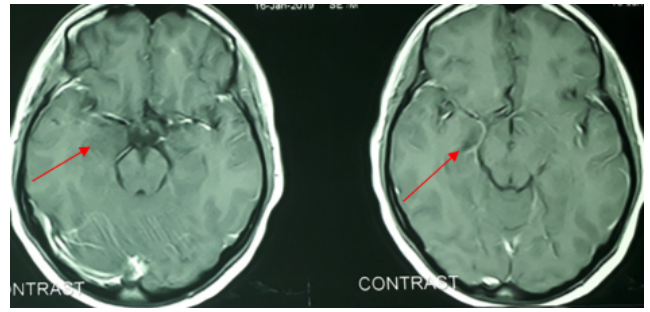


Fig. 2: Gadolinium contrast (GAD) sequences) showing bilateral (right>left) medial temporal lobe signal changes without post contrast enhancement (red closed arrow).

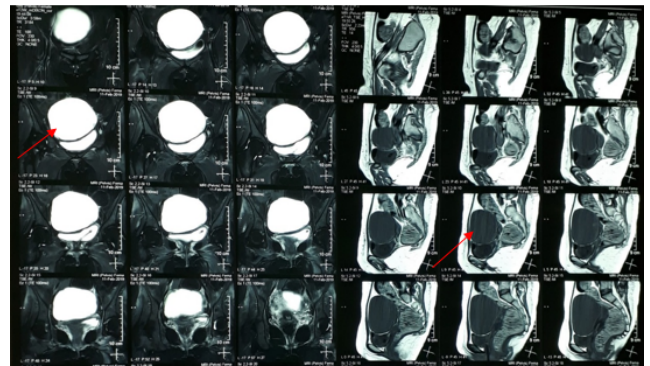


Fig. 3: Coronal and sagittal section of MRI Pelvis (t1w and t2w images respectively) showing large monolocular cyst with clear fluid without any evidence of fat or calcification in side the cyst (red closed arrow).

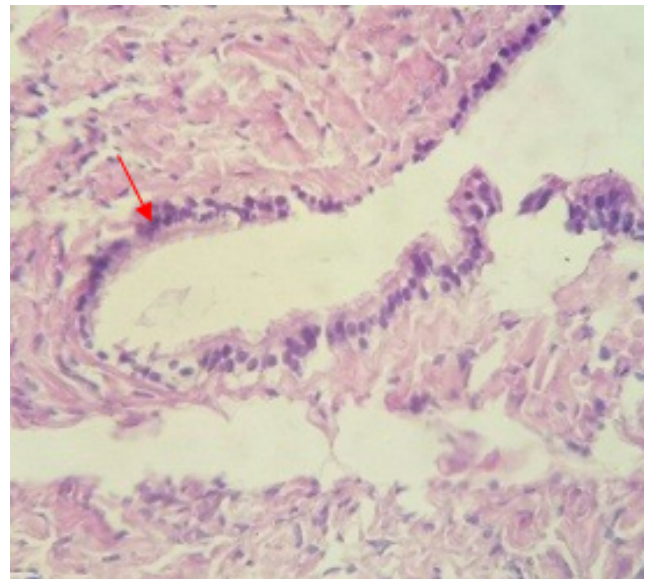


Fig. 4: Histopathology images showing cyst wall lined by a single layer of cuboidal to tall columnar epithelial cells with cilia with stromal spindle cells, suggestive of serous cystadenoma of ovary (red closed arrow).

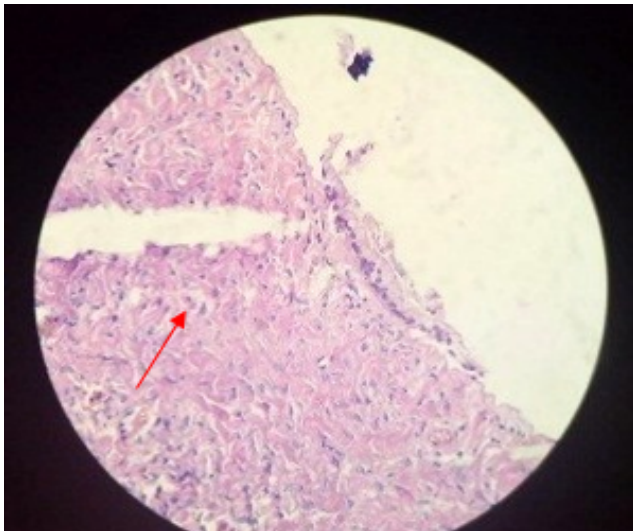


Fig. 5:

age females although it can affect any age group.^{2,4} Most common presentation seen in these type of patients is, subacute onset of behavioral changes and memory disturbances followed by language disturbances, orolingual dyskinesia, seizures, autonomic instability and central hypoventilation syndrome in a variable combinations.⁴ The memory disturbance is mainly in the form of recent memory loss and language disturbance is either in the form of complete muteness or patient talks irrelevantly.² The seizures can be either focal or generalized, but generalized seizure is more frequent than focal one and sometimes they can present with status epilepticus.⁵ Autonomic instability and central hypoventilation is most common cause for ventilatory assistance in these patients.^{1,4}

3.1. Diagnostic criteria for anti-NMDAR encephalitis³

Probable anti-NMDAR encephalitis:

Diagnosis can be made when all three of the following criteria have been met:

1. Rapid onset (less than 3 months) of at least four of the six following major groups of symptoms:
 - Abnormal (psychiatric) behaviour or cognitive dysfunction
 - Speech dysfunction (pressured speech, verbal reduction, mutism)
 - Seizures
 - Movement disorder, dyskinesias, or rigidity/abnormal postures
 - Decreased level of consciousness
 - Autonomic dysfunction or central hypoventilation
2. At least one of the following laboratory study results:
 - Abnormal electroencephalogram (EEG) (focal or diffuse slow or disorganised activity, epileptic activity,

- or extreme delta brush)
- CSF with pleocytosis or oligoclonal bands

3. Reasonable exclusion of other disorders

Diagnosis can also be made in the presence of three of the above groups of symptoms accompanied by a systemic teratoma

3.2. Definite anti-NMDAR encephalitis

Diagnosis can be made in the presence of one or more of the six major groups of symptoms and IgG anti-GluN1 antibodies, after reasonable exclusion of other disorders.

Our patient fulfilled the diagnostic criteria for definite anti-NMDAR encephalitis.

Diagnosis of anti-NMDAR encephalitis is often delayed because of nonspecific symptoms and psychiatric manifestations.^{6,7} Orolingual dyskinesia as the initial presentation, is very rare phenomenon.² In our patient orolingual dyskinesia was the initial presentation along with other neuropsychiatric manifestations. She was initially treated by psychiatrist and the abnormal movements and psychiatric manifestations were considered primarily of psychiatric in origin.⁵ But due to progressive deterioration in her clinical condition, patient was brought to our hospital. This disease is most commonly associated with ovarian teratoma but in our patient instead a right sided huge serous ovarian cyst of size approximately 10×12×14 cm was seen.³ The gynaecology consultation was taken and operative intervention was done later on. Although the exact nature of cyst could only be ascertained after histopathological examination, the radiological characteristics were suggestive of serous mono-locular cyst without any evidence of calcification or fat component. Later the histopathology of the cyst revealed it to be the serous cystadenoma of ovary.

The serous cystadenoma of ovary is a type of benign ovarian epithelial tumor composed of unilocular/multilocular cysts with the clear watery fluid. They are mostly asymptomatic in nature but at times they can cause mass effect because of the size of cyst. The histopathology of the cyst shows, cuboidal to tall columnar epithelial cells with cilia lining the cyst wall along with spindle cells in the stroma.⁸ Whereas, the teratoma of ovary is a type of germ cell tumor arising from ectopic pluripotent stem cells. They have components from all three embryological layers: endoderm, ectoderm and mesoderm. They can be solid or cystic with keratin/hair or teeth in side the tumor.⁸

The teratoma of ovary is well defined entity associated with anti- NMDAR encephalitis as it triggers the formation of anti-NMDAR antibody by the immune system because of various types of tissue in it. Whereas, the serous cystadenoma of ovary is benign epithelial tumor with single tissue component in it and it is uncertain whether this tumor could cause anti- NMDAR encephalitis or

it was a coincidental finding and the patient had improvement because of immunotherapy.⁹ However the patient's persistent response after removal of the tumor and no relapse since then points towards the causal association rather than a chance finding. However, Further studies are needed to prove it.

The association of teratoma or other tumors with anti-NMDAR encephalitis makes the chances of relapse less likely if the patient is treated with primary immunotherapy (i.v. methylprednisolone/ IVIG/ plasmapheresis) with removal of the tumor, compared to those who do not have associated tumor.^{10,11} Orolingual dyskinesia and other movement abnormalities can be seen during the course of illness usually in the second stage of the disease but prominent orolingual dyskinesia as the initial presenting feature in the first stage of the disease, as in our patient has not been reported in literature.

The anti-NMDAR encephalitis is occasionally associated with other autoimmune disorders like Hashimoto's thyroiditis (HT), systemic sclerosis(SS) and systemic lupus erythematosus (SLE).¹² The presence of autoimmune diseases does not affect the clinical course of autoimmune encephalitis. This has diagnostic implications as well, as these patients can easily be mistaken for psychiatric illness and the diagnosis as well as treatment might be delayed.² The response to immunotherapy is good but patients are prone for relapses, hence regular follow up is needed.¹⁰ Thorough search for associated tumours should be done in each and every case with autoimmune encephalitis as it gives a better chance for cure if removal of the tumor is done on time.

4. Conclusion

Anti-NMDAR encephalitis is a rare entity but its association with ovarian teratoma is well established. Proper evaluation and early treatment is key to good results. Diagnosis is usually delayed due to varied presentation and most of them are initially treated by psychiatrist due to prominent neuropsychiatric manifestations. Association of anti-NMDAR encephalitis with serous cystadenoma of ovary as well as orolingual dyskinesia as initial clinical presentation is not reported in literature till now, which is seen in our patient. Detailed evaluation of associated tumors in such type of patient is very important as the removal of the tumor along with immunotherapy leads to good outcome in most of the patients.

5. Source of Funding

No financial support was received for the work within this manuscript.

6. Conflict of Interest

The authors declare they have no conflict of interest.

References

1. Barry H, Byrne S, Barrett E, Murphy KC, Cotter DR. Anti-N-methyl-D-aspartate receptor encephalitis: review of clinical presentation, diagnosis and treatment. *B J Psych Bull.* 2015;39(1):19–23. doi:10.1192/pb.bp.113.045518.
2. Ferioli S, Dalmau J, Kobet CA, Zhai QJ, Broderick JP, Espay AJ, et al. Anti-N-methyl-D-aspartate receptor encephalitis: characteristic behavioral and movement disorder. *Arch Neurol.* 2010;67:250–1.
3. Dalmau J, Tüzün E, Wu HY, Masjuan J, Rossi JE, Voloschin A, et al. Paraneoplastic anti-N-methyl-D-aspartate receptor encephalitis associated with ovarian teratoma. *Ann Neurol.* 2007;61(1):25–36. doi:10.1002/ana.21050.
4. Graus F, Titulaer MJ, Balu R, Benseler S, Bien CG, Cellucci T, et al. A clinical approach to diagnosis of autoimmune encephalitis. *Lancet Neurol.* 2016;15(4):391–404. doi:10.1016/s1474-4422(15)00401-9.
5. Moscato EH, Jain A, Peng X, Hughes EG, Dalmau J, Balice-Gordon RJ. Mechanisms underlying autoimmune synaptic encephalitis leading to disorders of memory, behavior and cognition: insights from molecular, cellular and synaptic studies. *European Journal of Neuroscience.* 2010;32(2):298–309. Available from: <https://dx.doi.org/10.1111/j.1460-9568.2010.07349.x>. doi:10.1111/j.1460-9568.2010.07349.x.
6. Lee SK, Lee ST. The laboratory diagnosis of autoimmune encephalitis. *J Epilepsy Res.* 2016;6(2):45–50.
7. Dalmau J, Lancaster E, Martinez-Hernandez E, Rosenfeld MR, Balice-Gordon R. Clinical experience and laboratory investigations in patients with anti-NMDAR encephalitis. *Lancet Neurol.* 2011;10(1):63–74. doi:10.1016/s1474-4422(10)70253-2.
8. Scully RE. Ovarian tumors. A review. *AM J Pathol.* 1977;87(3):686–720.
9. Cho EH, Byun JM, Park HY, Kang MR, Jung YJ, Jeong CH, et al. Anti-NMDAR encephalitis associated with ovarian mucinous cystadenoma. *Taiwan J Obstet Gynecol.* 2019;58(4):557–9.
10. Titulaer MJ, McCracken L, Gabilondo I, Armangue T, Glaser C, Lizuka T, et al. Treatment and prognostic factors for long-term outcome in patients with anti-N-Methyl- D-Aspartate (NMDA) receptor encephalitis: a cohort study. *Lancet Neurol.* 2013;12:157–65.
11. Ishiura H, Matsuda S, Higashihara M, Hasegawa M, Hida A, Hanajima R, et al. Response of anti-NMDA receptor encephalitis without tumor to immunotherapy including rituximab. *Neurol.* 2008;71(23):1921–6. doi:10.1212/01.wnl.0000336648.43562.59.

Author biography

Sudhakar Pandey, Consultant Neurologist

Nomal Chandra Borah, Senior Neurologist

Shabnam A. Ahmed, Consultant Pathologist

Manjari Dwivedi, Senior Resident

Cite this article: Pandey S, Borah NC, Ahmed SA, Dwivedi M. Anti-NMDAR encephalitis presenting with early and prominent orolingual dyskinesia and its association with ovarian serous cystadenoma- case report. *IP Indian J Neurosci* 2020;6(4):333–336.