



Case Report

The common peroneal nerve schwannoma: A case rare case report with brief review of literature

Piyush Kumar Panchariya¹, Abhijeet Bele^{1,*}, H Singh¹, D Singh¹

¹Dept. of Neurosurgery, G B Pant Institute of Post Graduate Medical Education and Research, Delhi, India



ARTICLE INFO

Article history:

Received 06-11-2020

Accepted 12-11-2020

Available online 30-11-2020

Keywords:

Common peroneal nerve

Schwannoma

Neurilemmoma

ABSTRACT

Swelling in popliteal region is a common presentation with usual differential diagnosis of bakers cyst, ganglionic cysts. Schwannoma of common peroneal nerve although a clinically rare entity may also have similar presentation. The treatment of choice for such schwannoma is surgical excision with preservation of nerve integrity. Without knowledge of this consideration and disrespecting nerve planes during surgery may have devastating complications. We here present a similar rare case report of common peroneal nerve schwannoma with brief review of literature; the case was managed by complete surgical excision with no neurological deficit in post operated phase.

© This is an open access article distributed under the terms of the Creative Commons Attribution License (<https://creativecommons.org/licenses/by/4.0/>) which permits unrestricted use, distribution, and reproduction in any medium, provided the original author and source are credited.

1. Introduction

Neurilemmomas (neurinoma-schwannoma) are benign, solitary, well-demarcated usually as a capsule, slowly growing tumours. They arise from the proliferation of active peripheral Schwann cells.^{1,2} Although they represent the commonest benign peripheral nerve sheath tumours, the occurrence on the lower limbs account for 1% of all cases.³ Frequently they are seen between the ages of 20 and 50 years.

Cases of common peroneal nerve schwannomas are very rare in the literature (Table 1).^{2,4} They usually have a clinically silent course. Rarely, they may present as knee pain or paraesthesia due to mechanical compression of the nerve. A thorough examination and prompt investigation helped us make a timely diagnosis and initiate appropriate treatment. Schwannomas should be included in the differential diagnosis of lumps in the vicinity of nerves. These tumours may affect the nerve conduction of the nerve as indicated by the nerve conduction study in our case. This case presentation highlights the importance of screening for the possibility of a peroneal schwannoma

in patients presenting with popliteal swelling despite nonspecific findings of physical examination.

2. Case Report

A 12 years old male student patient presented to OPD with a complaint of swelling in right popliteal fossa since 5 years. It was initially of size of pea nut which gradually increased over period to present size about 2x2 cm. It was insidious in onset, gradually progressive, not associated with any pain or restriction of movement or any neurological deficit. There was no h/o trauma, pin prick, fever, reduction of swelling or any other.

Examination revealed a firm mass in the proximal lateral aspect of his right leg, measuring 3cm×3cm, located in the subcutaneous plane with little mobility in the vertical plane and good mobility in the horizontal plane (perpendicular to nerve direction). It was non tender, non-reducible, non-fluctuant, non transilluminating. Swelling disappeared on flexing the knee. No other masses were found. Motor function of the deep and superficial peroneal nerves was normal. By lightly tapping the leg lump, a positive Tinel's sign was elicited

* Corresponding author.

E-mail address: abhijeetsbele@gmail.com (A. Bele).

Table 1: Some related case reports.

S. No.	Case reports	Symptoms	Excision
1	Shariq et al. (2012)	Knee lump	Required intralesional excision
2	Houshian et al. (1999)	Knee Pain	Successful
3	Mahitchi et al. (2001)	Knee Pain and numbness	Successful
4	Cato et al. (1995) ⁶	Knee Web space pain	Successful
5	Biröl Aktaş et al.(2017)	Knee lump. pain numbness	Successful

Routine laboratory diagnostic tests and x rays showed no specific findings. Therefore, an MRI scan was obtained (Image A). Nerve conduction study was done which was suggestive of decreased motor amplitude of the right common peroneal nerve at ankle and fibular head as compared to left common peroneal nerve.

The MRI revealed an ovoid solid mass at posterolateral aspect of right knee about 2.9 cm x 1.79 cm x 2.96 cm in size overlying the head of gastrocnemius and anterolateral just abutting the bicep femoris. It was slightly hyper intense than muscle on T1 weighted images and was hyper intense on T2 weighted images and at the perimeter was involving the common peroneal nerve and demonstrating nerve continuity.

During surgery, a longitudinal incision was made and the lesion was exposed by longitudinal cutaneous and subcutaneous incisions. The peroneal nerve was located and dissected secured at either ends. After longitudinal dissection of the perineurium, the lesion was excised with its roots in the common peroneal nerve. The perineural sheath was repaired with proline 8-0 suture.

The excised material was sent for histopathologic examination which showed a capsule formed in the epineurium with spindle cells arranged in short whorls, with hyper and hypo-cellular areas and numerous verocay bodies.

The patient's complaints completely disappeared in the post-operative period without development of any neurological deficit.

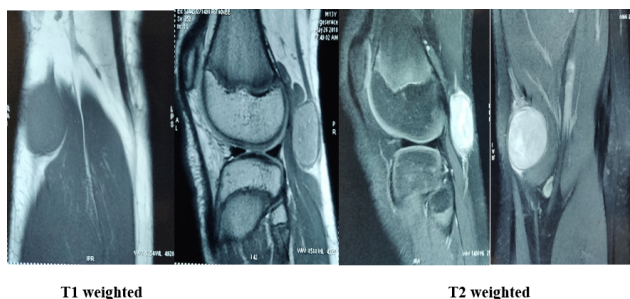


Fig. 1: Ovoid smooth surfaced solid mass at posterolateral aspect of rt. knee, 2.9cm x 1.79cm x 2.96 cm in size, overlying lateral head of gastrocnemius and antero-laterally abutting bicep femoris. T1 images shows slightly hyperintense mass as compare to muscle intensity and hyperintense mass on T2 weighted images with common peroneal nerve at either end in continuity.

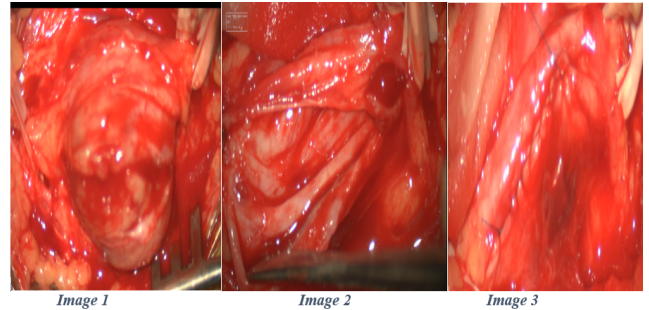


Fig. 2: Intraoperative images: 1: Peroneal nerve schwannoma with nerve in continuity; 2: Perineural Sheath; 3: Sutured perineurium.

3. Discussion

A Schwannoma, also known as neuroma, neurilemmoma or Schwann cell tumour, arises from the neurilemmal cells which forms myelin over peripheral nerves. Schwannomas are slow growing masses with rare malignant transformation.³ Schwannomas has more predilection for females in usual age group of fifth decade. Schwannomas are located in varied location with rare reports of being located in leg and foot.⁵ Schwannomas are usually clinically silent lesions with main presentation as a painless growing mass as was in our case. MRI is the investigation of choice of peripheral nerve schwannomas⁶ which reflects nature of pathology and planes with respect to adjoining anatomical structures. Nerve conduction studies and other ancillary tests⁷ may reflect subtle changes in nerve physiology where no obvious clinical symptoms of nerve compromise are evident as was there in our case with decreased NCV.

Surgical excision remains the treatment of choice with careful enucleation of schwannoma preserving nerve fascicles is the main goal of treatment.⁷ The main challenge is to preserve nerve continuity and its function in post operated period. Our case had no deficits in post operated period and is doing fine after 1 year of follow up.

The schwannomas are grossly solid or solid cystic lesions with presence of Antoni A and Antoni B pattern on microscopy. In Antoni A, there is presence of spindle cell array with collagen matrix and presence of verocay bodies while in Antoni B loose arrangement is present with a mucinous matrix.⁸ The typical

There is usually a good prognosis after complete excision of peroneal nerve schwannomas.

4. Conclusions

Schwannoma of peroneal nerve may present as a painless palpable mass in leg and foot and should be kept in consideration while evaluating such cases specially swelling in popliteal region. Complete excision of lesion with preservation of nerve function and integrity remains the mainstay of treatment with low rates of recurrence.

5. Source of Funding

None.

6. Conflict of Interest

None.

References

1. Akbay A. Periferik sinir tümörleri. *Türk Nöroşirürji Der.* 2005;15:225–6.
2. Houshian S, Freund KG. Gigantic benign schwannoma in the lateral peroneal nerve. *Am J Knee Surg.* 1999;12:41–2.
3. Rafai M, Largab A, Trafah M. Peroneal nerve Schwannoma presenting with a peroneal palsy. *Rev Neurol.* 2006;162(8-9):866–8.
4. Öz TT, Aktaş B, Özkan K, Özturan B, Kilic B, Demiroğlu M, et al. A case of schwannoma of the common peroneal nerve in the knee. *Orthop Rev.* 2017;9(1):6825. doi:10.4081/or.2017.6825.
5. Russell RC, Williams NS, Bulstrode CJ. Bailey and Love's short practice of surgery. London: Arnold; 2004.
6. Shariq O, Radha S, Konan S. Common peroneal nerve schwannoma: an unusual differential for a symptomatic knee lump. *BMJ Case Rep.* 2012;2012(dec03 1):bcr2012007346. doi:10.1136/bcr-2012-007346.
7. Lai CS, Chen IC, Lan HC, Lu CT, H YJ. Management of extremity neurilemmomas: clinical series and literature review. *Ann Plast Surg.* 2013;71(1):S37–42. doi:10.1097/SAP.000000000000042..
8. Rodriguez FJ, Folpe AL, Giannini C, Perry A. Pathology of peripheral nerve sheath tumors: diagnostic overview and update on selected diagnostic problems. *Acta Neuropathol.* 2012;123(3):295–319. doi:10.1007/s00401-012-0954-z.

Author biography

Piyush Kumar Panchariya, Senior Resident

Abhijeet Bele, Senior Resident

H Singh, Professor

D Singh, Director Professor

Cite this article: Panchariya PK, Bele A, Singh H, Singh D. The common peroneal nerve schwannoma: A case rare case report with brief review of literature. *IP Indian J Neurosci* 2020;6(4):330-332.