

Content available at: <https://www.ipinnovative.com/open-access-journals>

IP International Journal of Ocular Oncology and Oculoplasty

Journal homepage: <https://ijooo.org/>

Original Research Article

Lateral tarsal strip (LTS): Surgical technique and outcomes

Syed Mehbub Ul Kadir^{1,*}, Rajendra P Maurya², Md. Saiful Islam³,
Mostafa Zahir Raihani¹, Sharmin Ahmed⁴, Meghna Roy², Golam Haider⁴¹Sheikh Fajilatunnesa Mujib Eye Hospital and Training Institute, Gopalganj, Bangladesh²Regional Institute of Ophthalmology, Institute of Ophthalmology Banaras Hindu University, Varanasi, Uttar Pradesh, India³Rajshahi Medical College Hospital, Rajshahi, Bangladesh⁴Bangladesh Eye Hospital and Institute, Dhaka, Bangladesh

ARTICLE INFO

Article history:

Received 14-03-2021

Accepted 22-03-2021

Available online 28-04-2021

Keywords:

Lateral tarsal strip

Involutional

Entropion

Ectropion

ABSTRACT

Aims: To assess the outcome of lateral tarsal strip (LTS) for the involutional entropion and ectropion.**Materials and Methods:** A quasi study was carried out in a tertiary eye hospital of Dhaka, Bangladesh, between January 2013 and December 2020. This study included all patients who underwent lateral tarsal strip (LTS) procedure for the correction of involutional entropion and ectropion. Group A patients were presented with involutional entropion and group B patients were presented with involutional ectropion. We assessed surgical outcome and postoperative complications.**Results:** Out of 48 lower eyelids marginal malposition of 43 patients were studied in this study and 5 cases were presented bilateral lower lid marginal malposition. Lateral tarsal strip (LTS) procedure was a unique procedure to correct the involutional entropion (24 eyelids 50%), involutional ectropion (24 eyelids 50%), involving the lower eyelid. The male to female ratio was almost 2.6:1. The mean age was 68.49 years with 54 years to 90 years age range. The surgical correction was satisfactory in 95.9%, and 91.7% of lower eyelids involutional entropion, and involutional ectropion respectively.**Conclusions:** Lateral tarsal strip (LTS) is a unique procedure to achieve better cosmetic and functional outcome for the correction involutional eyelid marginal malposition (entropion, and ectropion).© This is an open access article distributed under the terms of the Creative Commons Attribution License (<https://creativecommons.org/licenses/by/4.0/>) which permits unrestricted use, distribution, and reproduction in any medium, provided the original author and source are credited.

1. Introduction

Involutional entropion and involutional ectropion are common eyelid malposition. Entropion presents with Inward rotation of the eyelid towards the globe and ectropion causes an outward rotation of the eyelid margin away from the normal eyelid position. There are various surgical options to correct the entropion and ectropion. Quikert's procedure, wies procedure, Wheelers technique, triangular tarsectomy, wedge excision, wheeler technique, or lateral Bick's shortening and many more techniques are described in literatures for the management of entropion and ectropion.¹⁻³ LTS is a successful procedure for the

management of horizontal laxity and as well as lateral canthal laxity in the cases of involutional entropion and ectropion.² We attempted to analyse the surgical outcome and postoperative complications of lateral tarsal strip (LTS) procedure for the correction of both involutional marginal malposition (entropion and ectropion) of the lower eyelid.

2. Materials and Methods

A quasi study was carried out in a tertiary eye hospital of Dhaka, Bangladesh, between January 2014 and December 2020. This study included all patients who underwent lateral tarsal strip (LTS) procedure for the correction of involutional lower eyelid marginal malposition (entropion and ectropion), and followed up after the LTS surgery up to 1 year during the time of January 2013 to December 2020.

* Corresponding author.

E-mail address: mehbubkadir@gmail.com (S. M. U. Kadir).

Group A patients presented with involuntional entropion and group B patients were included involuntional ectropion. We assessed surgical outcome and postoperative complications. All LTS surgeries were done by a single surgeon. Patients were evaluated clinically, and preoperative general checkup was assessed by an anesthesiologist. Patients with cicatricial entropion, spastic entropion, paralytic ectropion were excluded from this study. We assessed surgical outcome, postoperative complications, and recurrence. Surgical outcome includes restoration of eyelid marginal position nearer to normal eyelid position, and relief of preoperative symptoms. Patients were advised for follow up at 1 month then 3 monthly followed up to one year of surgery. Data were maintained and analyzed statistically using quick calc graph pad software for determination of mean, test of significance and p-value.

2.1. Surgical technique for lateral tarsal strip

Lateral canthotomy incision about 1 cm is usually made at the lateral canthus by Ellman radiofrequency cautery, then blunt dissection is performed by a straight scissor to expose the periosteum of the lateral orbital wall. An inferior canthotomy and cantholysis was created with RF Cautery with proper hemostasis. Measuring the desired amount of LTS strip with pulled the eyelid towards the lateral canthus. Anterior and posterior lamella of the lateral aspect of lower eyelid is gently separated and then anterior lamella is trimmed to make a LTS strip about 5-10 mm depends on lower eyelid laxity followed by scarping of the tarsal conjunctiva of lateral tarsal strip. The expected amount of LTS can be assessed and fixating sutures is placed through the tarsal strip and the periosteum of lateral orbital wall by 5/0 prolene suture which is at least 2 mm superior to medial canthus. The periosteal bite should be confirmed by pulling the sutures and tied the suture; second suture is placed as in the same manner. Finally, the lateral canthus is reconstructed with 6/0 vicryl buried suture into gray line followed by closure of skin and orbicularis oculi muscle with 6/0 vicryl sutures accordingly. The procedure is demonstrated in Figures 1 and 2.

3. Results

We assessed the outcome of LTS procedure for 48 lower eyelids marginal malposition of 43 patients. 38(88.4%) cases were unilateral and 5(11.6%) cases were bilateral eyelid marginal malposition. Among the bilateral cases, 3(60%) were involuntional entropion and 2(40%) were involuntional ectropion. Group A included 24(50%) eyelids with involuntional entropion of 21 patients, and group B included 24(50%) eyelids with involuntional ectropion of 22 patients [Table 1]. This evaluated 31(72%) male and 12 female (28%). The mean age \pm SD was 68.49 ± 9.97 years with the age range from a minimum of 54 years to a

maximum of 90 years. Forty-five (93.7%) eyelids obtained satisfactory outcome after correction of involuntional lower eyelid entropion and ectropion by the LTS procedure alone within one year followed up period. Three eyelids (6.3%) showed recurrences after 6 months of the LTS procedure. Among the recurrence cases, two (8.3%) were involuntional ectropion (Group B) and another one (4.2%) was involuntional entropion (Group A).

The success rate was 95.8%, and 91.7% of lower eyelids involuntional entropion, and involuntional ectropion respectively. The difference between the success and recurrence of involuntional entropion and involuntional ectropion was not statistically significant. Chi-square test was done and The p-value was >0.05 . Overcorrection was assessed in 3 eyelids (8.3%) of involuntional entropion which was resolved within 3 weeks of surgery. Mild ecchymosis was observed in 45 (93.7%) eyelids in early postoperative days, mild to moderate pain was presented in all (100%) cases up to 3 days of surgery, Feeling the discomfort in the lower eyelid (41 cases, 85.4%), and feeling of tightness at lateral canthus (95.8%). The feeling of tightness of the lower eyelid and tightness of lateral canthus were stabilized after 1 to 2 weeks of LTS procedure.

4. Discussion

Involuntional entropion and ectropion cause an imbalance forces on the lower eyelid and causes irritation to the globe and may cause corneal ulcer which leads to loss of vision.^{4,5} Surgical correction is the treatment of choice. There are various surgical options are described in the literature to correct involuntional entropion and involuntional ectropion. The Lateral tarsal procedure is a unique procedure by which both involuntional entropion and ectropion can be corrected. Understanding eyelid anatomy and through knowledge of surgical procedure are essential for the correction of eyelid marginal malposition. Both entropion and ectropion are of different clinical entities but can present similar ocular symptoms. Lateral tarsal strip (LTS) technique is a simple and unique procedure to correct both ectropion and entropion of lower eyelid.^{6,7} The LTS procedures help in stabilization of the horizontal length of the lower eyelid and also correct the lateral canthal laxity. We studied 24 eyelids with involuntional entropion of 21 cases (group A), and 24 eyelids with involuntional ectropion of 22 cases (group B). Male (72%) is more prone to female (28%) for eyelid malposition in our study. The mean age is 66.67 year of group A, and 70.68 year of group B patients respectively. The satisfactory outcome of LTS procedure alone is evaluated in the 45(93.7%) eyelids in both groups of our study. The recurrence is noted in one eyelid (4.2%) of group A, and two eyelids (8.3%) of group B during the follow up period. LTS with infraciliary rotation appears to be a safe and effective technique to repair involuntional eyelid entropion with a very high success rate

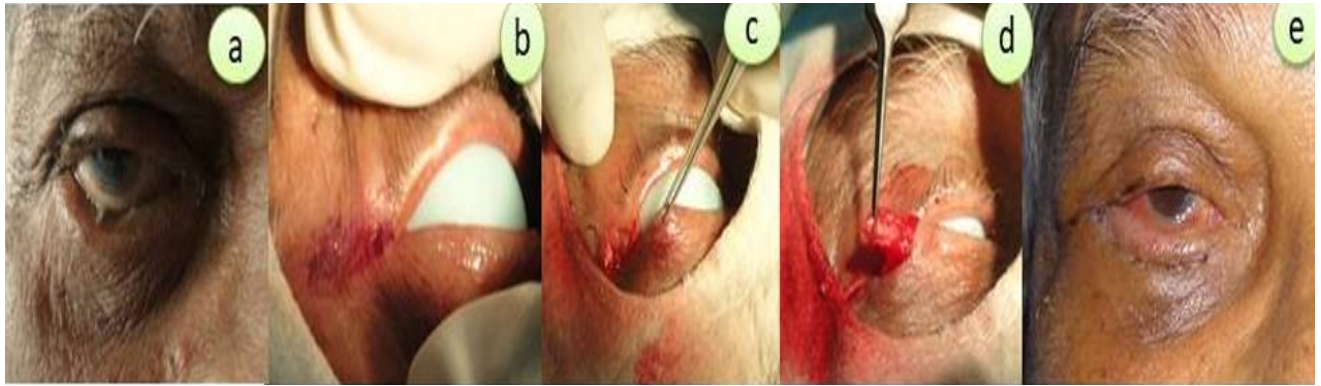


Fig. 1: (a-e): a. Involutinal Entropion of right lower eyelid, b. Marking Lateral canthotomy incision, c. Inferior canthotomy and cantholysis, d. Making a lateral strip, and e. Immediate postoperative status and restoration of right lower eyelid marginal position.

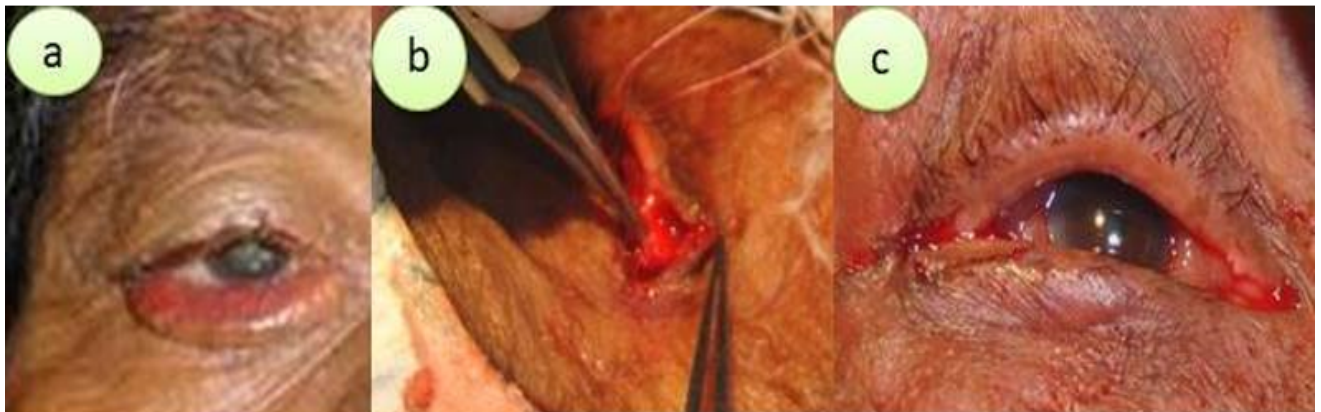


Fig. 2: (a-c): Involutinal ectropion of the right lower eyelid, the lateral tarsal strip (LTS), restoration of lower eyelid position after LTS procedure

Table 1: 1:Distribution of demographic profile and surgical outcome of LTS

Parameters	Group A		Group B		Results
	No.	%	No.	%	
Patients:	21	48.8	22	51.2	43
Eyelids	24	50	24	50	48
Unilateral	18	85.7	20	91	38 (88.3%)
Bilateral	03	14.3	02	09	05 (11.7%)
Male	15	71.4	16	72.7	31 (72%) 12 (28%)
Female	06	28.6	06	27.3	
M:F	2.5:1		2.6:1		2.6:1
Age Distribution:					
Mean Age ± SD (Year)	66.67 ± 9.85		70.68 ± 9.52		68.49 ± 9.97
Median age	63		67		66
Age Range	54 y to 87 y		59 y to 90 y		54 y to 90 y
95% CI	62.18 to 71.15		66.46 to 74.90		65.42 to 71.56
Recurrence (eyelids)	01 4.2		02 8.3		χ^2 value=0.356, df=1 p-value= >0.5 ^{n.s}
Success (eyelids)	23 95.8		22 91.7		

(97.5%) and minimal recurrence rate (2.5%) in 39 eyelids. ocular irritation and discomfort are relieved in 97.7% cases and careful examination is required to ensure the cause of entropion prior to initiating surgical intervention.⁸ 22.2% patients developed postoperative complications of LTS procedure.⁷ The lagophthalmos, superficial punctate keratopathy (SPK) are evaluated preoperatively and all the symptoms are resolved postoperatively. Combined lateral tarsal strip with minimal tarsorrhaphy is an easy, safe, and most effective surgical technique for the management of the lower eyelid paralytic ectropion. It causes minimal aesthetic disfigurement and low morbidity during the long-term follow up.⁹ López-García JS et al. reported that recurrence is evaluated in 8 entropion eyelids (17.4%) and one ectropion eyelid (2.3%) of the 90 eyelids malposition which was corrected by the conventional LTS procedure in one group. The Recurrence is found in only 2 entropion eyelids (4%) in 94 eyelids malposition and repaired by a modified tarsal strip technique in another group. The horizontal laxity of the eyelid is improved in both groups after surgery. There were significant differences among the patients those who were treated with the modified technique ($P=0.04$). The modified suture placement of the LTS improved the stability of the lower eyelid and prevented recurrences after surgery. The modified LTS technique is helpful for the treatment of patients with entropion and ectropion.¹⁰ The correction of ectropion by LTS with double sutures and conjunctival trimming showed improving the lower horizontal laxity than conventional LTS technique. LTS including double suture and conjunctival cuts showed a better ectropion correction with reducing grade and recurrences.¹¹ Jones retractor plication (JRP) alone in 61 patients and compared with JRP with a LTS in 57 patients for the corrected of involutional entropion was evaluated in a study and reported that JRP + LTS technique come with a higher success rate compared to JRP alone.¹² Minimal ecchymosis is observed in all cases of our study which was resolved within 2 weeks of surgery. All patients are felt mild postoperative pain up to 3 days of surgery. All the patients were happy and satisfied with the relief of epiphora, and foreign body sensation from their eyes. We performed a combined surgery (Dacryocystectomy with LTS) for the management of chronic dacryocystitis and involution entropion of the same eye. The combined surgeries (lacrimal drainage surgery with LTS) are effected techniques for the management of nasolacrimal duct obstruction and lower lid laxity.¹³ LTS is helping to restore the normal lid function and gives a rapid rehabilitation and best aesthetic outcome.¹⁴ Transverse everting sutures can be performed in combination with LTS for the better outcome for the correction of involutional entropion.^{14,15}

5. Conclusion

Lateral tarsal strip (LTS) procedure is easy, simple, and unique surgical technique to correct the lower eyelid

malposition of different etiology and it can be performed with an additional technique to achieve the best surgical outcome.

6. Conflict of Interest

The authors declare no potential conflicts of interest.

7. Source of Funding

No funding was received for this study.

References

- Vahdani K, Ford R, Garrott H, Thaller VT. Lateral tarsal strip versus Bick's procedure in correction of eyelid malposition. *Eye*. 2018;32(6):1117–22. doi:10.1038/s41433-018-0048-9.
- Collin JRO. A manual of systematic eyelid surgery. In: 3rd edn. New York: Churchill Livingstone; 2006. p. 59–60.
- Jordan DR, Anderson RL. The lateral tarsal strip revisited. The enhanced tarsal strip. *Arch Ophthalmol*. 1989;107:604–6.
- Wright M, Bell D, Scott C, Leatherbarrow B. Everting suture correction of lower lid involutional entropion. *Br J Ophthalmol*. 1999;83(9):1060–3. doi:10.1136/bjo.83.9.1060.
- van den Bosch WA, Leenders I, Mulder P. Topographic anatomy of the eyelids, and the effects of sex and age. *Br J Ophthalmol*. 1999;83(3):347–52. doi:10.1136/bjo.83.3.347.
- Fradinho N, Pereira A, Rasteiro D, Sousa J, Tojo N, Martins J, et al. Lateral tarsal strip technique for lower lid ectropion and entropion. *Int J Oral and Maxillofac Surg*. 2013;42(10):1322–5. doi:10.1016/j.ijom.2013.07.521.
- Al-Taher AAM, Awadeen AER. Lateral Tarsal Strip, Can It Be One Solution for All Types of Lower Eyelid Malposition? *Egypt J Hospital Med*. 2019;75(5):2745–7.
- Rabinovich A, Allard FD, Freitag SK. Lower Eyelid Involutional Entropion Repair with Lateral Tarsal Strip and Infraciliary Rotation Sutures: Surgical Technique and Outcomes. *Orbit*. 2014;33(3):184–8. doi:10.3109/01676830.2014.894540.
- Kwon KY, Jang AY, Yoon JS. Long-term outcome of combined lateral tarsal strip with temporal permanent tarsorrhaphy for correction of paralytic ectropion caused by facial nerve palsy. *J Craniofac Surg*. 2015;26(5):409–12.
- López-García JS, García-Lozano I, Giménez-Vallejo C, Jiménez B, Sánchez A, Elosua de-Juan I. Modified lateral tarsal strip for involutional entropion and ectropion surgery. Graefe's Arch for. *Clin and Exp Ophthalmol*. 2017;255:619–25.
- Meduri A, Inferrera L, Oliverio GW, Tumminello G, Rechichi M, Mazzotta C, et al. The Use of a Double Suture and Conjunctival Cuts in the Lateral Tarsal Strip: A New Approach to Involutional Ectropion. *J Craniofac Surg*. 2018;29(8):2312–5. doi:10.1097/scs.0000000000004838.
- Ranno S, Sacchi M, Gilardi D, Lembo A, Nucci P. Retractor Plication versus Retractor Plication and Lateral Tarsal Strip for Eyelid Entropion Correction. *Euro J Ophthalmol*. 2014;24(2):141–6. doi:10.5301/ejo.5000369.
- Lee H, Hwang J, Kim JW, Park M, Baek S. The Effectiveness of Simultaneous Lateral Tarsal Strip With Endonasal Dacryocystorhinostomy for the Treatment of Nasolacrimal Duct Obstruction and Lower Lid Laxity. *J Craniofac Surg*. 2013;24(3):980–3. doi:10.1097/scs.0b013e3182869ae3.
- Olver JM. Surgical tips on the lateral tarsal strip. *Eye*. 1998;12(6):1007–12. doi:10.1038/eye.1998.258.
- Barnes JA, Bunce C, Olver JM. Simple Effective Surgery for Involutional Entropion Suitable for the General Ophthalmologist. *Ophthalmol*. 2006;113(1):92–6. doi:10.1016/j.ophtha.2005.06.039.

Author biography

Syed Mehbub Ul Kadir, Assistant Professor

Rajendra P Maurya, Associate Professor

Md. Saiful Islam, Assistant Professor

Mostafa Zahir Raihani, Senior Consultant

Sharmin Ahmed, Consultant

Meghna Roy, Resident

Golam Haider, Professor

Cite this article: Kadir SMU, Maurya RP, Islam MS, Raihani MZ, Ahmed S, Roy M, Haider G. Lateral tarsal strip (LTS): Surgical technique and outcomes. *IP Int J Ocul Oncol Oculoplasty* 2021;7(1):12-16.